

Case #1

Patient Demographics

Age/Gender:

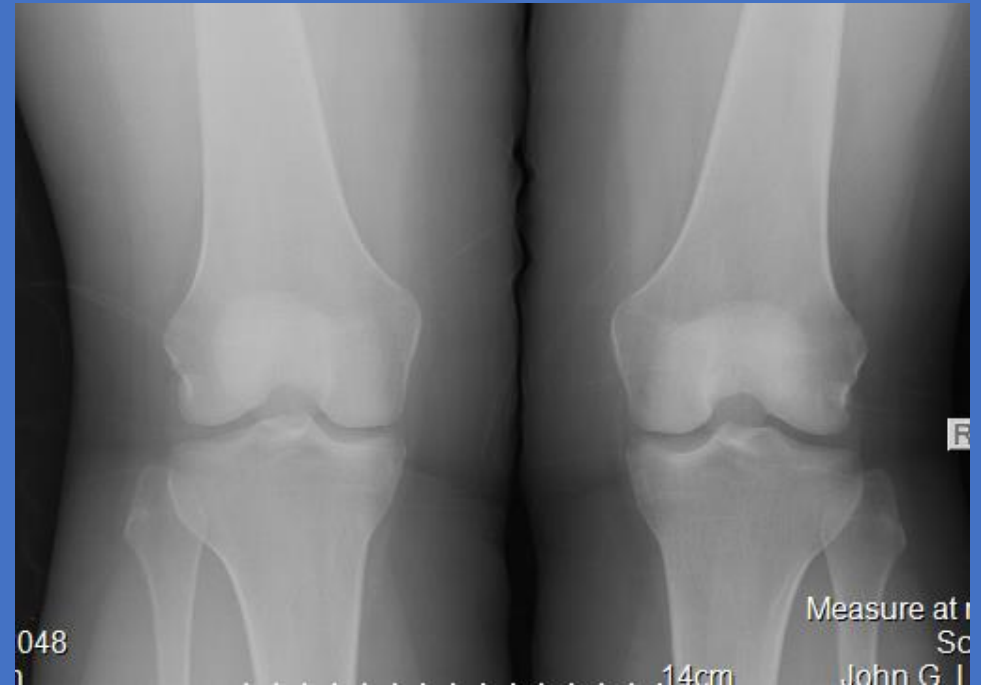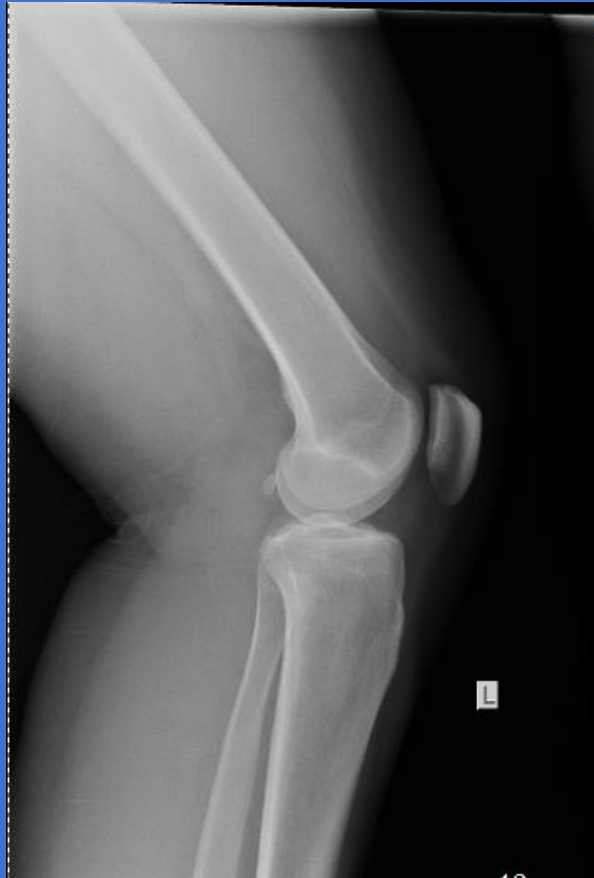- 39 yo female

Hx Presentation:

- Fall, contusion
- 10 months prior
- Pain localized to medial aspect of knee

Pre-Images

Xray



Case #1

Age/Gender:

- 39 yo female

Hx Presentation:

- Fall, contusion
- 10 months prior
- Pain localized to medial aspect of knee

Pre-Images:

Long leg alignment radiographs – neutral

MRI – Medial femoral condyle defect, no subchondral edema

Otherwise unremarkable

Prior surgery: None prior

Conservative treatment:

Physical therapy

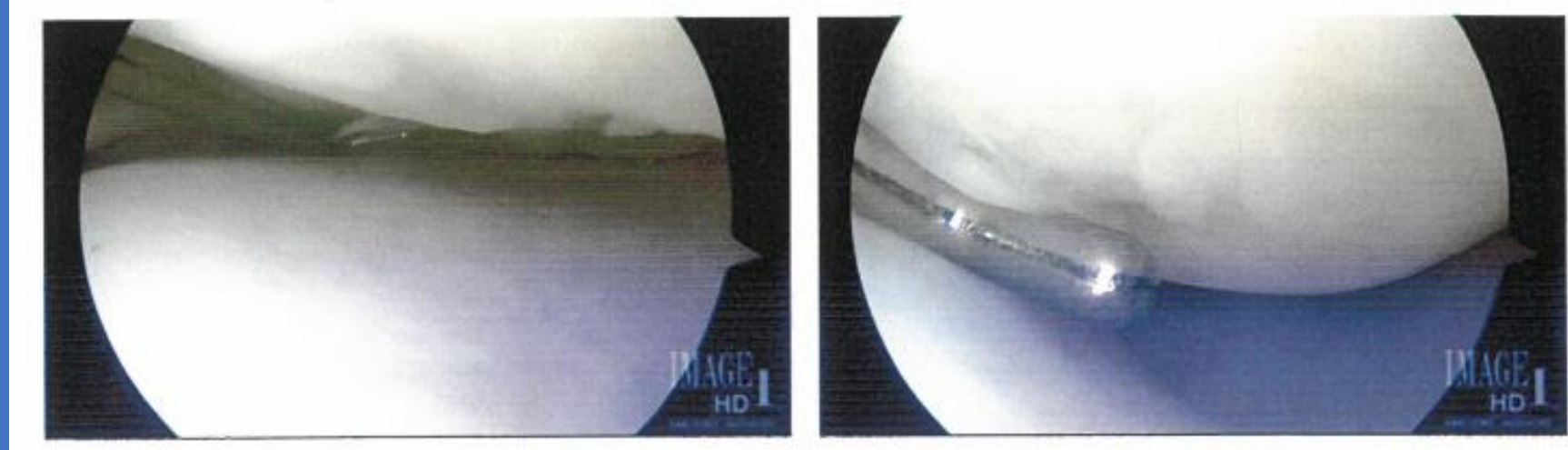
Valgus unloader knee brace

NSAIDs

Treatment

- May 2018
- Diagnostic Scope Pics
 - 2 x 1.5cm
 - Medial femoral condyle, grade 3
 - Biopsy obtained

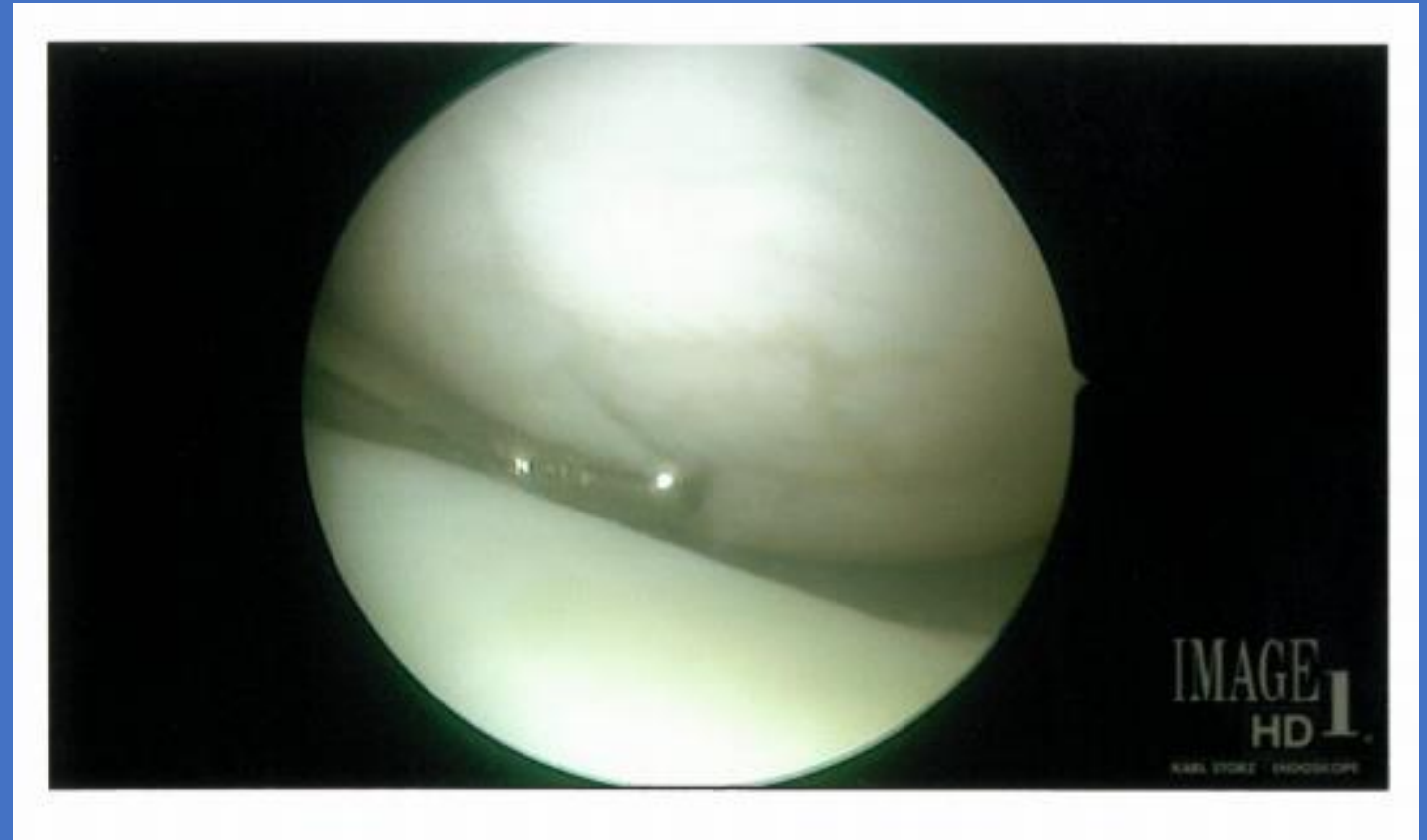
Diagnostic Scope Pics



Treatment

- August 2020
- Surgery
 - MACI MFC
 - 3.5cm x 1.5cm at time of implant

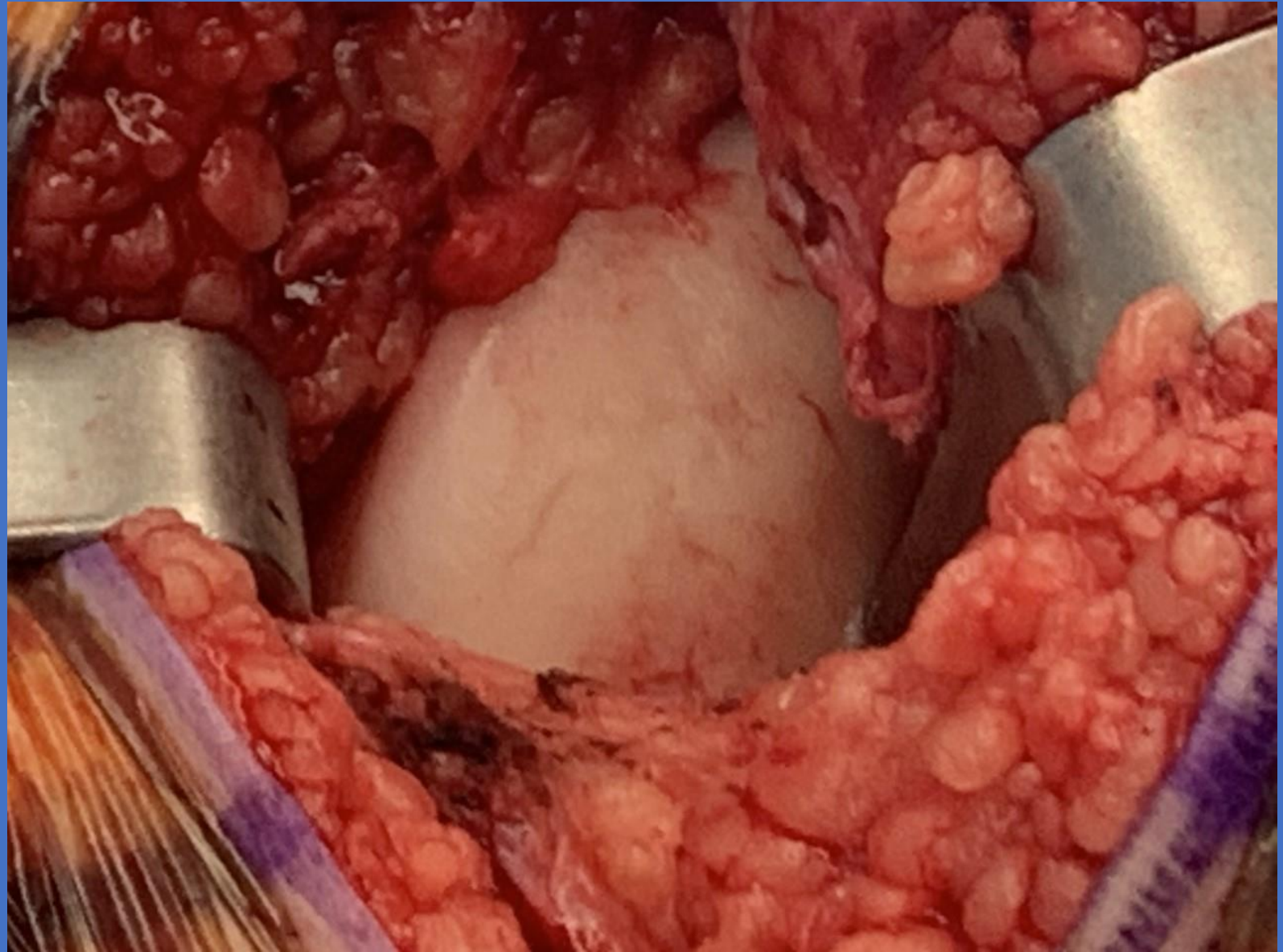
Before MACI



Treatment

- Surgery
 - MACI MFC

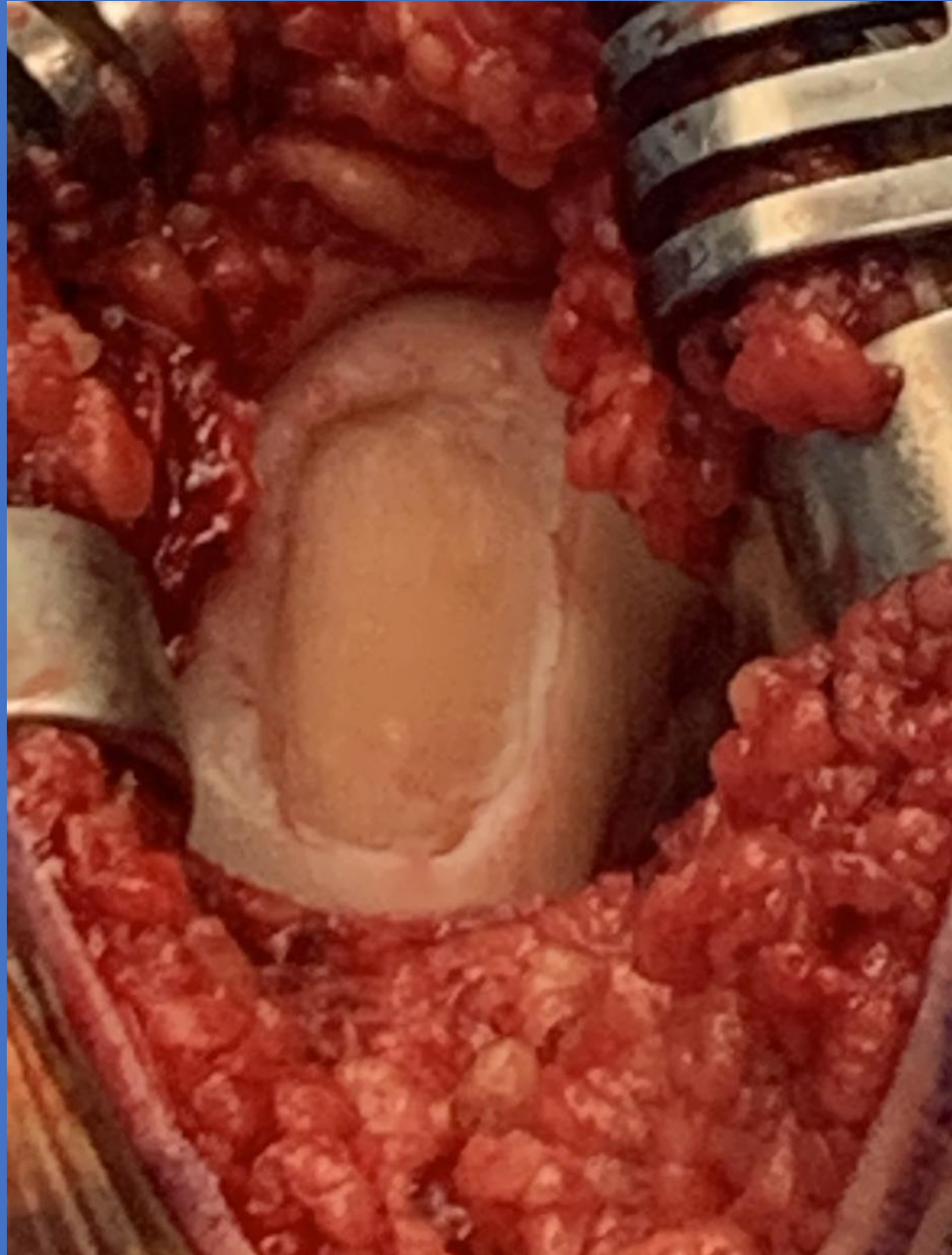
MFC defect exposure



Treatment

- Surgery
 - MACI MFC

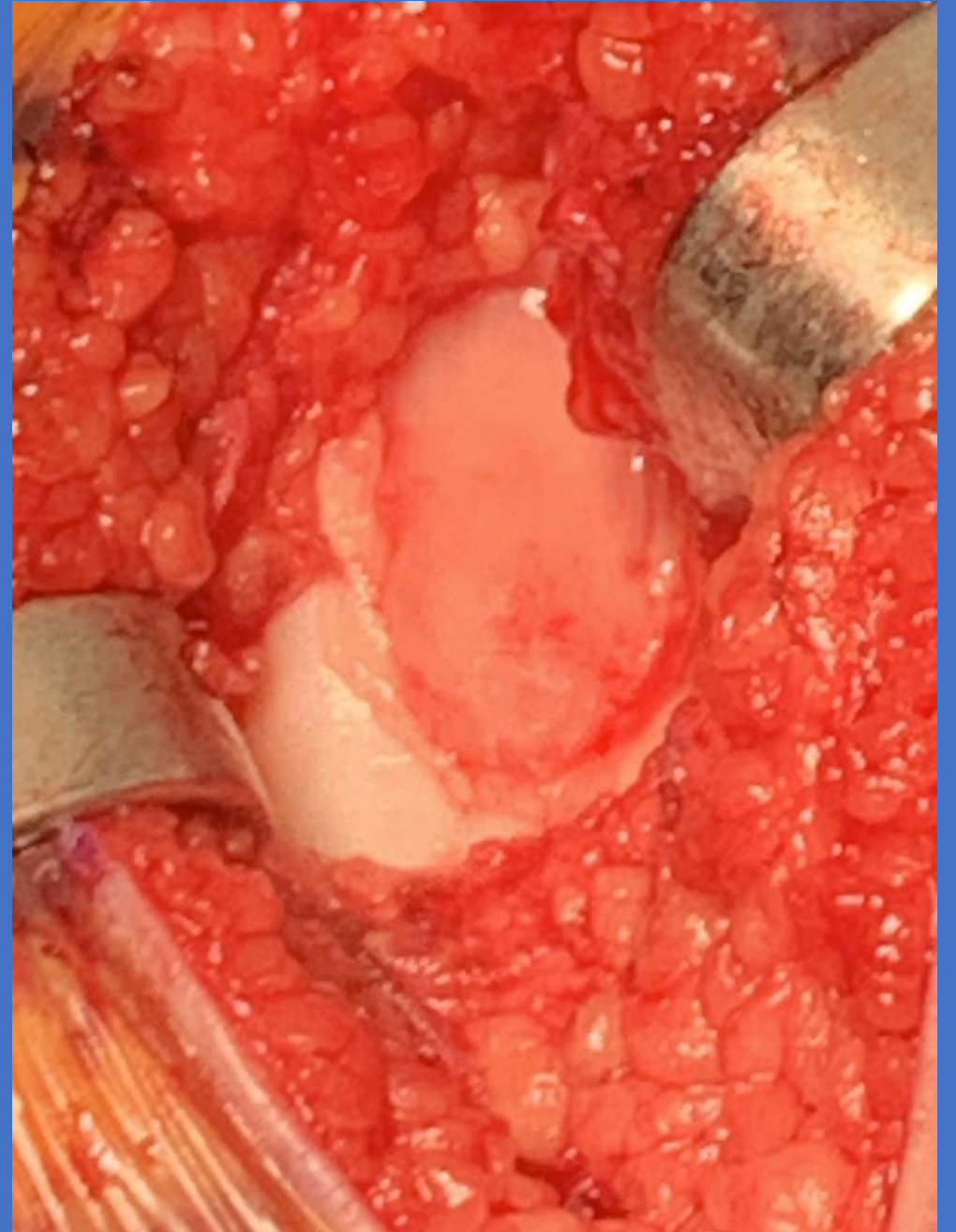
Removal of calcified cartilage layer and creation of vertical walls



Treatment

- Surgery
 - MACI MFC

MACI post-implantation



Post-op

Complications: Patient developed atrial fibrillation with rapid ventricular rhythm immediately postop, admitted for observation and anticoagulation with Eliquis

Rehabilitation:

- CPM after eight hours
- Partial weightbearing x 1 month using ROM knee brace 0-60 for 2 weeks, 0-90 for 2-4 weeks
- FROM and FWB with crutches at four weeks postop -- transitioned to valgus unloader knee brace and initiated physical therapy 2x weekly for 6 weeks
- Valgus unloader brace for at least one year postop

Case 2

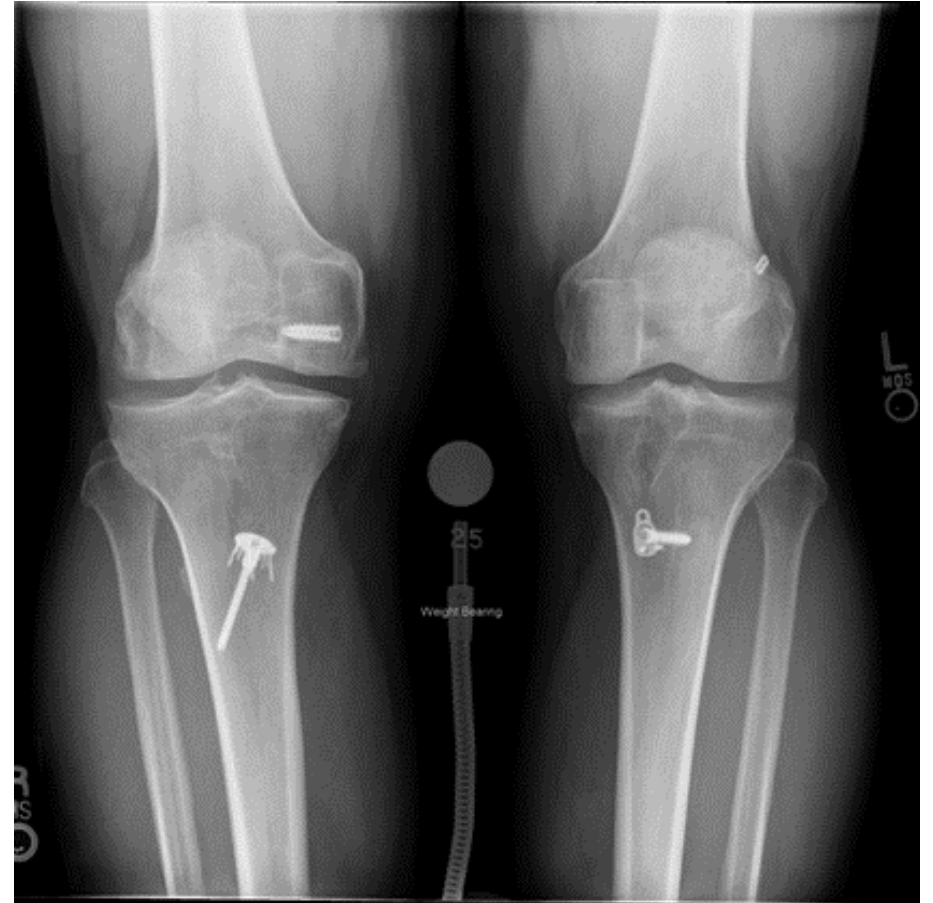
+41yo male

- Construction worker
- Runner, avid cyclist
- 2-year history of medial sided knee pain
 - + h/o PCL reconstruction 21 years ago, after fall off his bike
 - + h/o chondroplasty/MFx of the MFC 8 years ago
- Underwent recent knee arthroscopy, partial medial meniscectomy, chondroplasty 18 months ago
 - + Symptomatic relief and did well initially, but tripped 6 weeks after
 - Knee has “never felt the same” after this
 - Steroid/visco injections with no relief

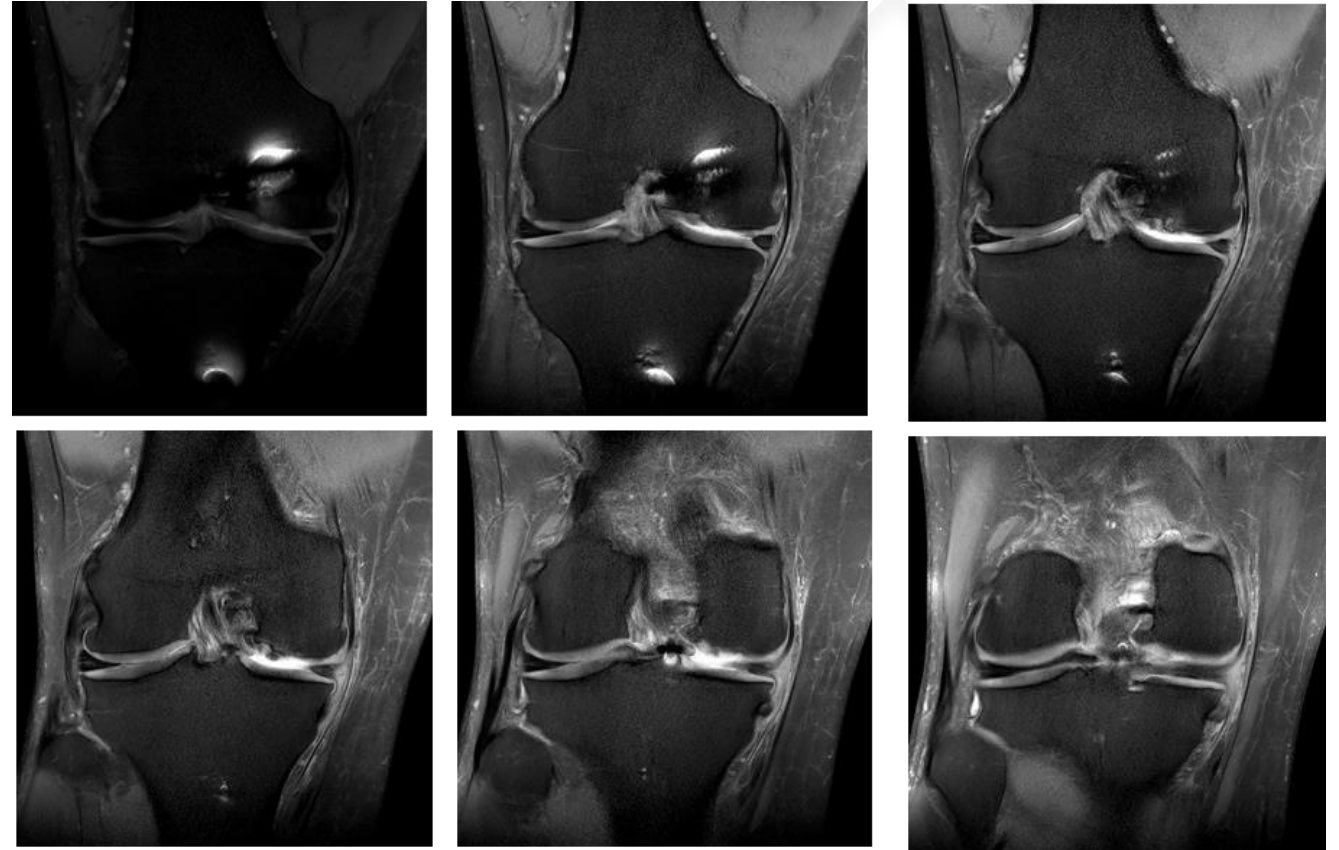
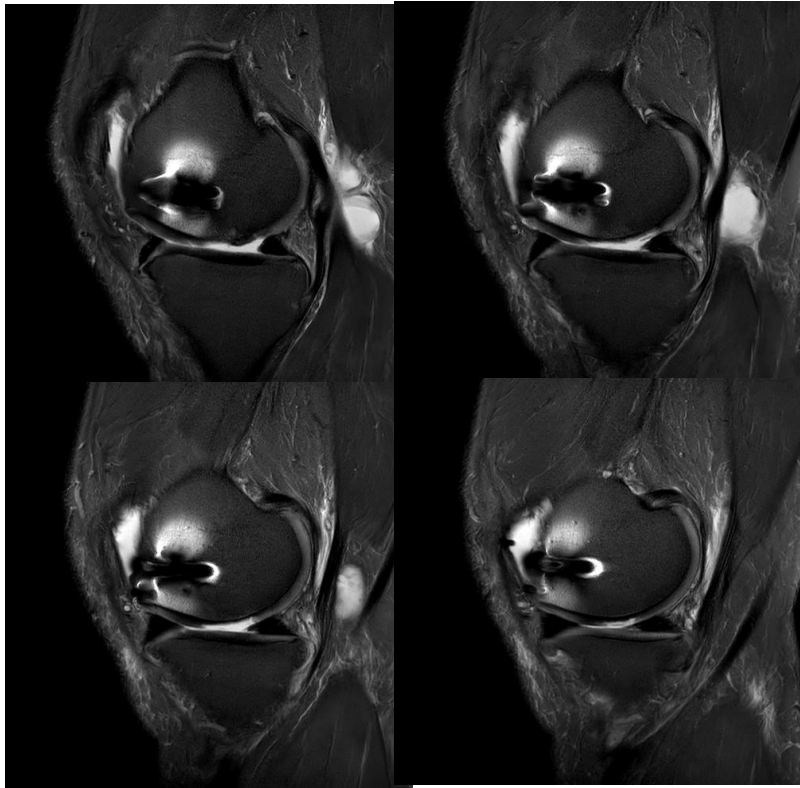


Physical Exam

- + No effusion
 - + FAROM
 - + + Medial joint line tenderness
 - + Neg McMurray's
 - + Grade 1 PCL, good endpoint
-
- + XR




MRI

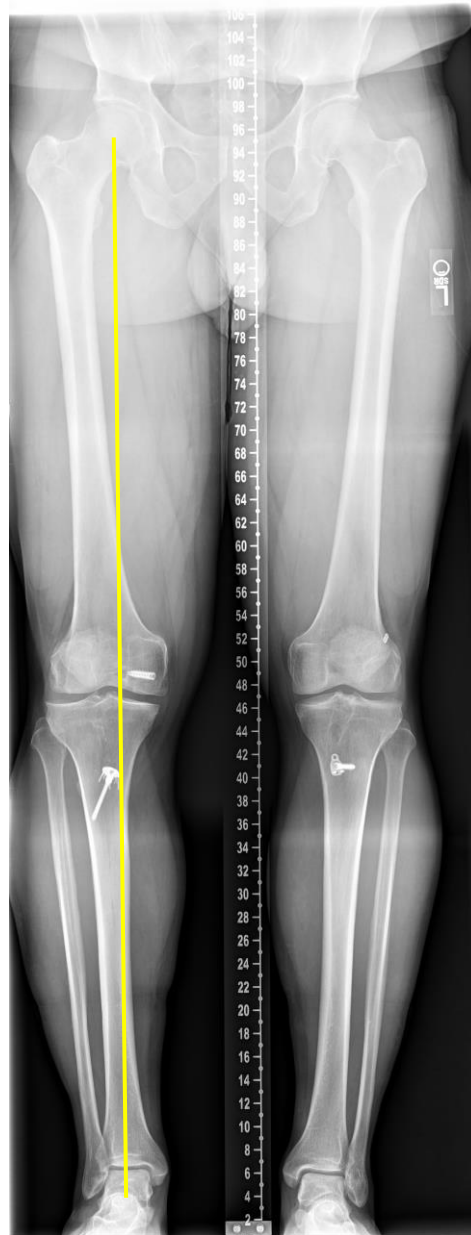


- + Large chondral lesion MFC
- + MFC osteophyte
- + Meniscus intact

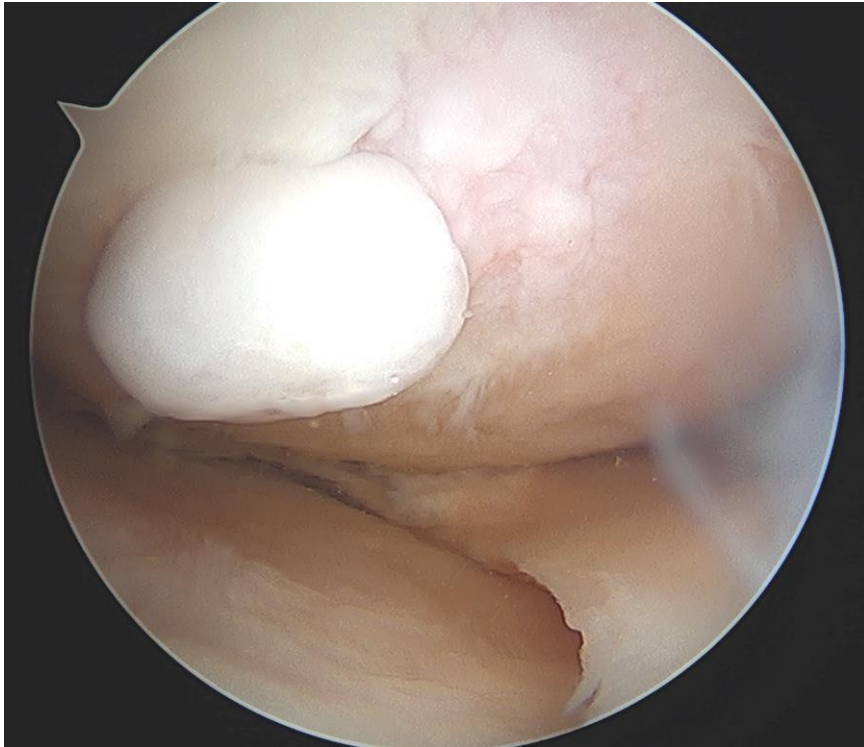
✕ Thoughts?



X Scanogram

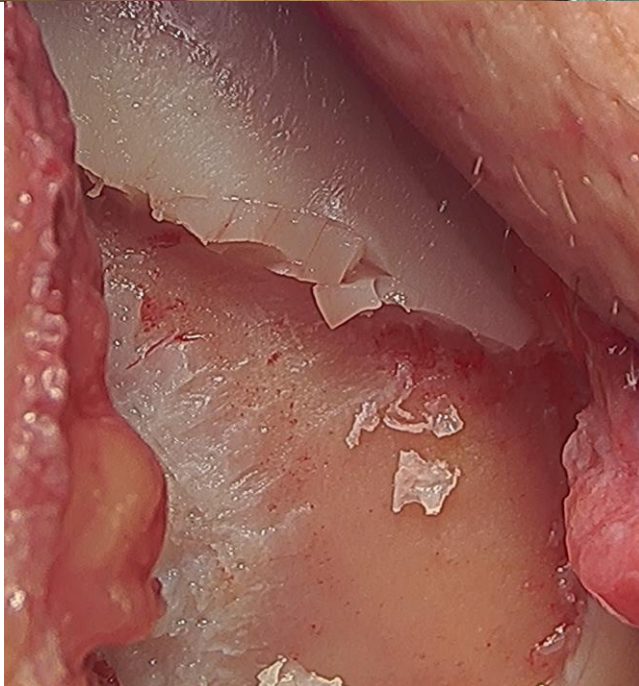
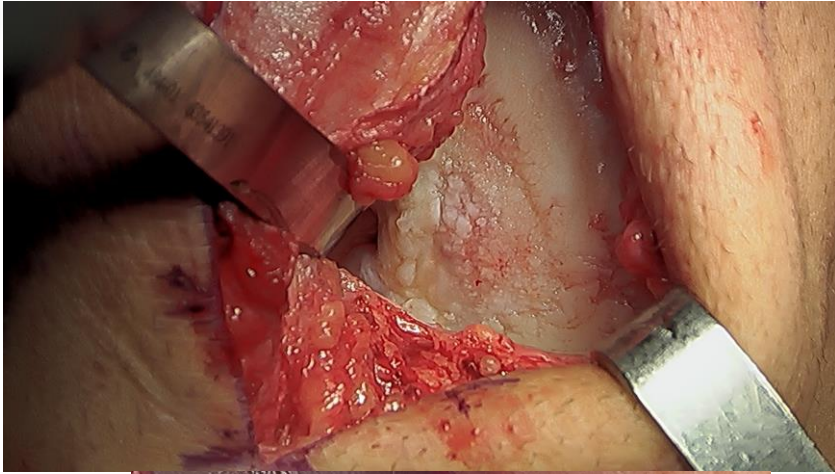


Diagnostic arthroscopy



- +3.6 x 2cm
- +Grade 4 lesion
- +Chondroplasty, LBR performed

X Treatment decision



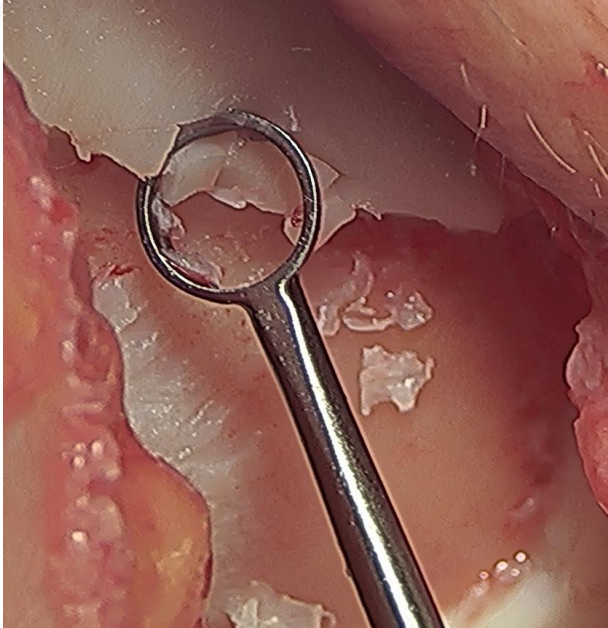
+ Isolated large MFC lesion

- No malalignment
- Ligamentously stable
- Intact meniscus

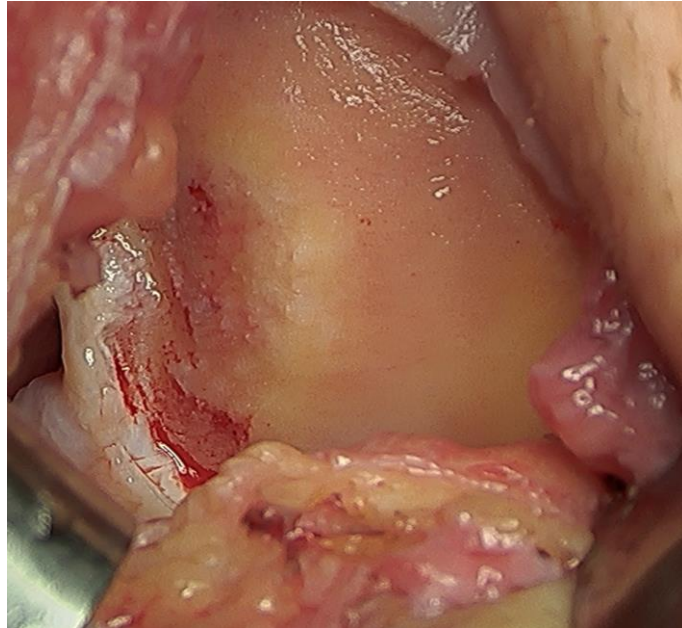
+ Surgical plan

- Midline incision, midvastus medial parapatellar arthrotomy
- Prepare lesion – vertical borders
- ?uncontained lesion

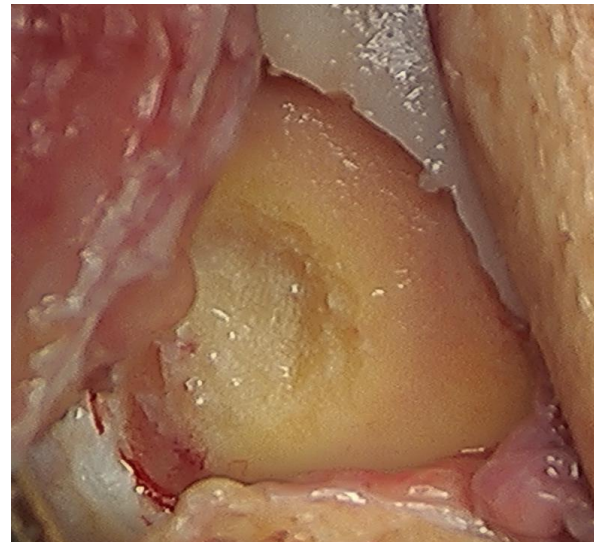
Surgical procedure - principles



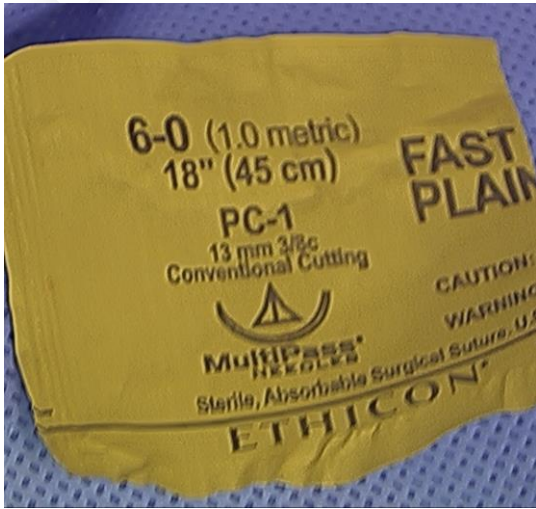
+ Vertical borders



+ Debride sclerotic bone/intralesional osteophyte

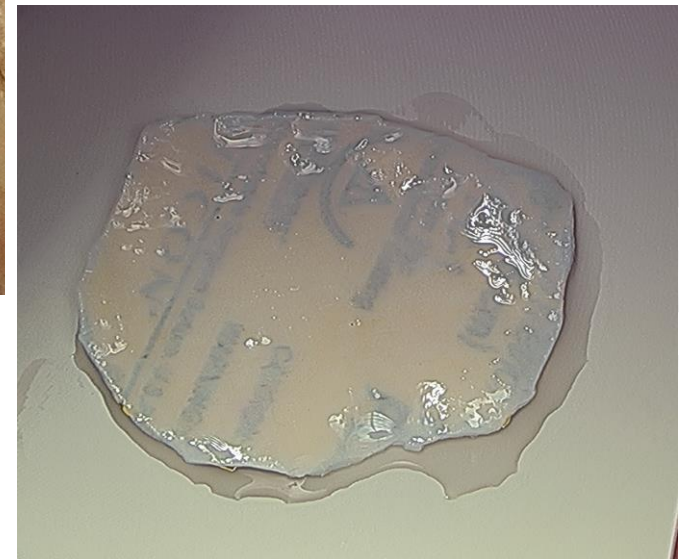
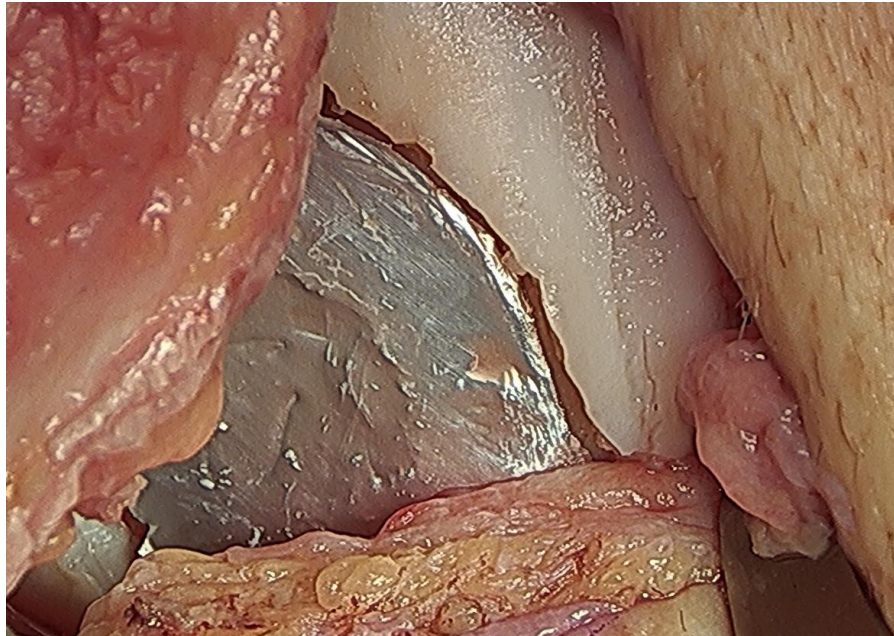


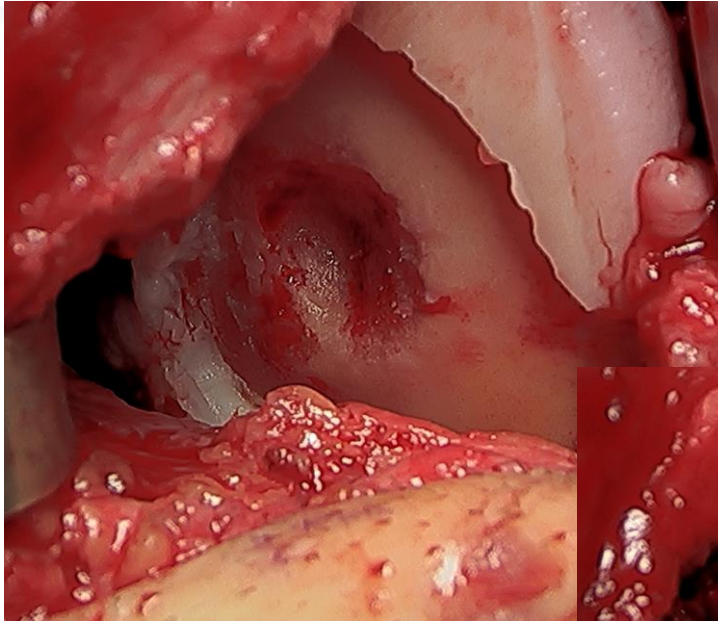
MACI Template



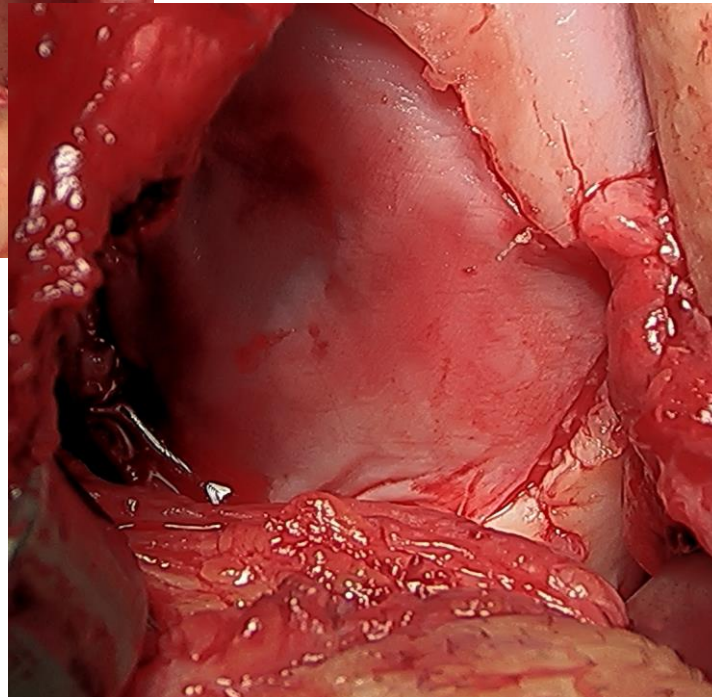
- + Colored side
- + Cell side

+ Suture packet foil template





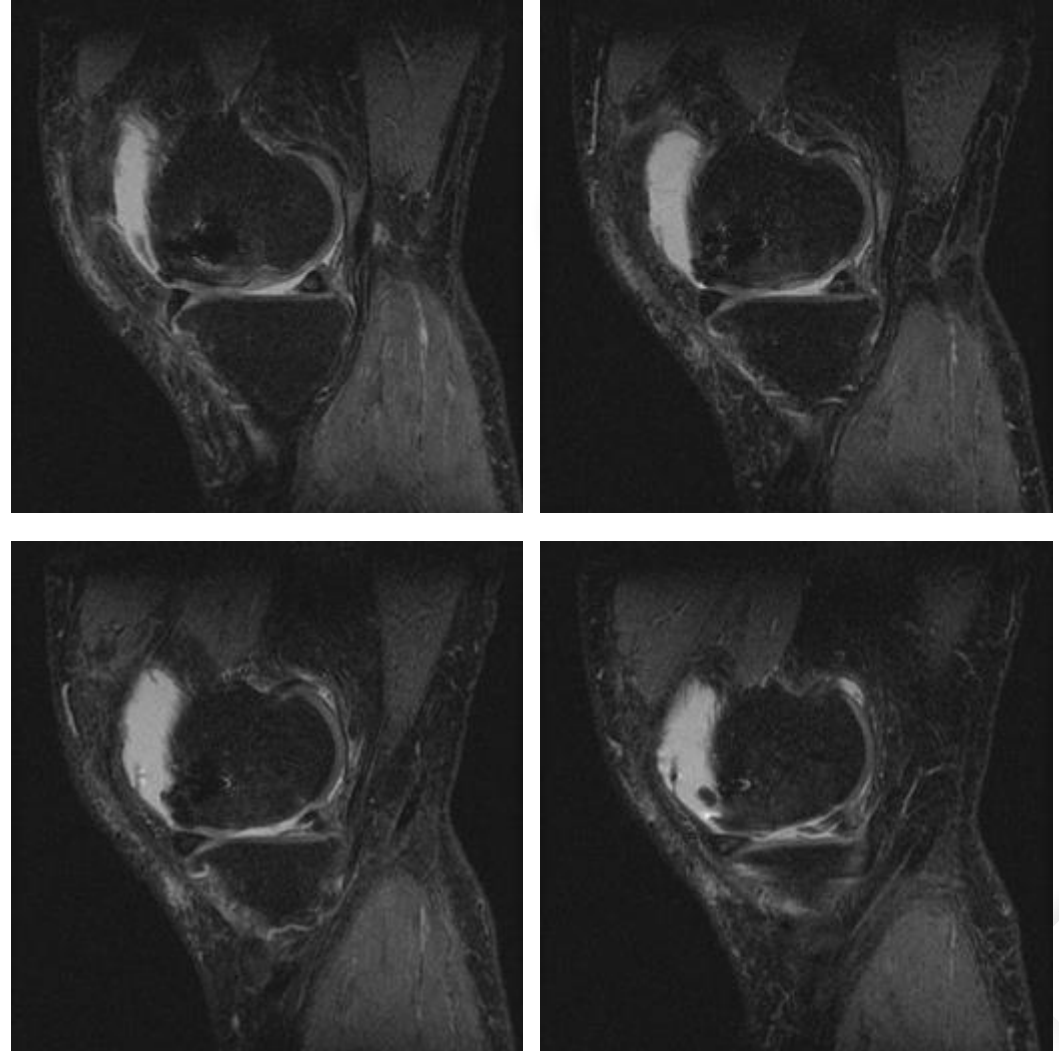
- + Fibrin glue clot on bleeding subchondral bone
- + Thin layer fibrin glue



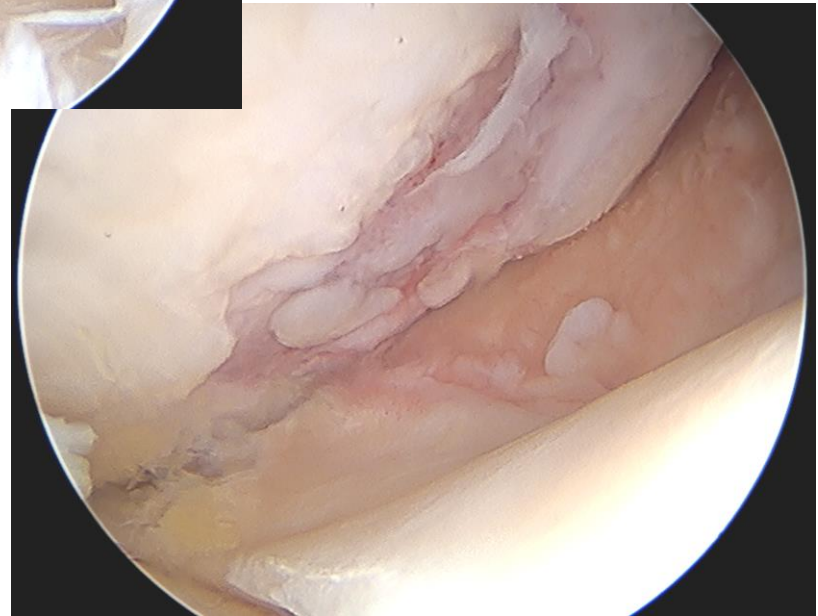
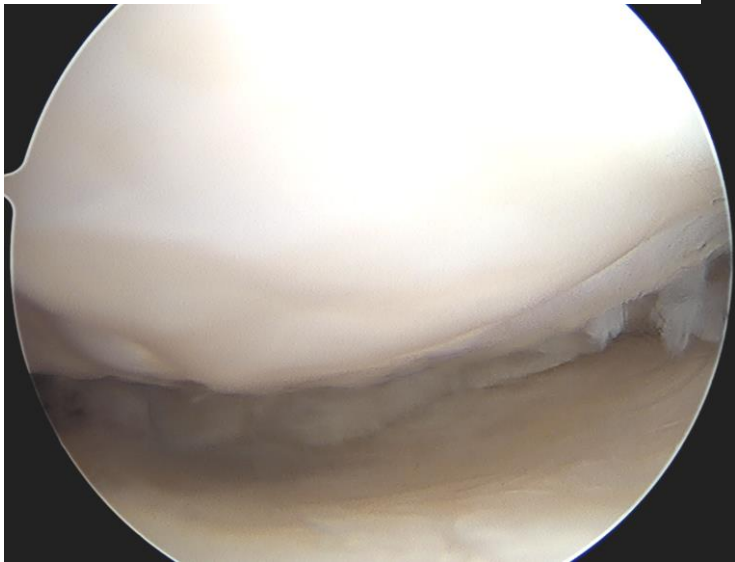
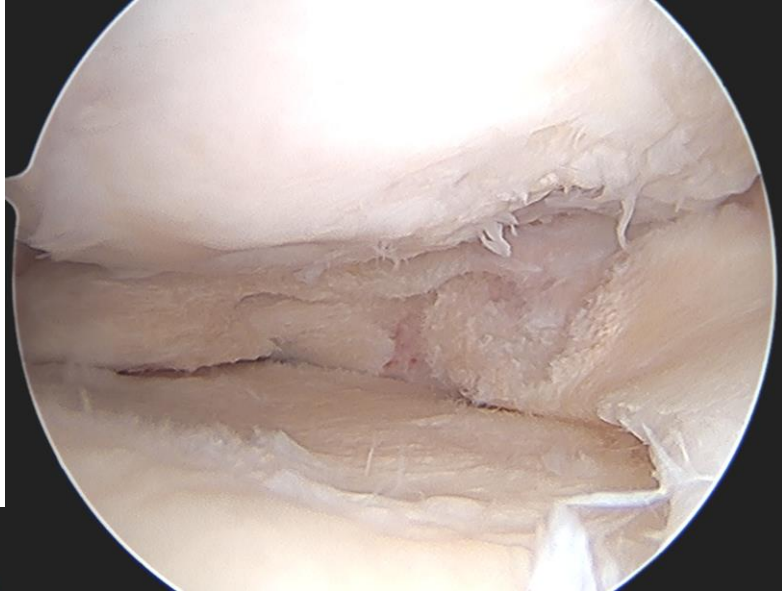
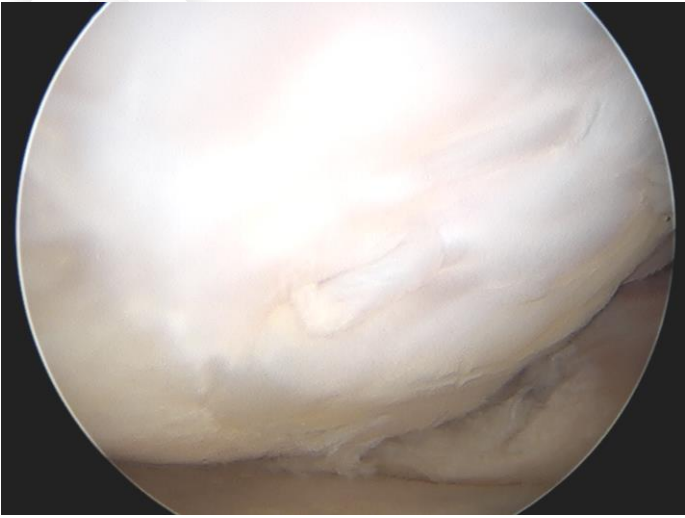
Lay down membrane,
cell side down
suture edges –
uncontained/large

F/u

- + 3 months post op – was putting on his pants and heard a loud pop
- + Medial sided knee pain – different than preop
- + Worse with terminal extension. When it pops, he has relief.



2nd look arthroscopy



Case #3

Patient Demographics

Age/Gender:

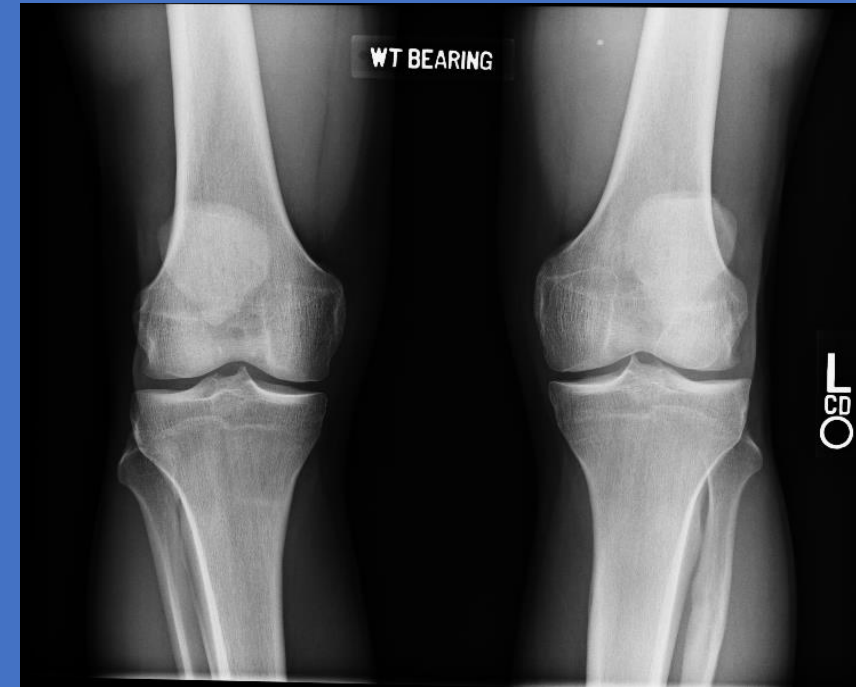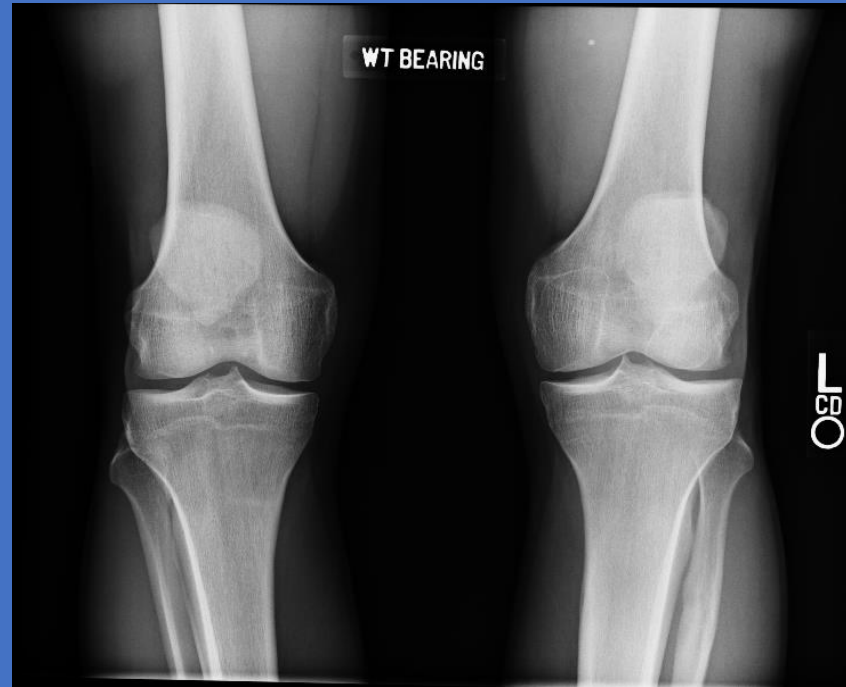- 31 yo male

Hx Presentation:

- Soccer player
- Left knee pain >1 year
- History of MFx LFC 5 years ago

Pre-Images

Xray



Case #3

Patient Demographics

Age/Gender:

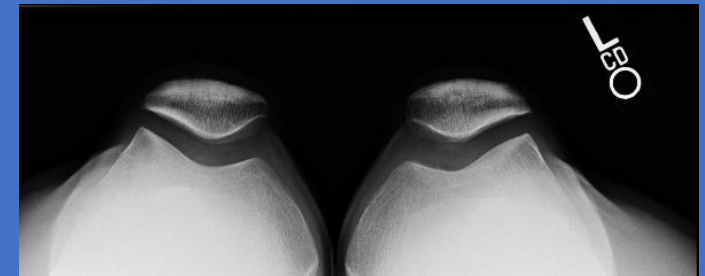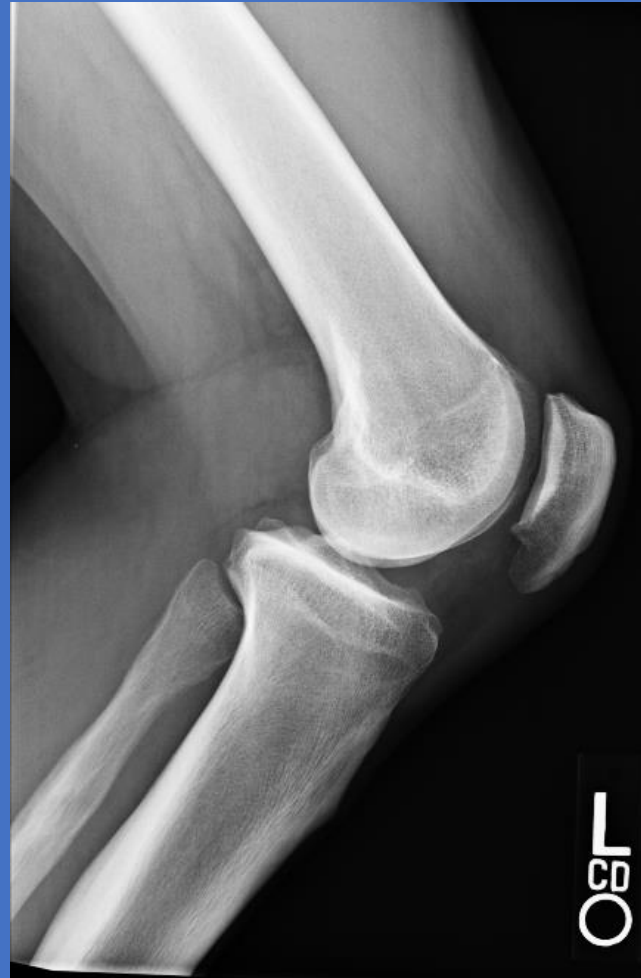- 31 yo male

Hx Presentation:

- Soccer player
- Left knee pain >1 year
- History of MFx LFC 5 years ago

Pre-Images

Xray



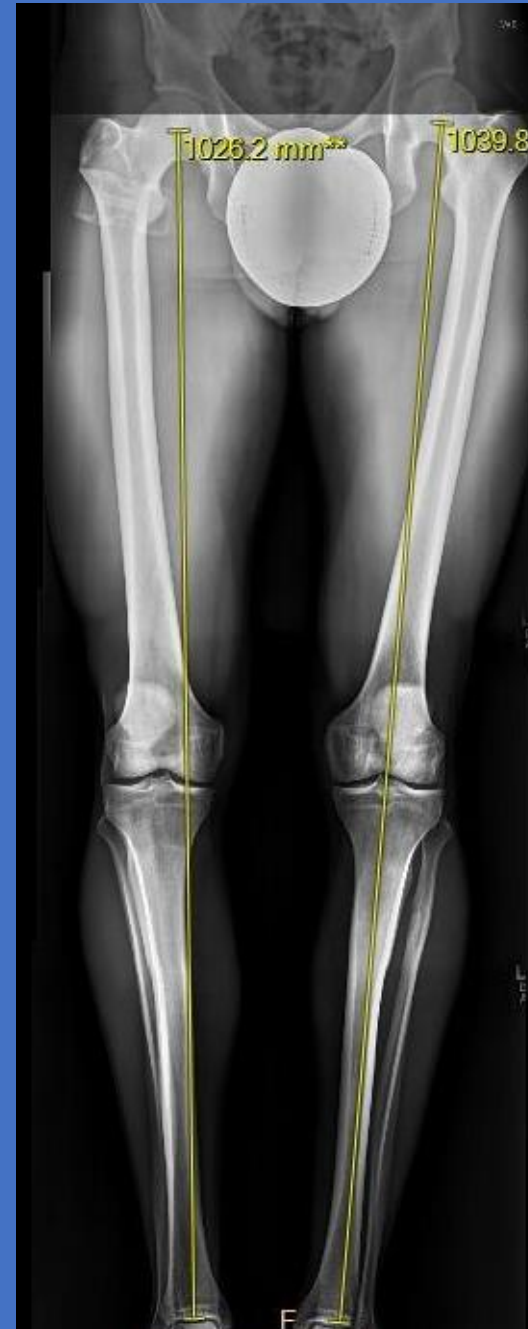Case #3

Patient Demographics

Exam Findings:

- Full range of motion bilateral knees
- Lateral joint line tenderness
- Slight valgus deformity
- Normal ligamentous exam
- +1 effusion

Pre-Images

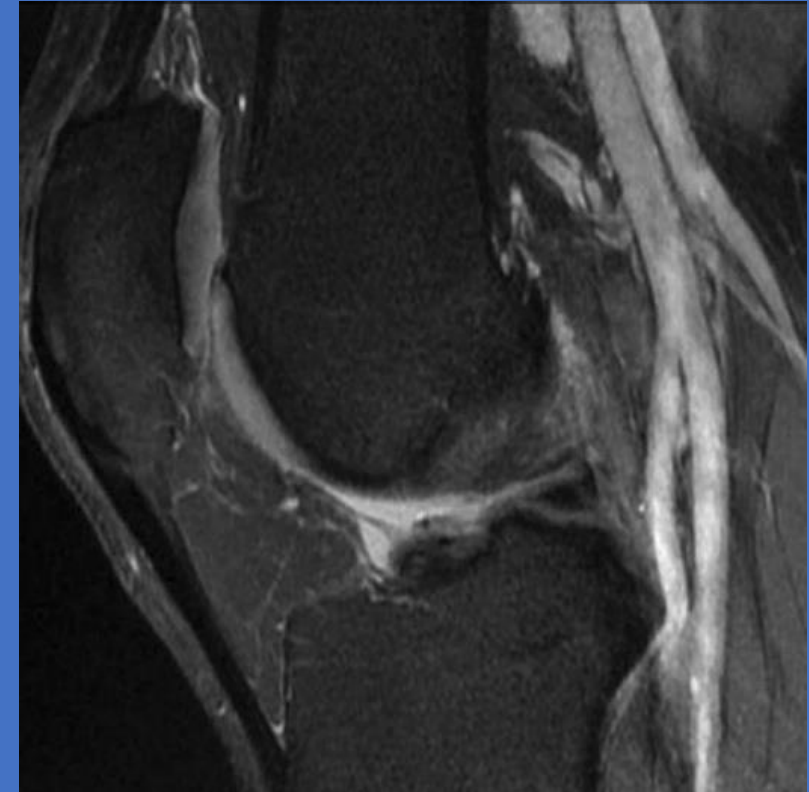
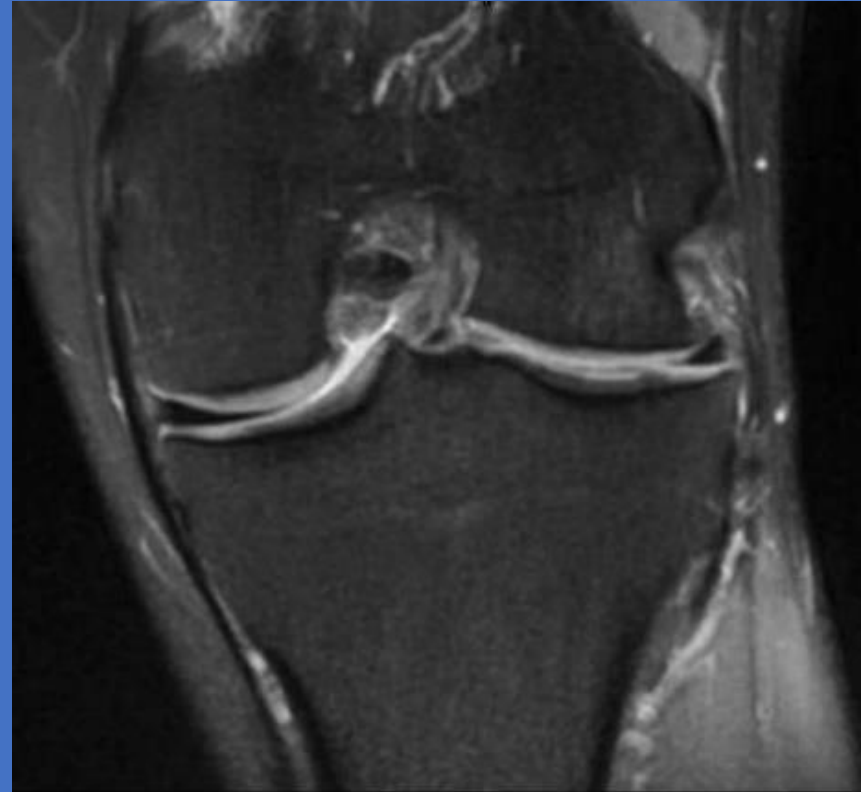

Case #3

Patient Demographics

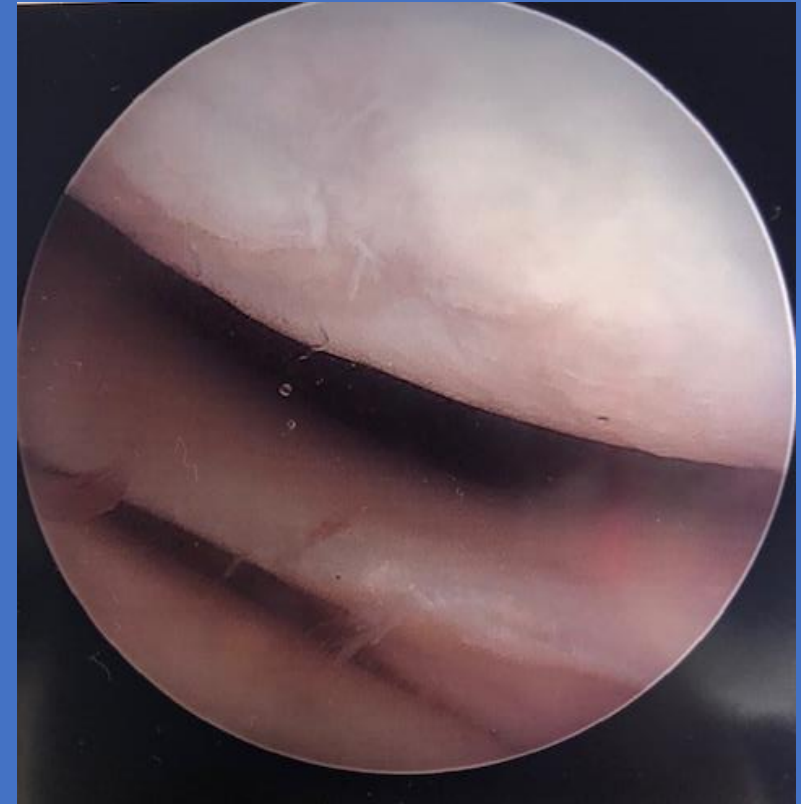
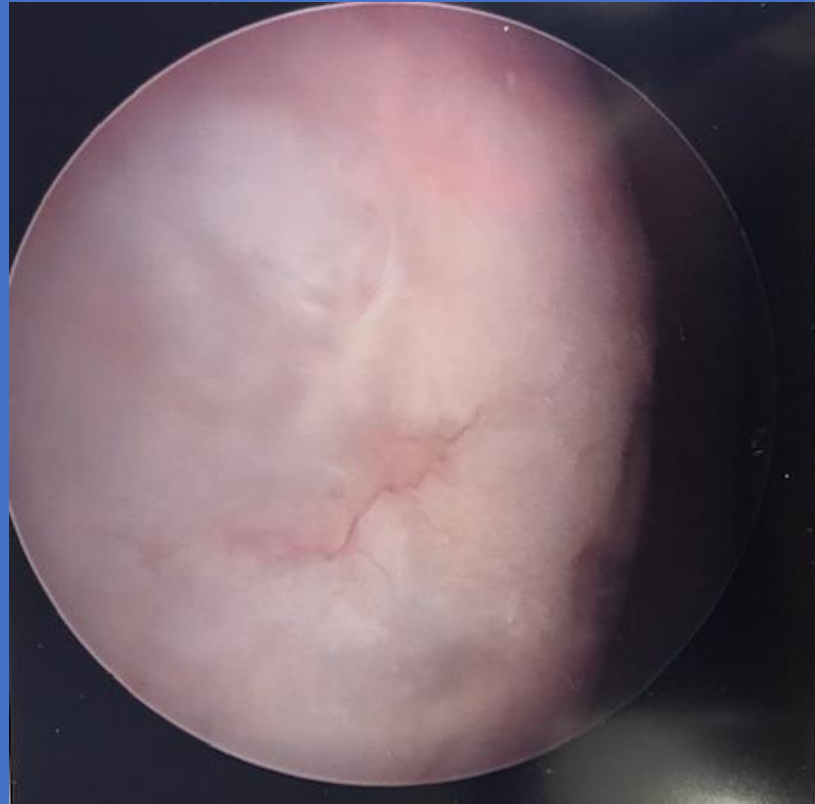
Exam Findings:

- Full range of motion bilateral knees
- Lateral joint line tenderness
- Slight valgus deformity
- Normal ligamentous exam
- +1 effusion



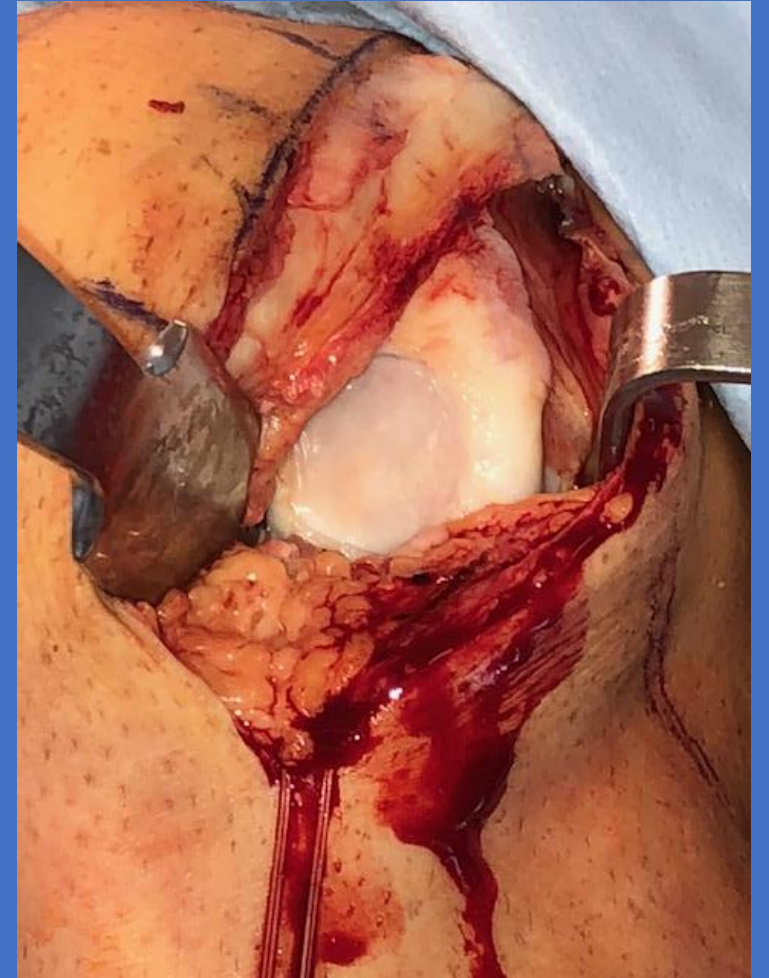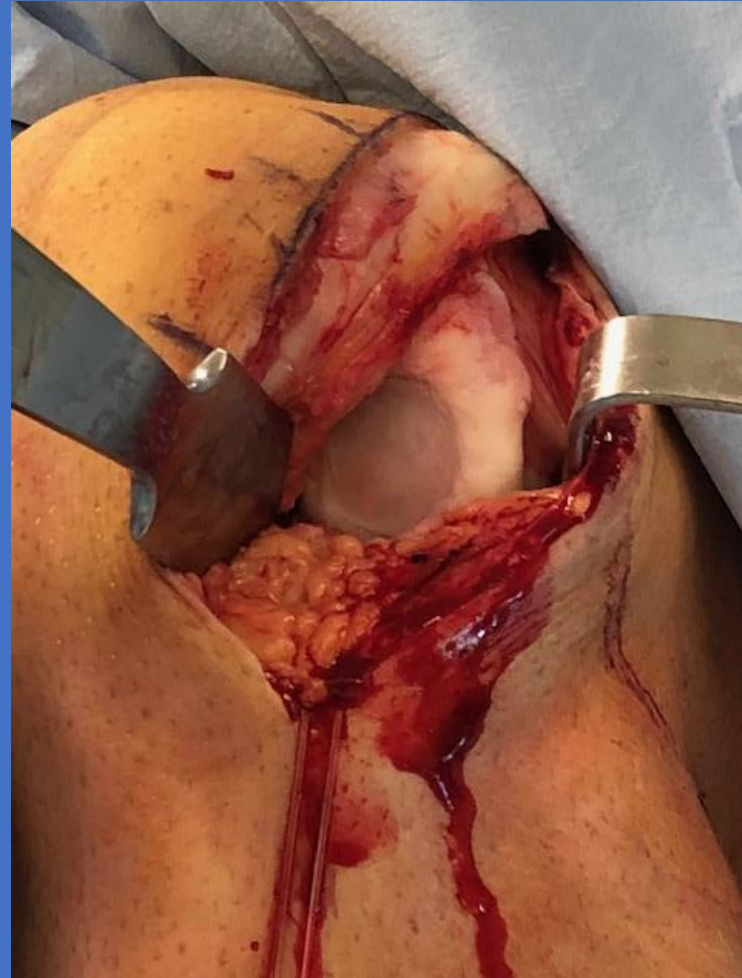Treatment

- Diagnostic Scope Pics
 - 3x3 cm defect
 - No bone involvement
 - Biopsy obtained
 - No other pathology



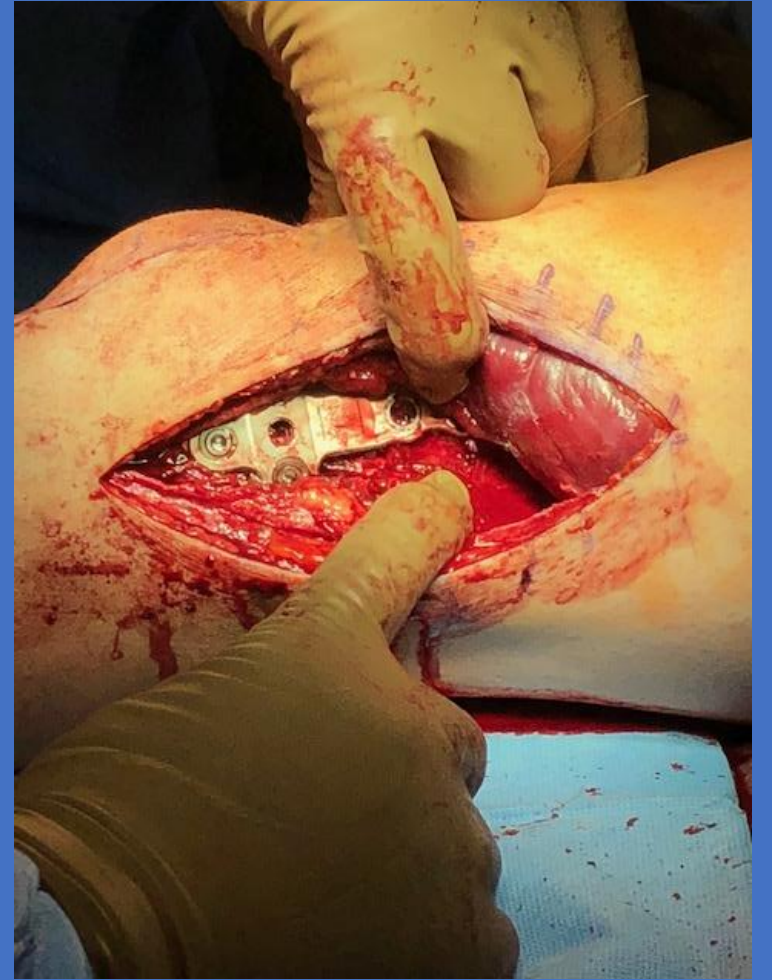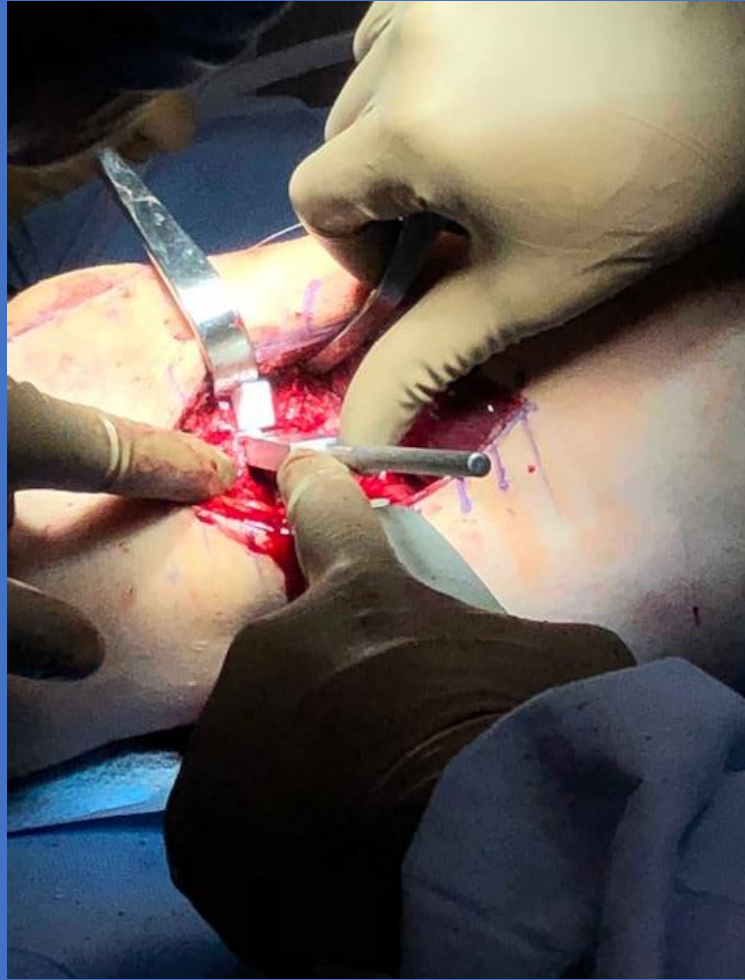
Treatment

- Surgery
 - MACI LFC
 - DFO



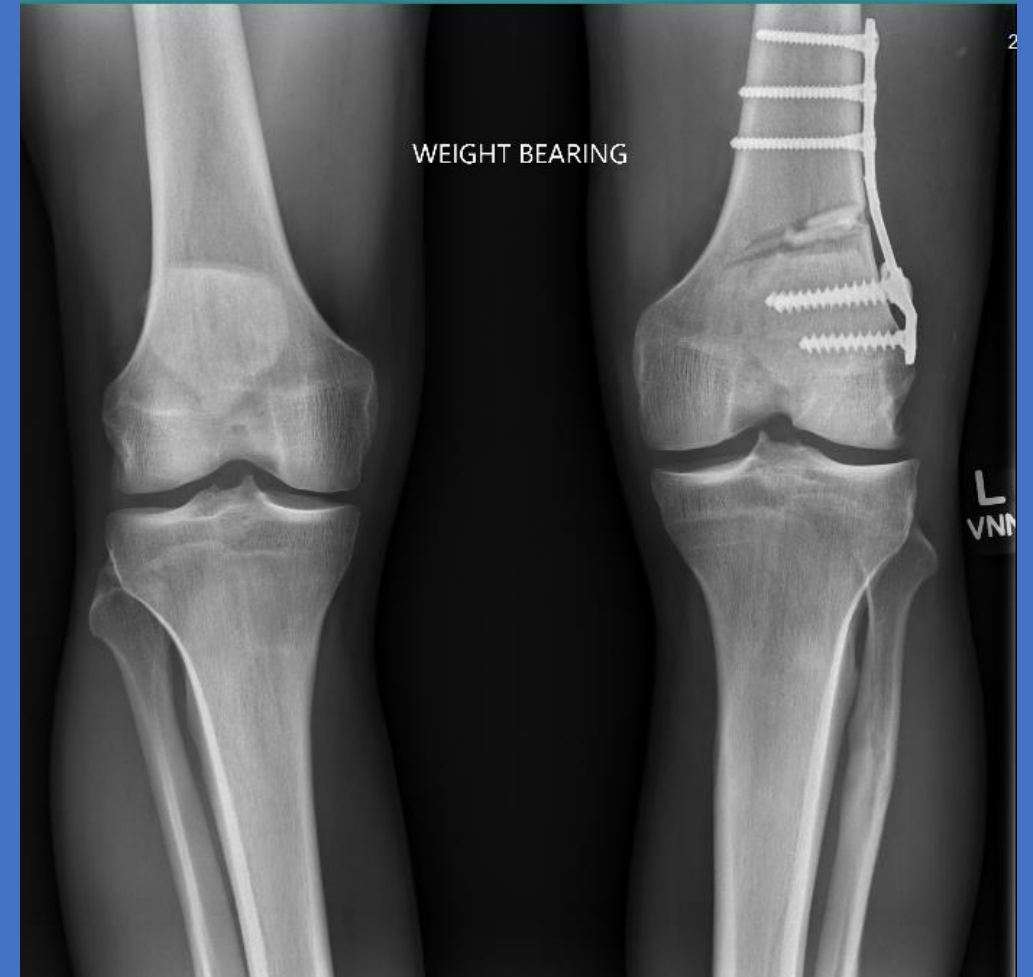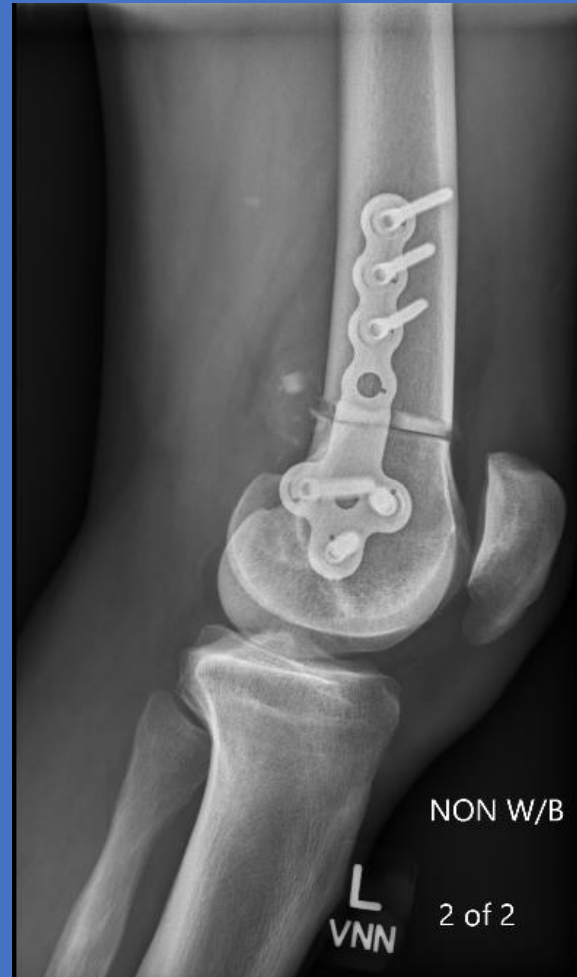Treatment

- Surgery
 - MACI LFC
 - DFO



Treatment

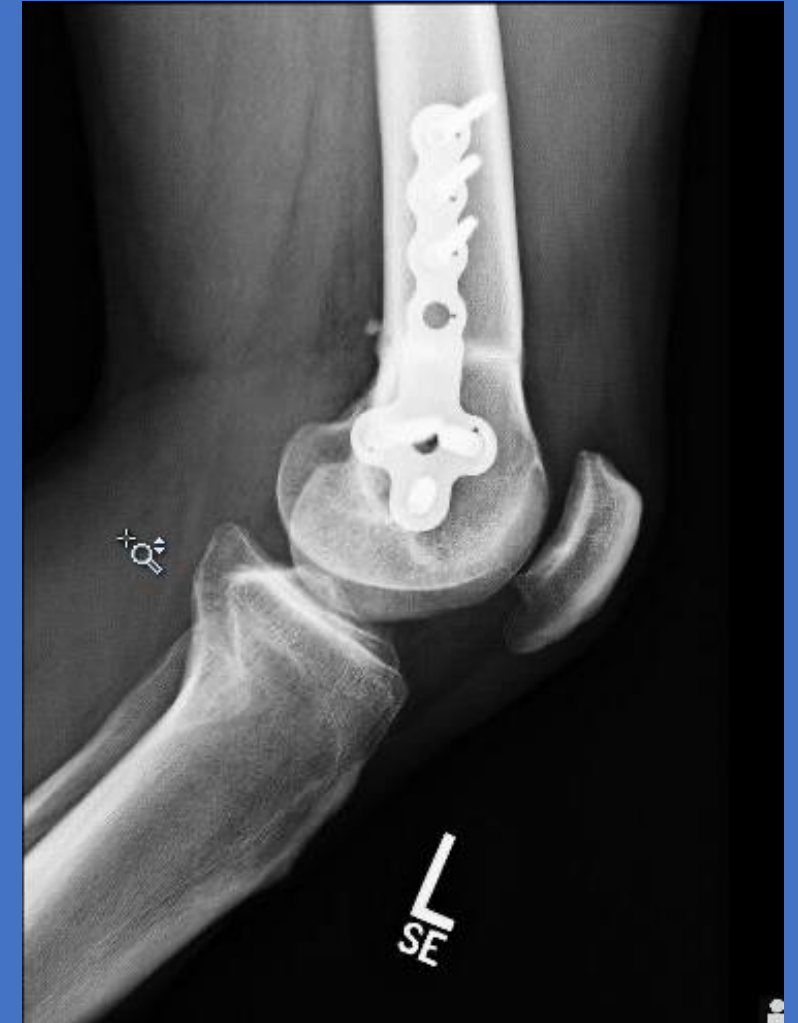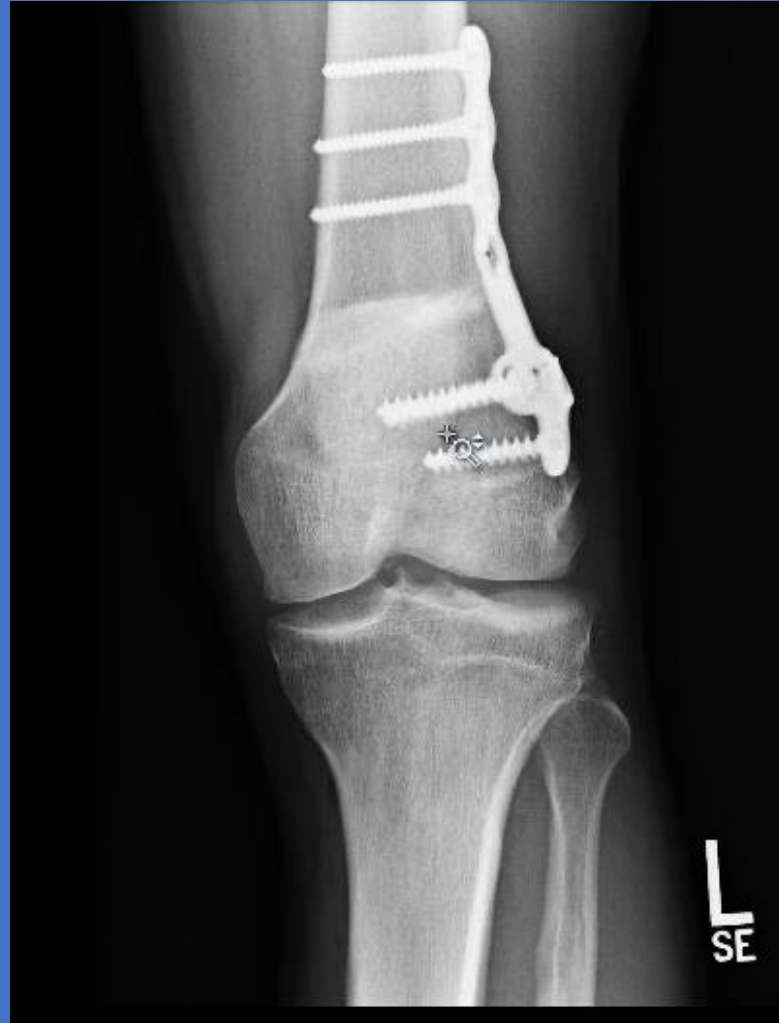- Surgery
 - MACI LFC
 - DFO



Post-op

Unremarkable post-op
Course

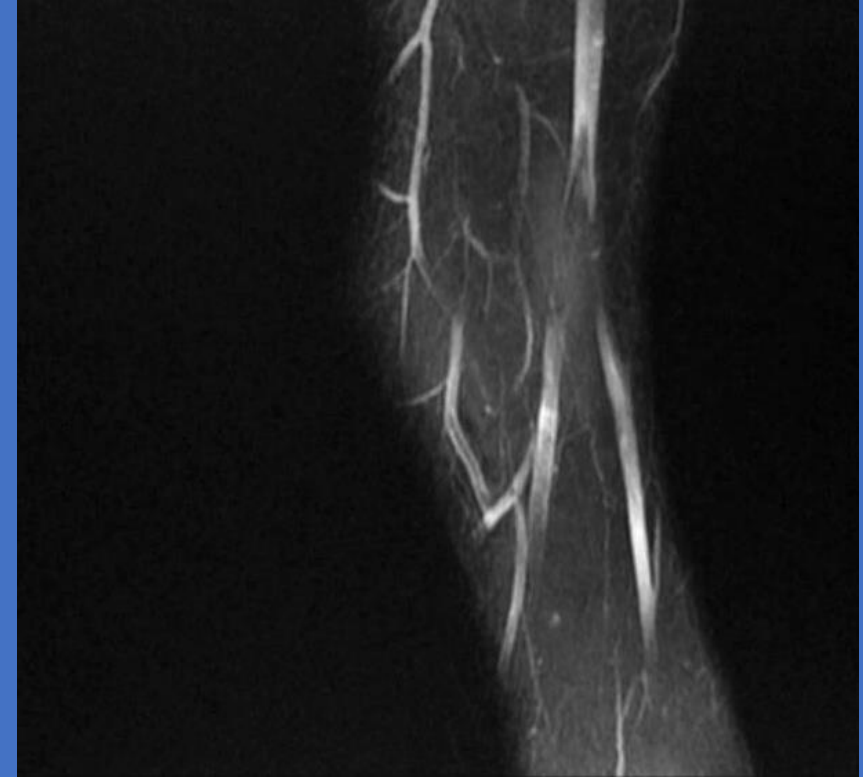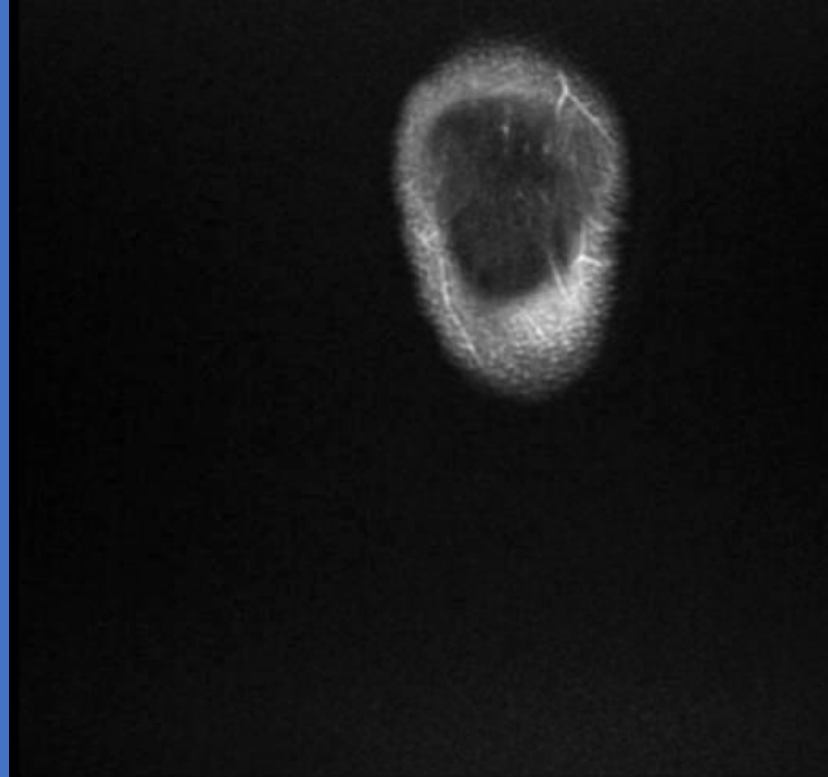
At 18 months,
developed some
“clicking” – pain over
distal ITB, lateral joint
line, near DFO plate



Post-op

Unremarkable post-op
Course

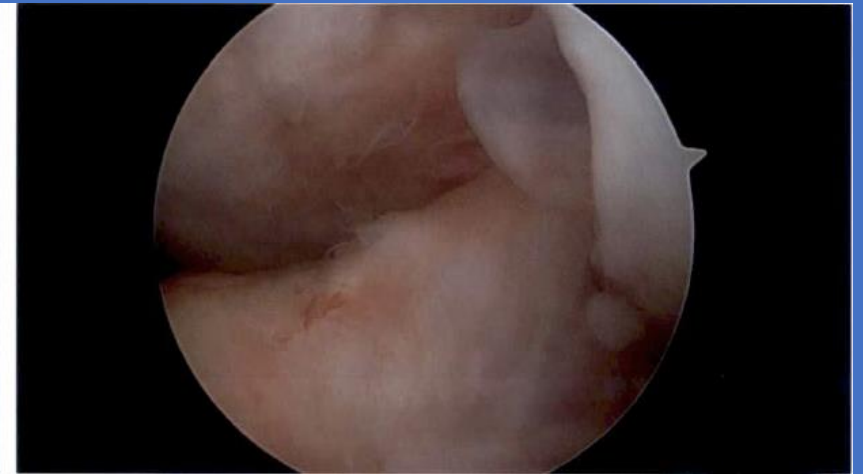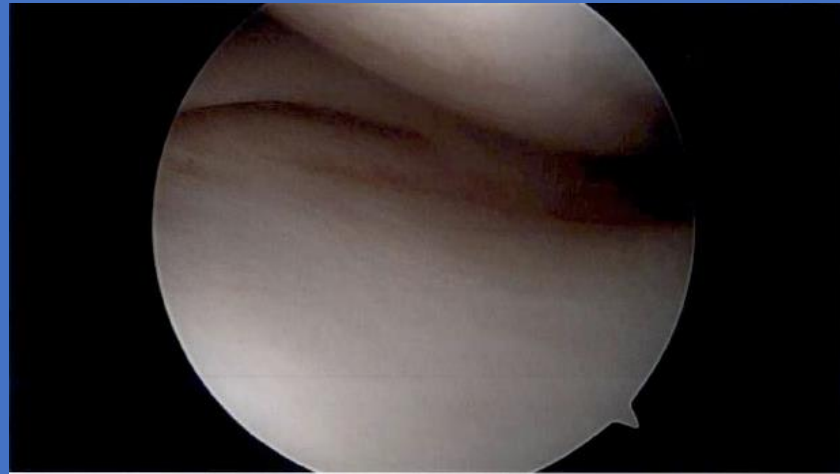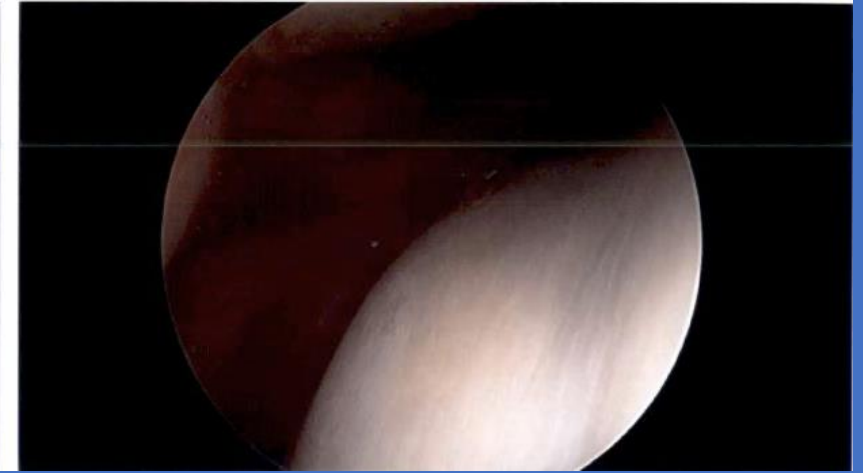
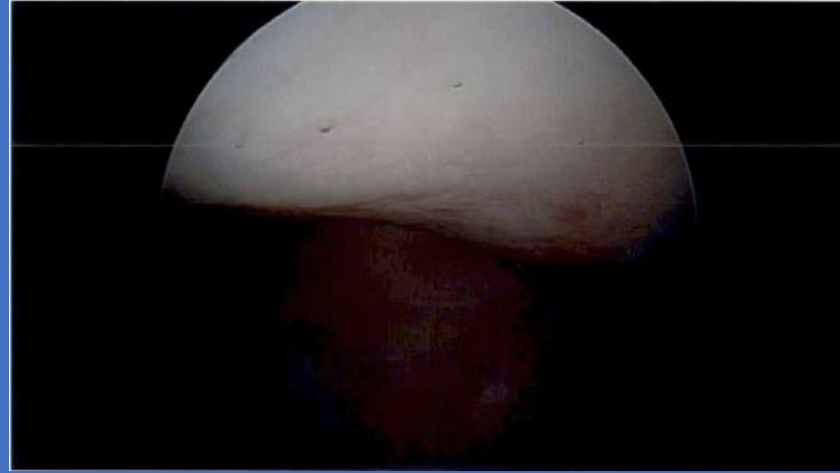
At 18 months,
developed some
“clicking” – pain over
distal ITB, lateral joint
line, near DFO plate



Second Look

Elects to proceed with
HWR and diagnostic
arthroscopy

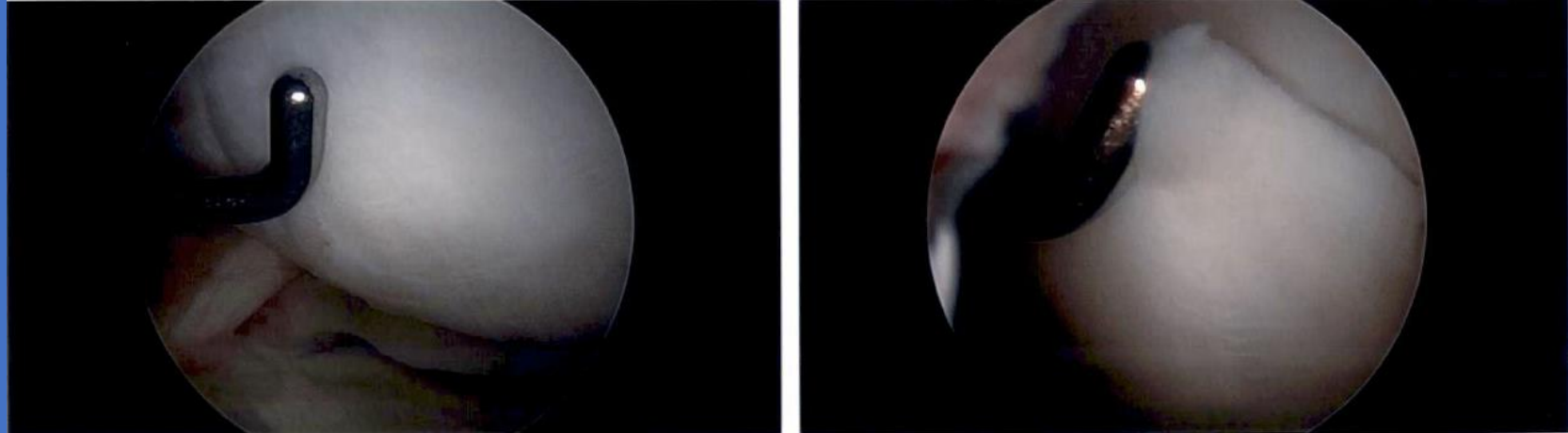
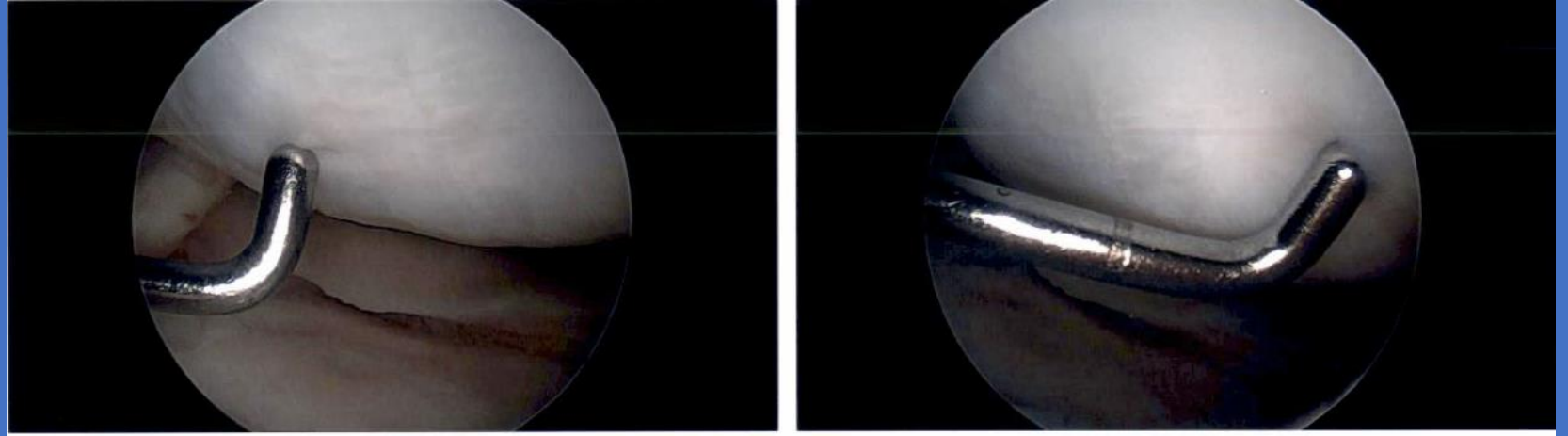
No new pathology PF or
medial compartment



Second Look

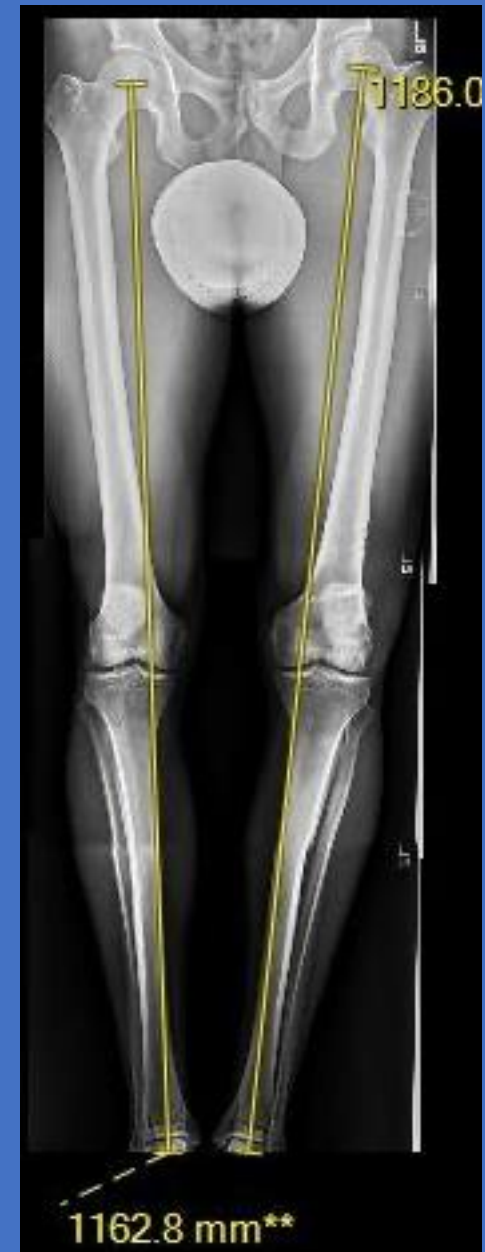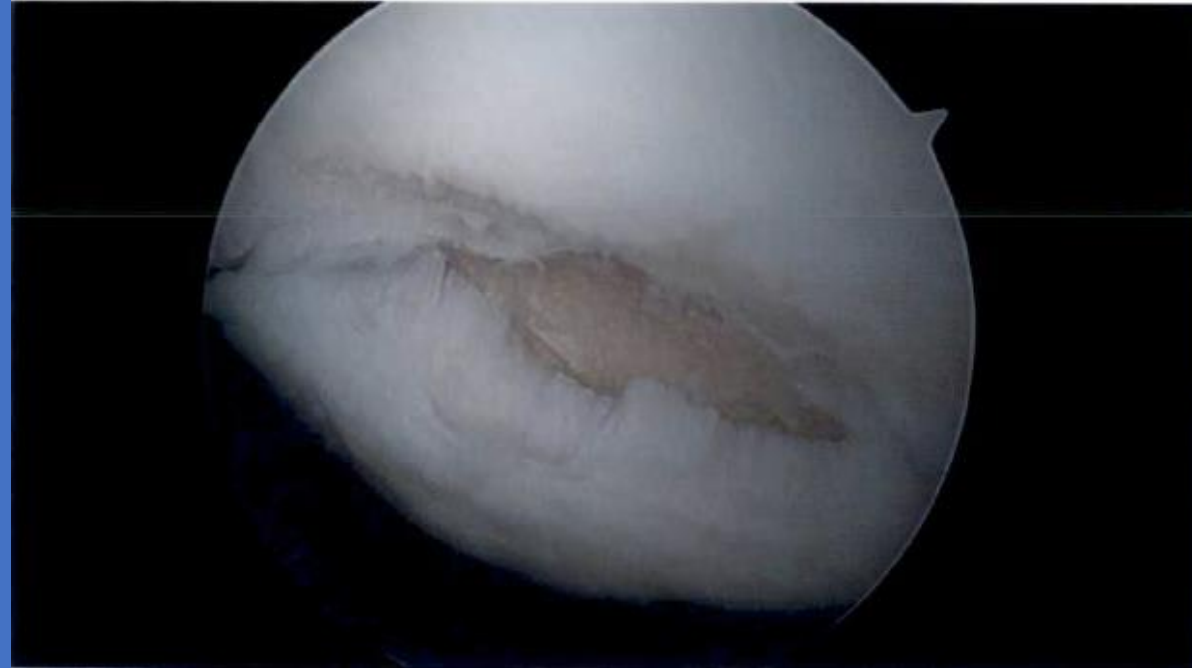
Lateral femoral condyle
has good fill

Unstable edge at
superior anterior LFC



Second Look

Chondroplasty and
plate removal



Case 4

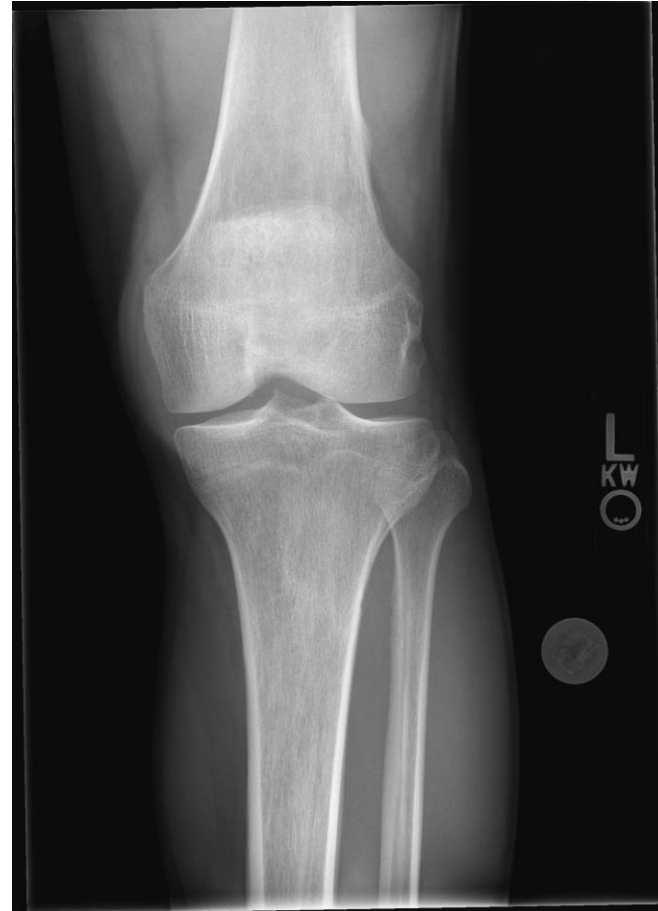+36yo male personal trainer

- 2-year history of knee pain/swelling after playing basketball
 - + Vague pain
- Underwent Left knee arthroscopy/chondroplasty at outside hospital, noted MFC and trochlear lesion
- Unable to return to activities 6 months after procedure
 - + 6 weeks post op, able to do all activities, but gradual performance decline since

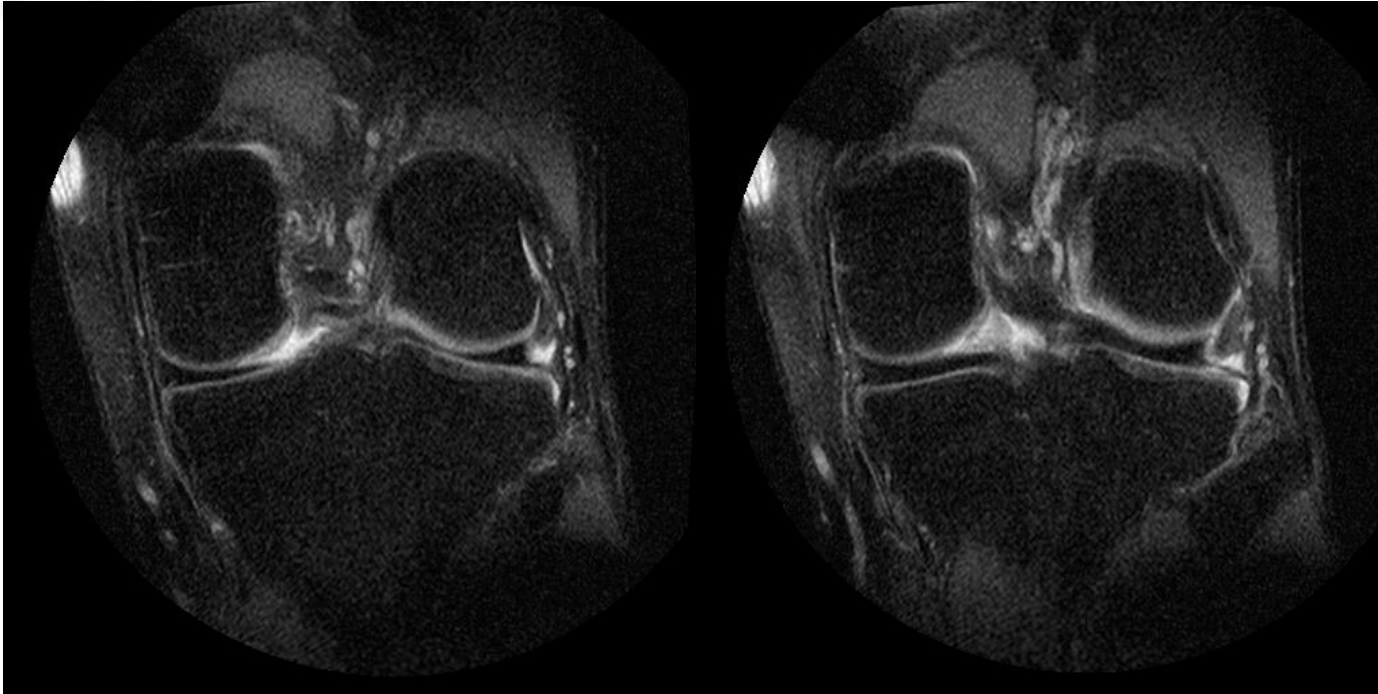
Physical Exam

+ Left knee exam

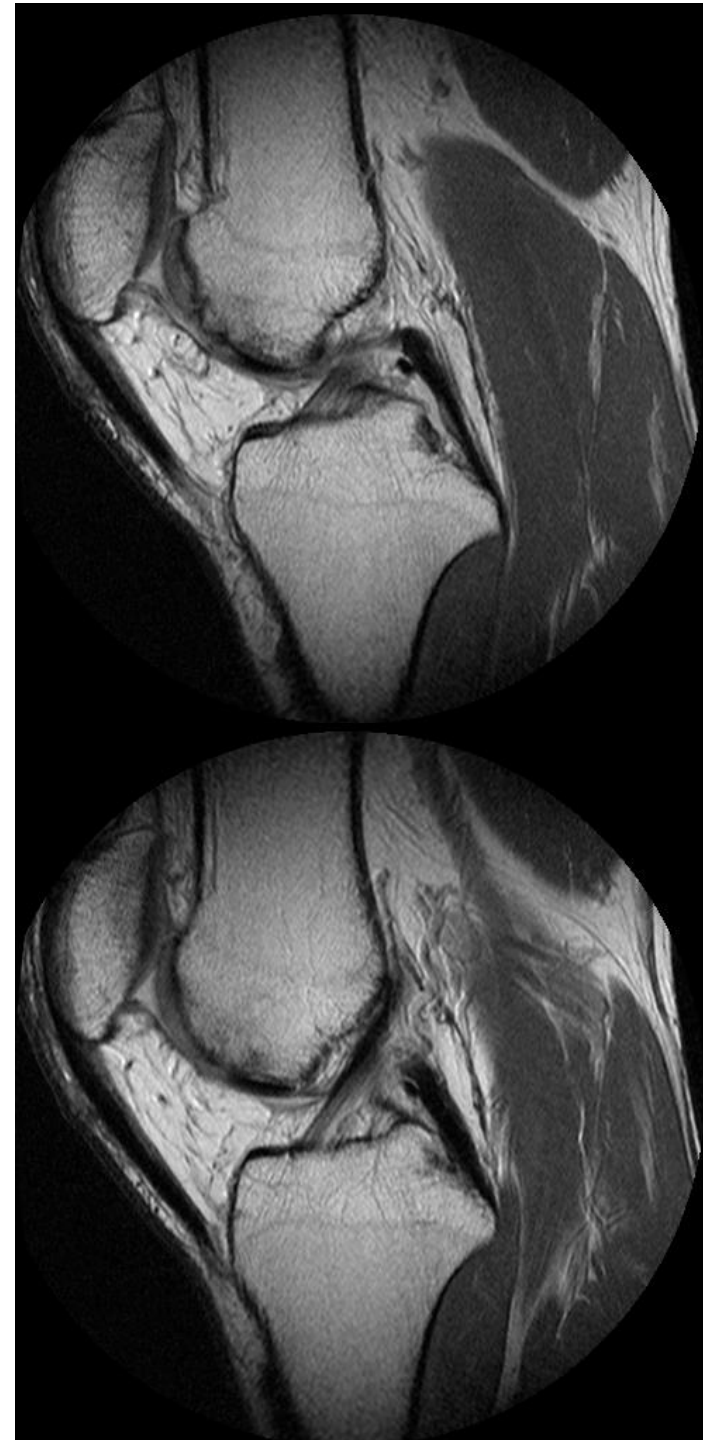
- No effusion
- FAROM
- NTTP joint line
- No crepitus
- Ligamentously stable




MRI



- + Grade 3 lesion MFC
- + Lesion on trochlea with intralesional osteophyte





✕ Thoughts?



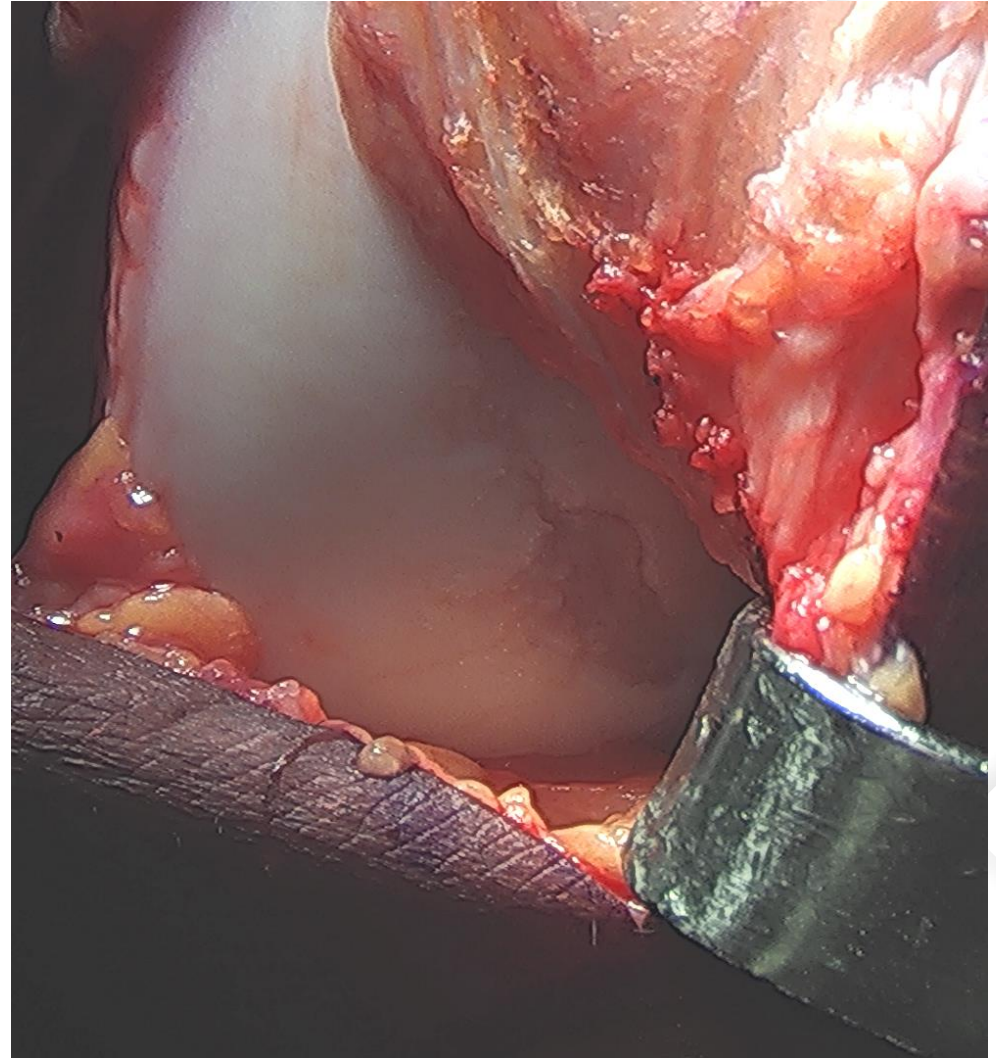
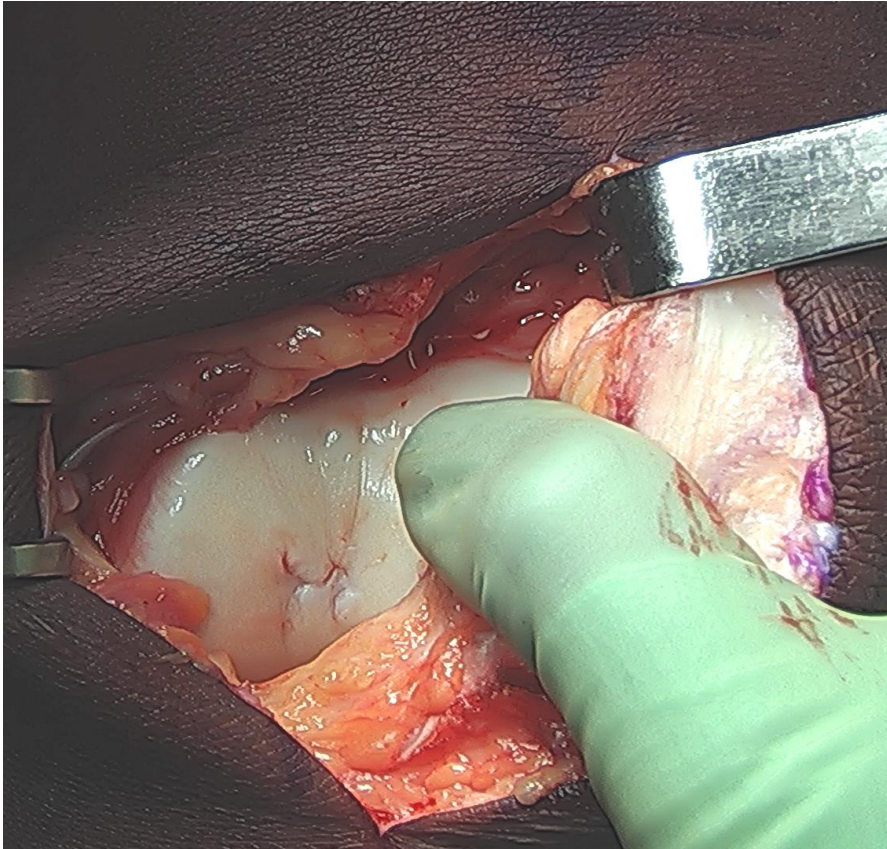


Medical Records sent

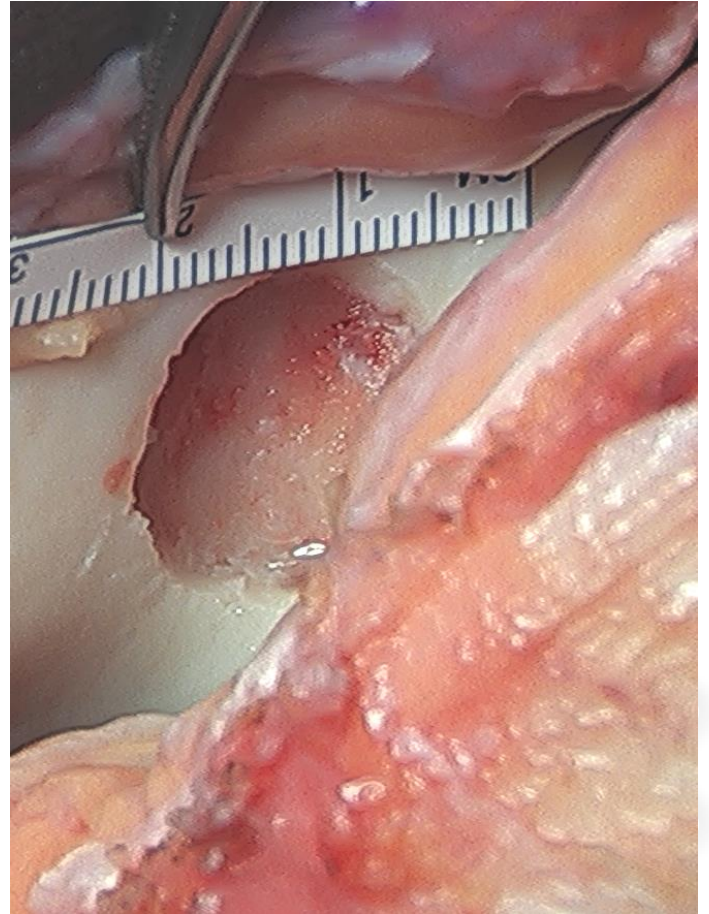
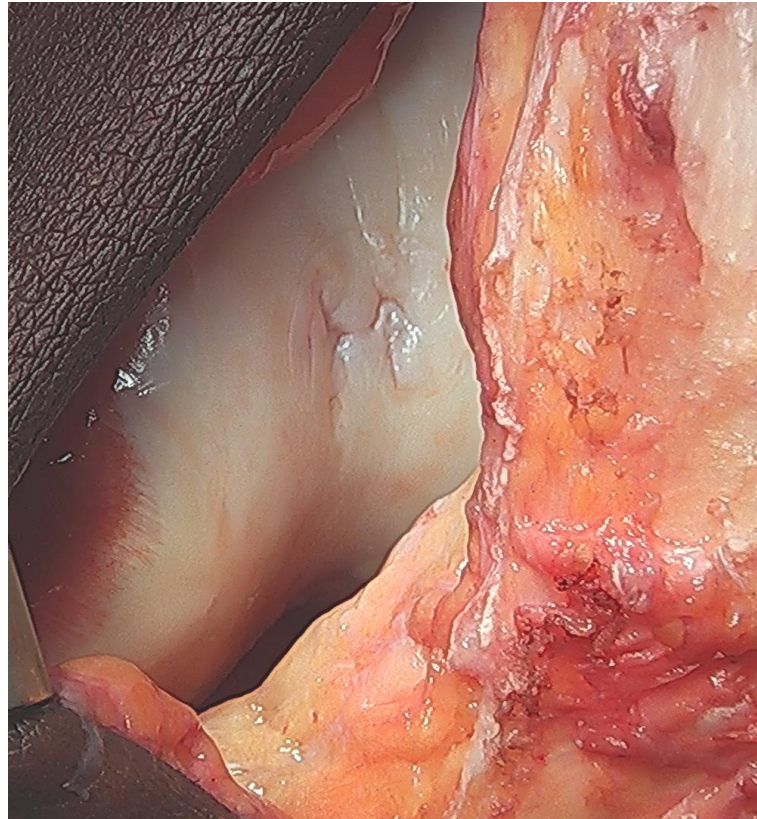
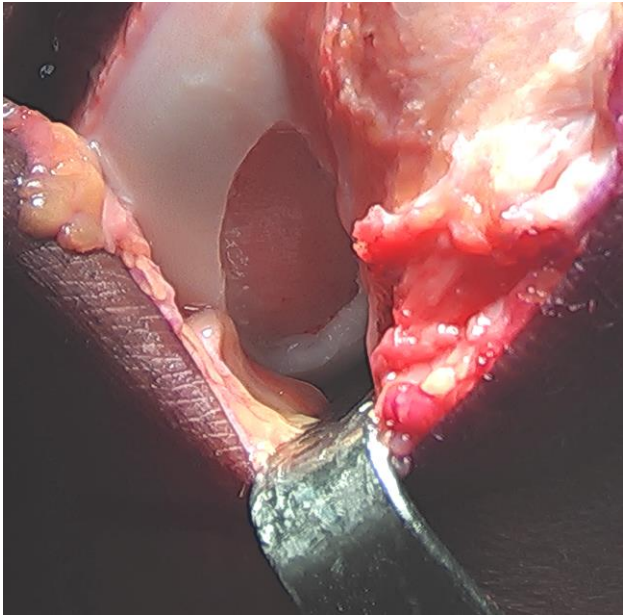
- + Central trochlear lesion 1.5 x 2cm
 - + Unclear MFC lesion based on pix

 - + Unable to squat, affecting his livelihood as Personal trainer.
 - + Failed conservative measures
- 
- 

MACI - identification of lesion



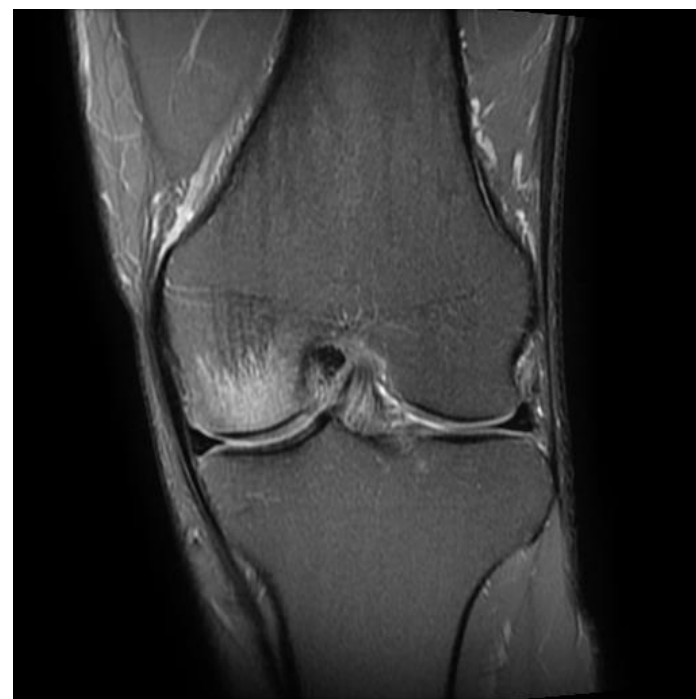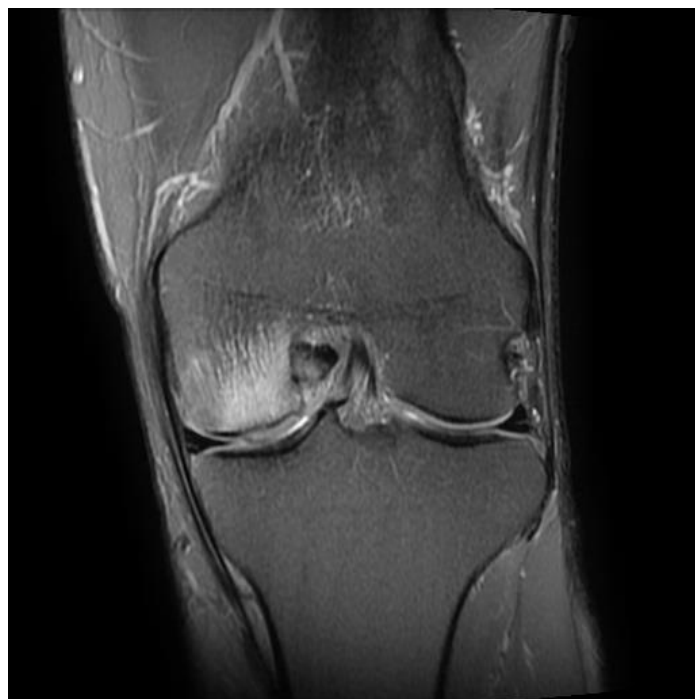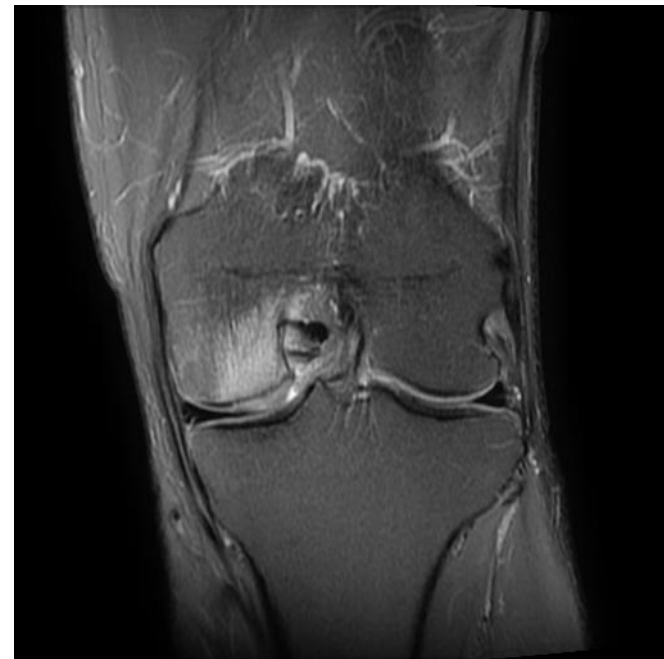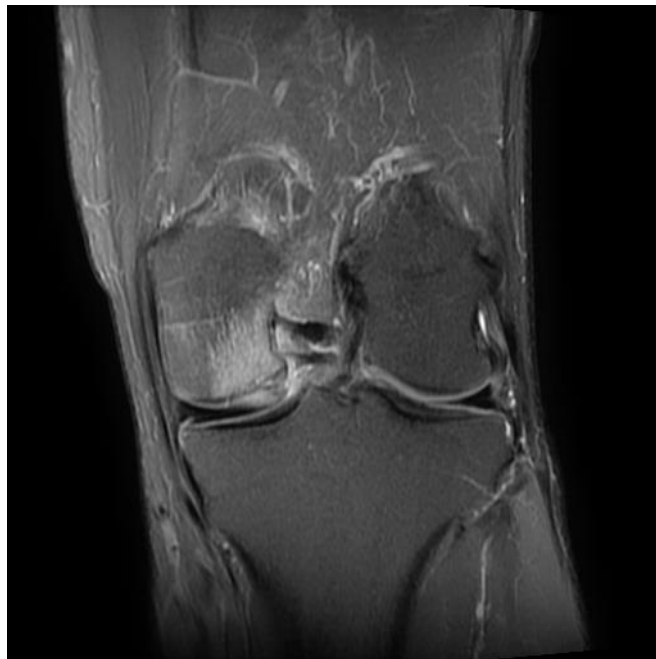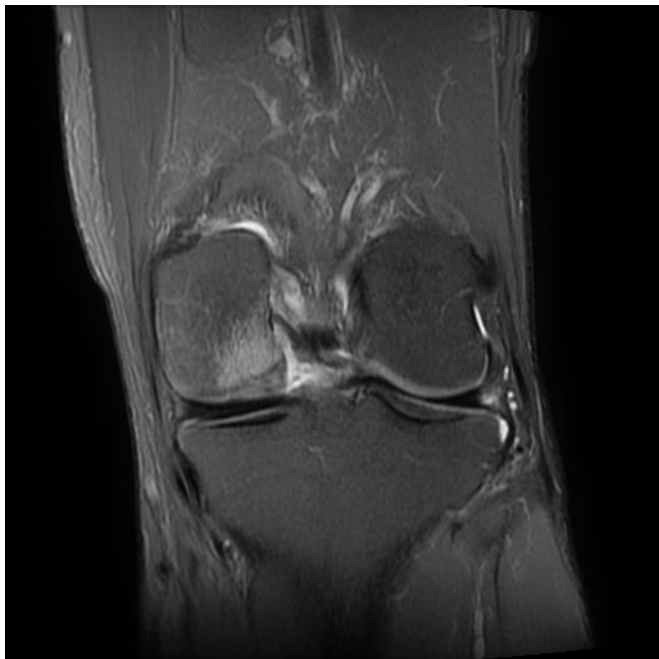
MACI implantation



Post-op f/u

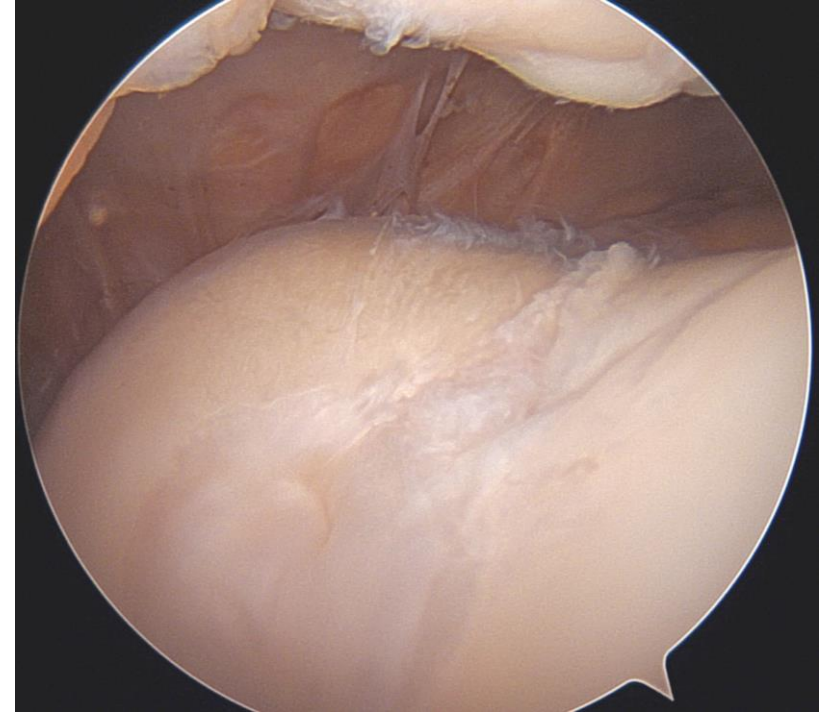
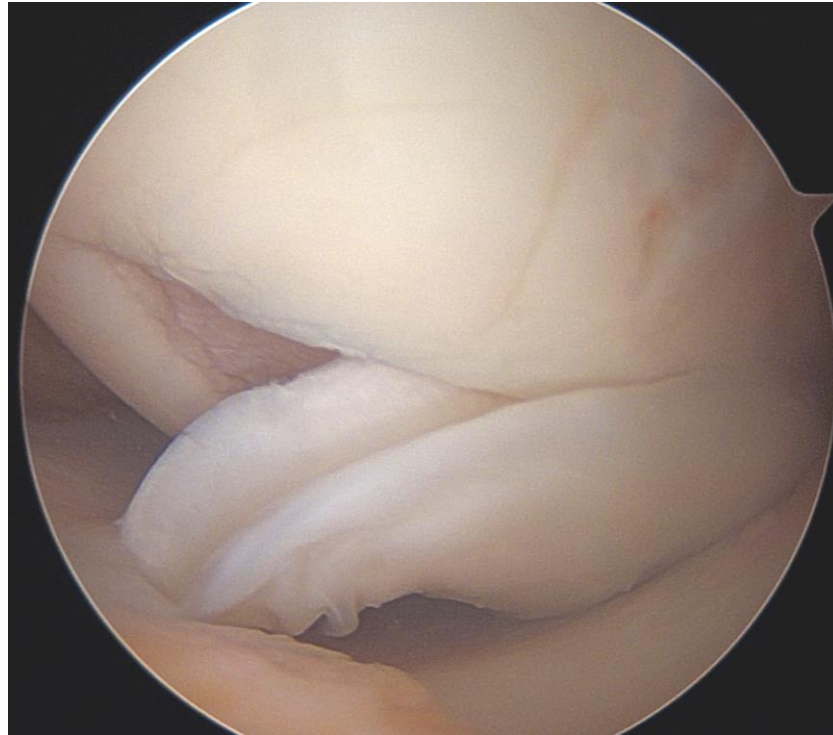
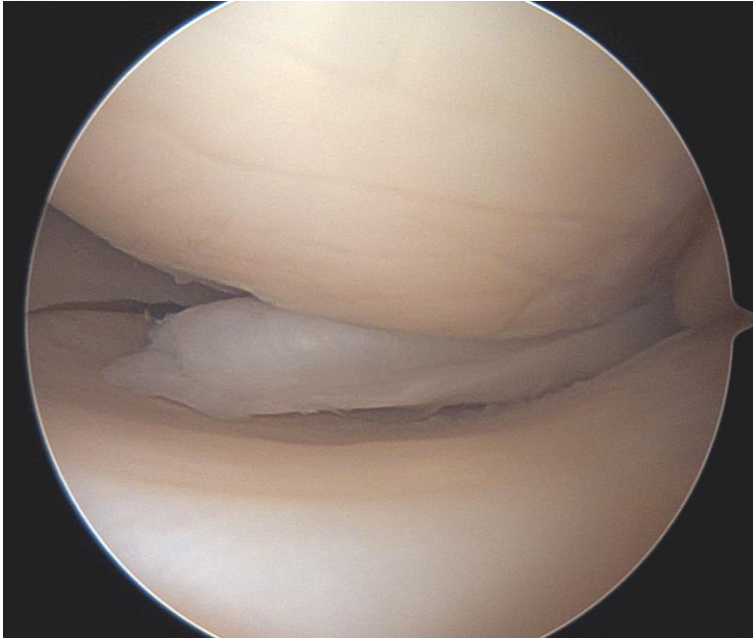
- +7 months, lightly jogged across the street, noted mild pain medially and then swelling, resolved
- +10 months post op – continued to rehab, but started noting sharp pain with flexion around 30 degrees
- +MRI at 13 months post implantation


X MRI



X

2nd look arthroscopy



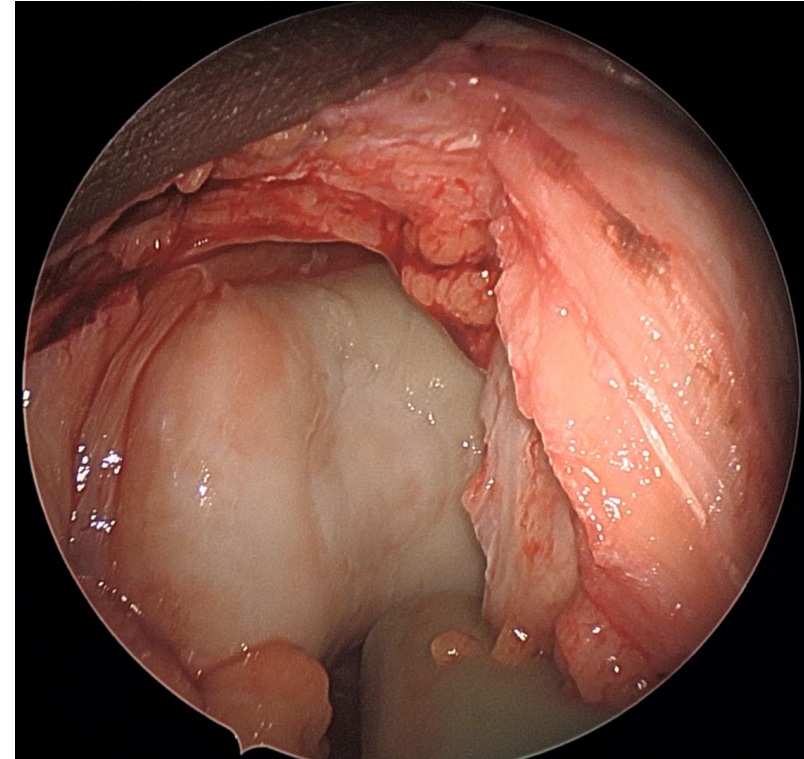
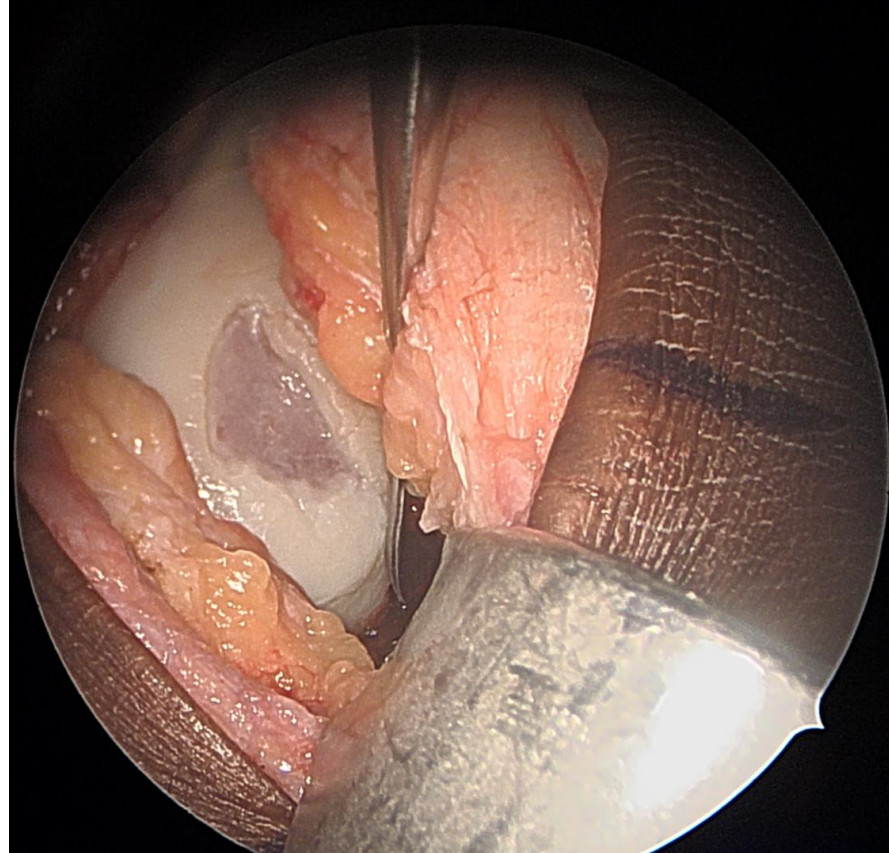
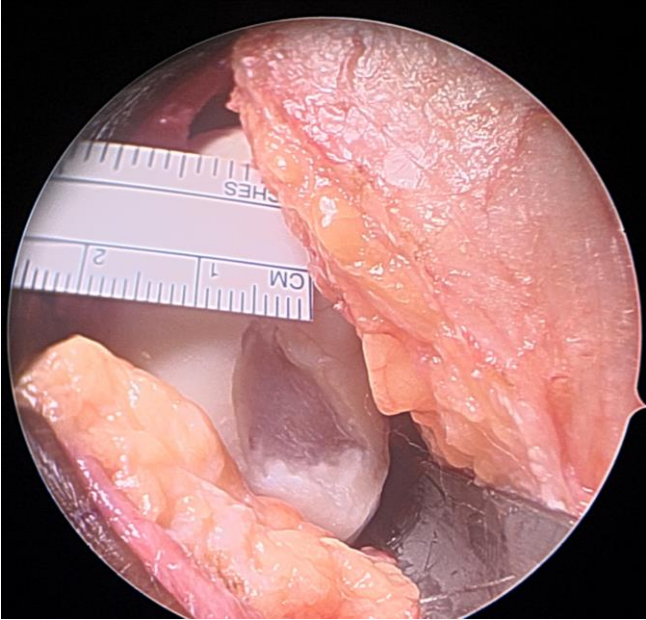


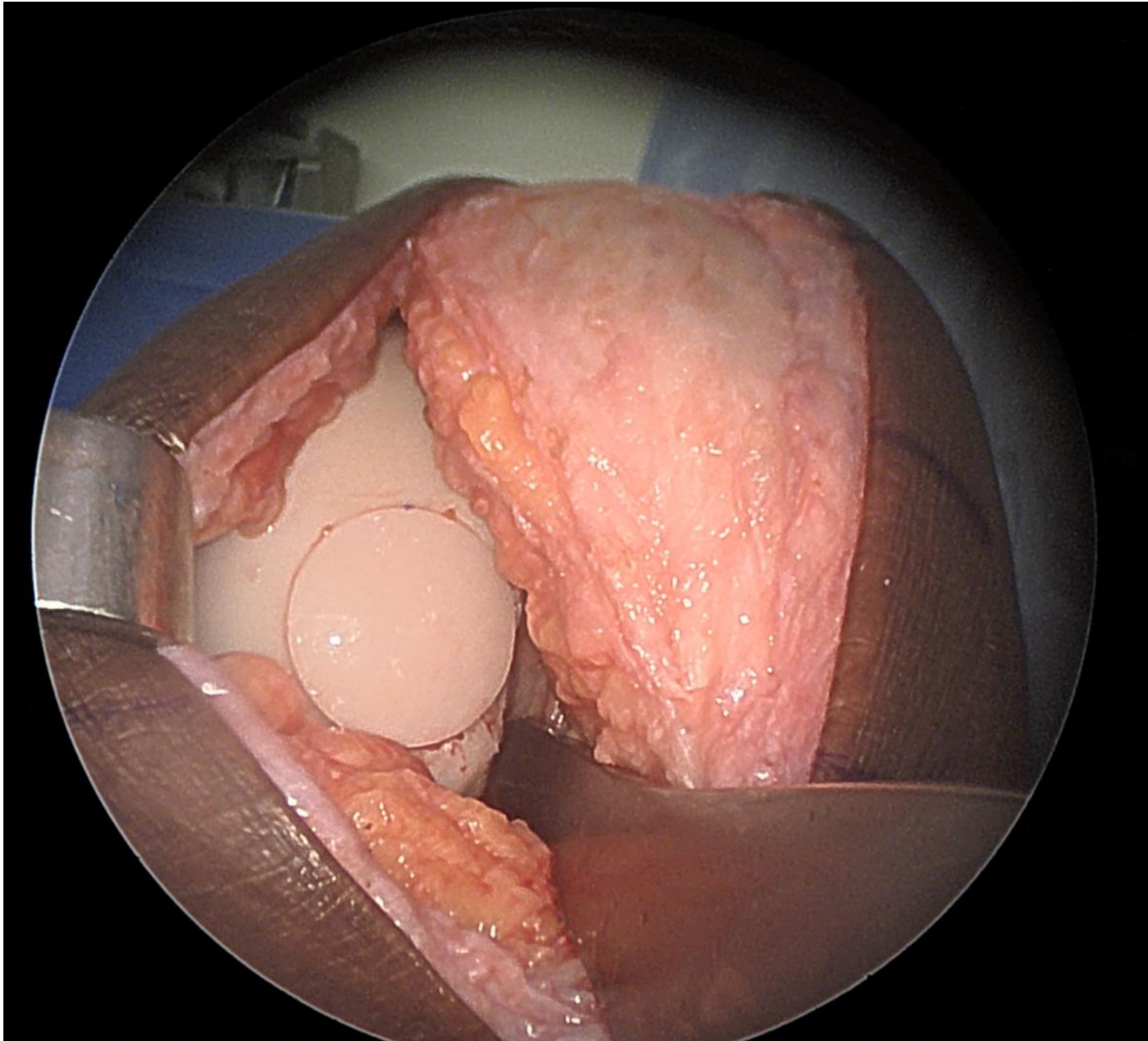
X Options?

- + What went wrong?
- + What now?



Osteochondral allograft





Case #5

Patient Demographics

Age/Gender:

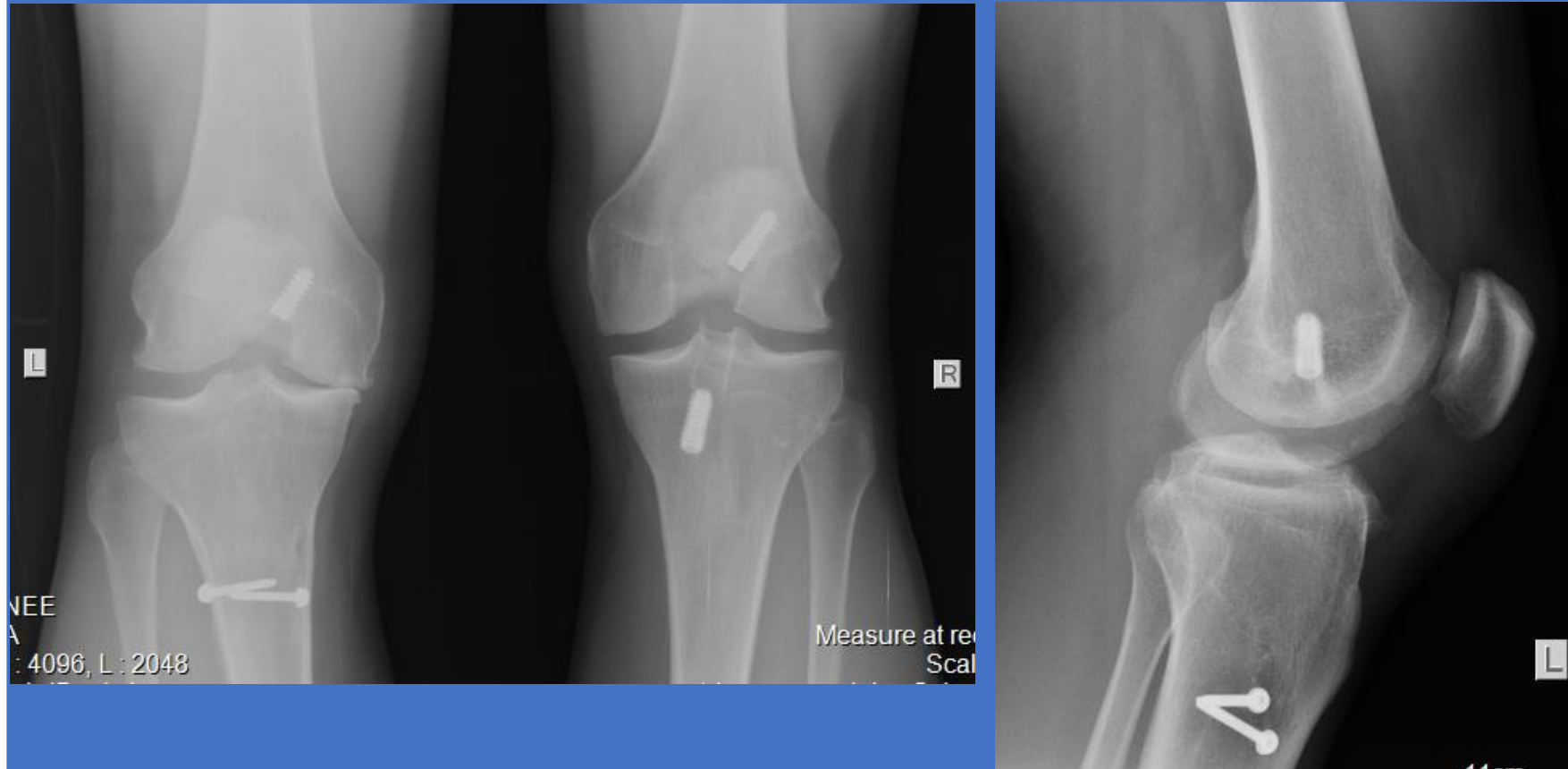
- 33 yo male

Hx Presentation:

- Fedex Delivery
- Slipped downstairs, hyperextension injury
- Prior surgery

Pre-Images

Xray



Case #5

Patient Demographics

Exam Findings:

- ROM 0-138
- Medial jointline TTP
- Lateral jointline TTP

Pre-Images

MRI

- Post surgical changes from prior PCL reconstruction
- Complex medial meniscus tear with extrusion
- Full thickness chondral loss MFC with marginal osteophytes

Treatment

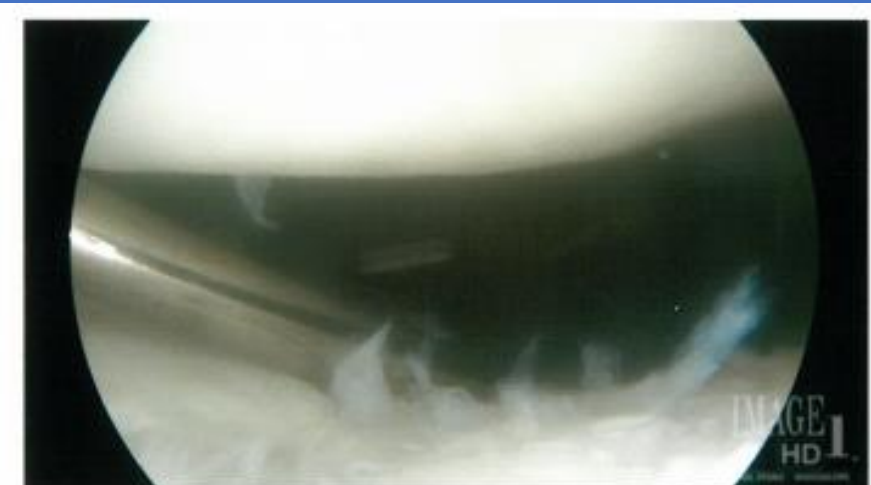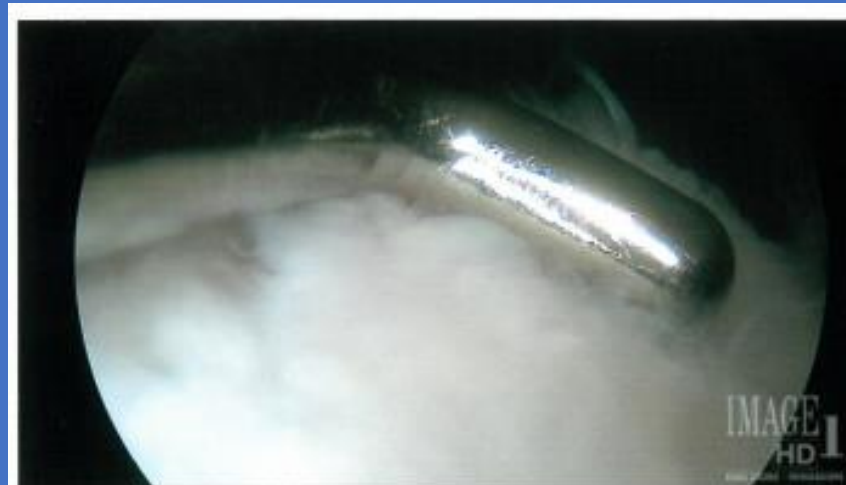- Physical therapy
- NSAIDs
- Viscosupplementation
- Bracing
- 5 years prior knee arthroscopy with PLM, chondroplasty trochlea, MFC/LFC for mechanical symptoms
- Pre-existing PCL reconstruction from soccer injury in High School

Treatment

- May 2018
- Diagnostic Scope Pics
 - MFC Grade 4, 0-90 measuring 3x5cm
 - MTP Grade 4 1x1.5cm
 - Femoral trochlea 3x4cm
 - LFC minimal chondromalacia
 - Biopsy obtained

Diagnostic Scope Pics

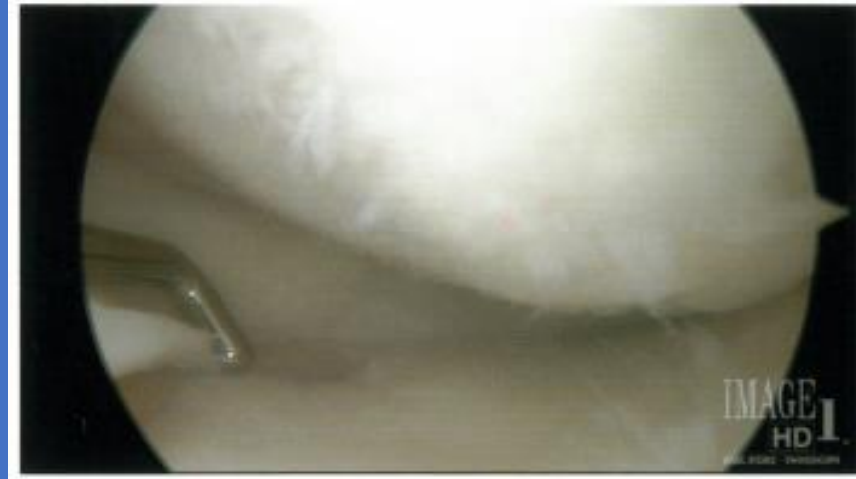-- Trochlea



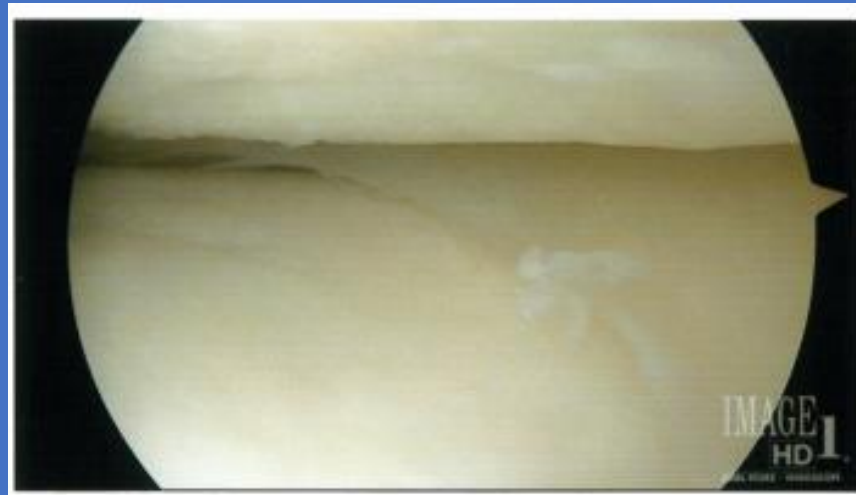Treatment

- May 2018
- Diagnostic Scope Pics
 - MFC Grade 4, 0-90 measuring 3x5cm
 - MTP Grade 4 1x1.5cm
 - Femoral trochlea 3x4cm
 - LFC Grade 2/3
 - Biopsy obtained

Diagnostic Scope Pics MFC



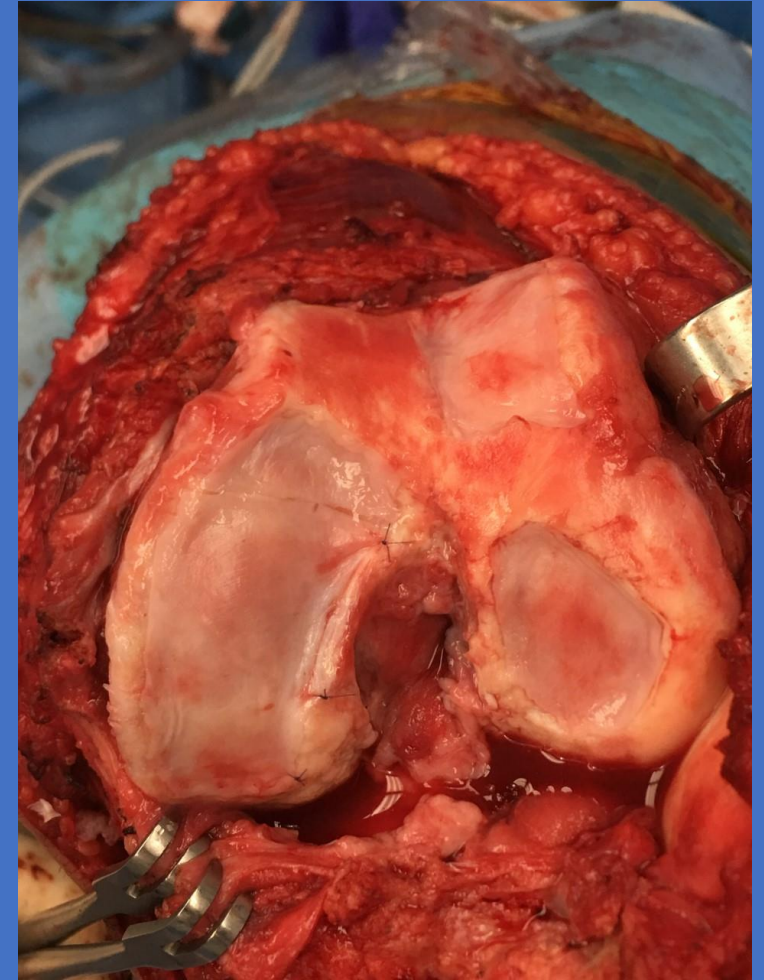
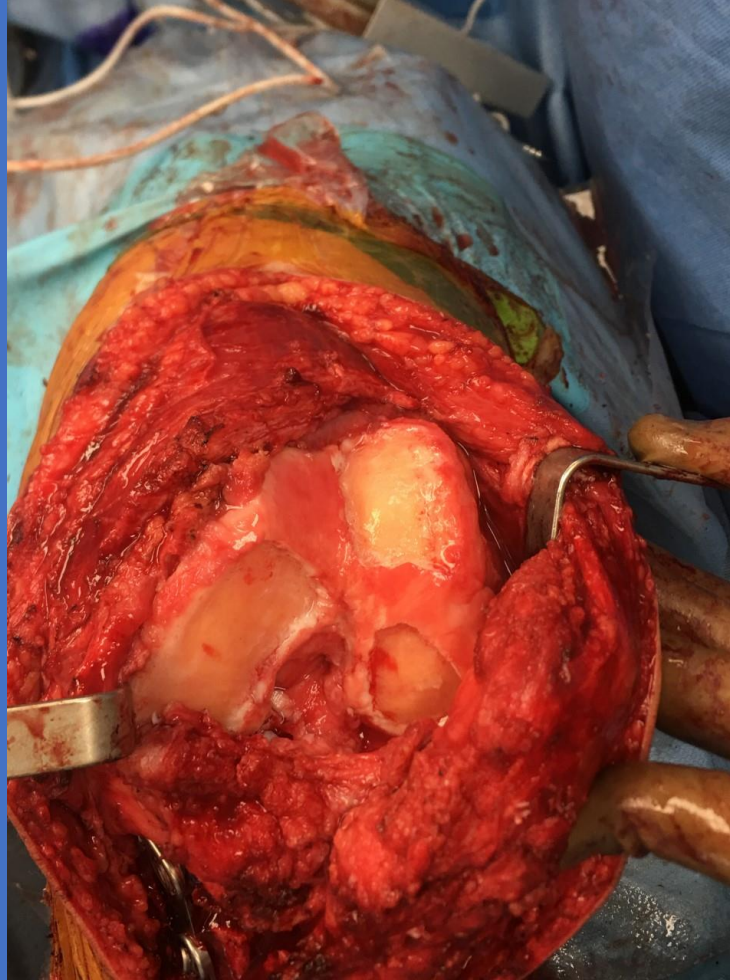LFC



Treatment

- Surgery
 - MACI MFC
 - MACI LFC
 - MACI Trochlea
 - HTO
 - TTO
 - Lateral Release

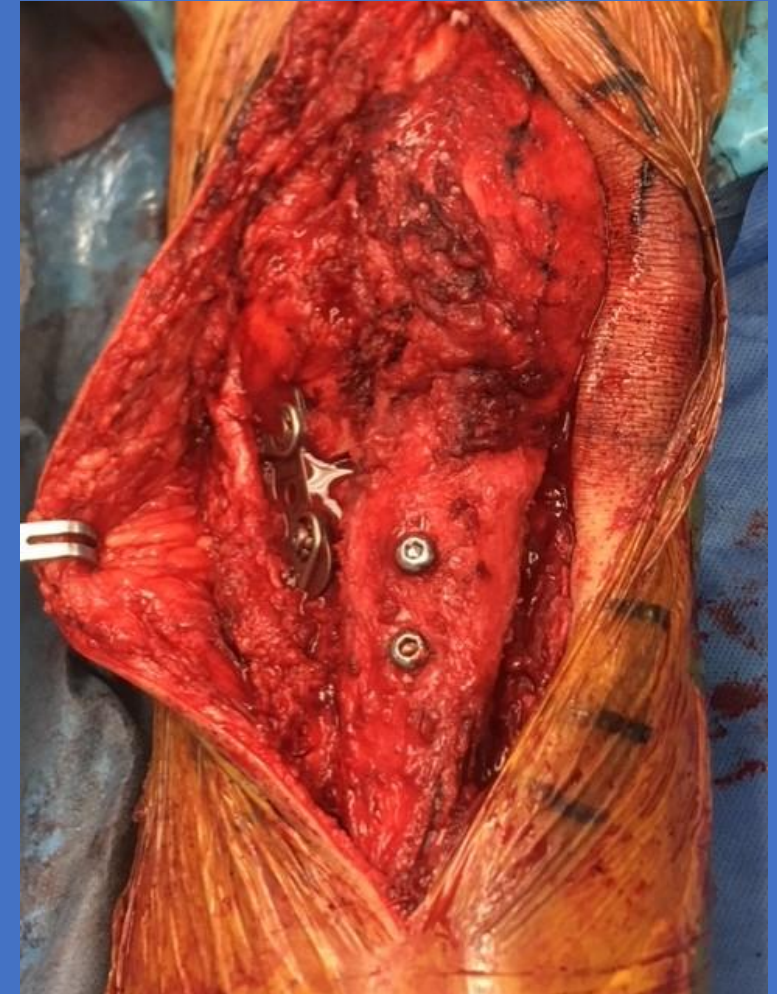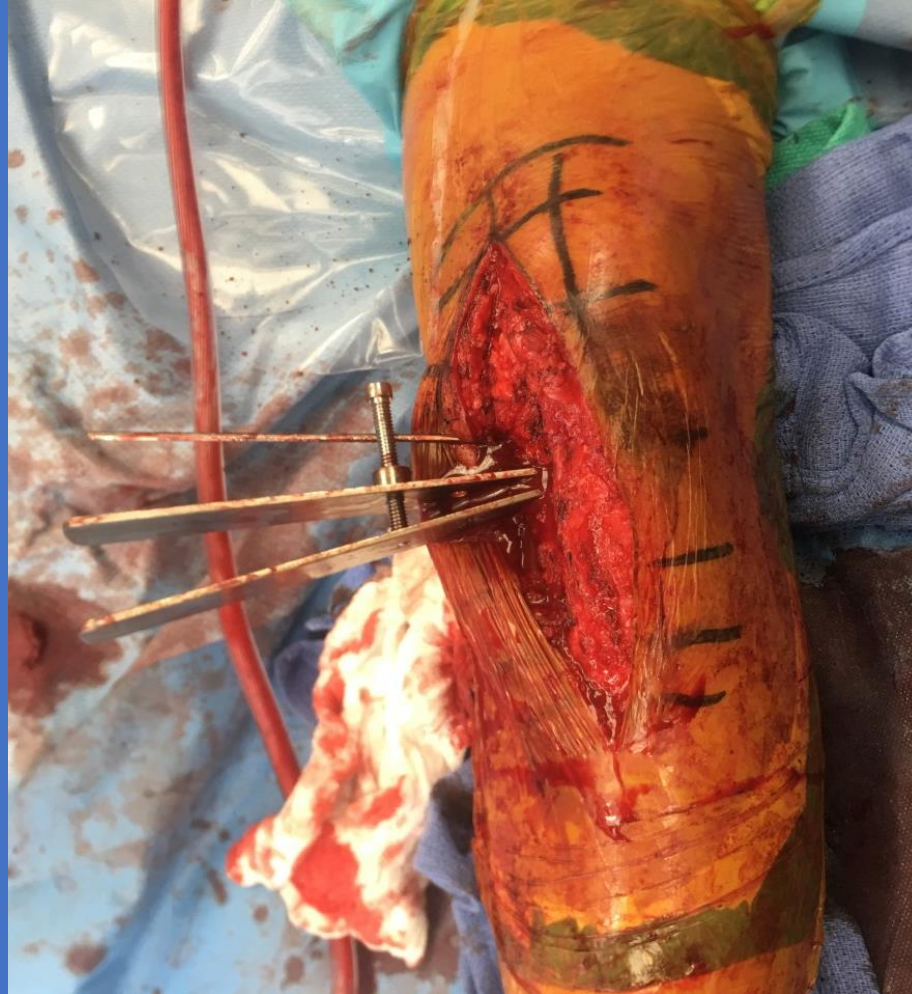MACI prep/post-implantation



Treatment

- Surgery
 - MACI MFC
 - MACI LFC
 - MACI Trochlea
 - HTO
 - TTO
 - Lateral Release

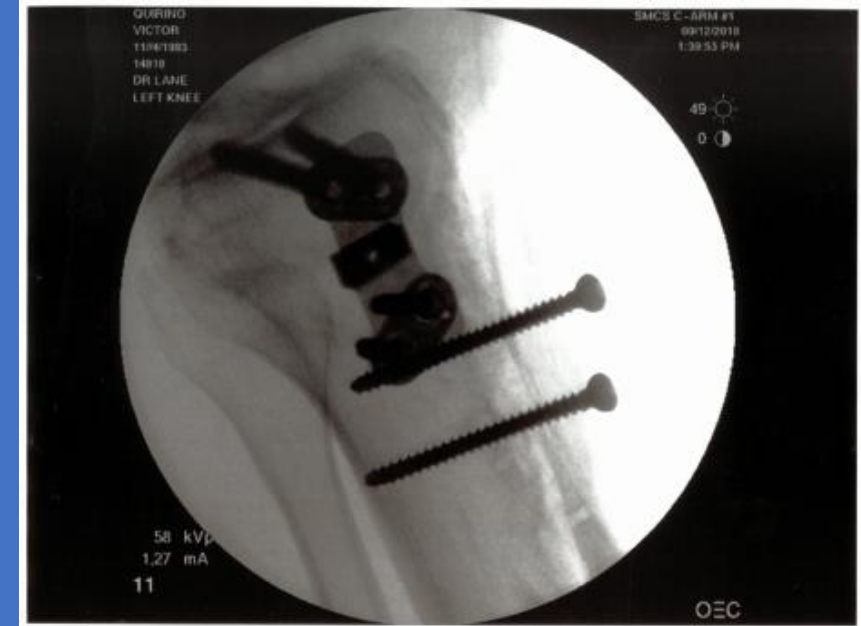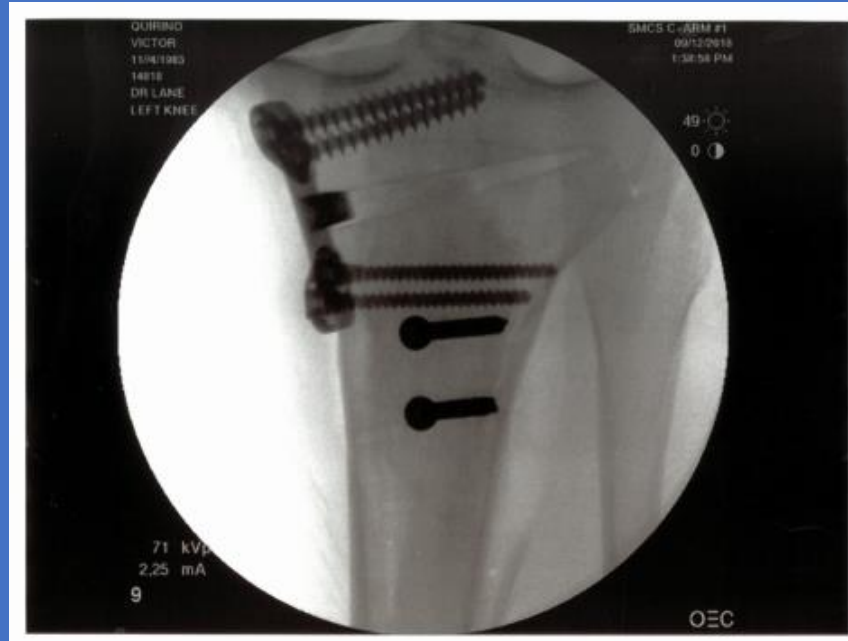Osteotomy



Treatment

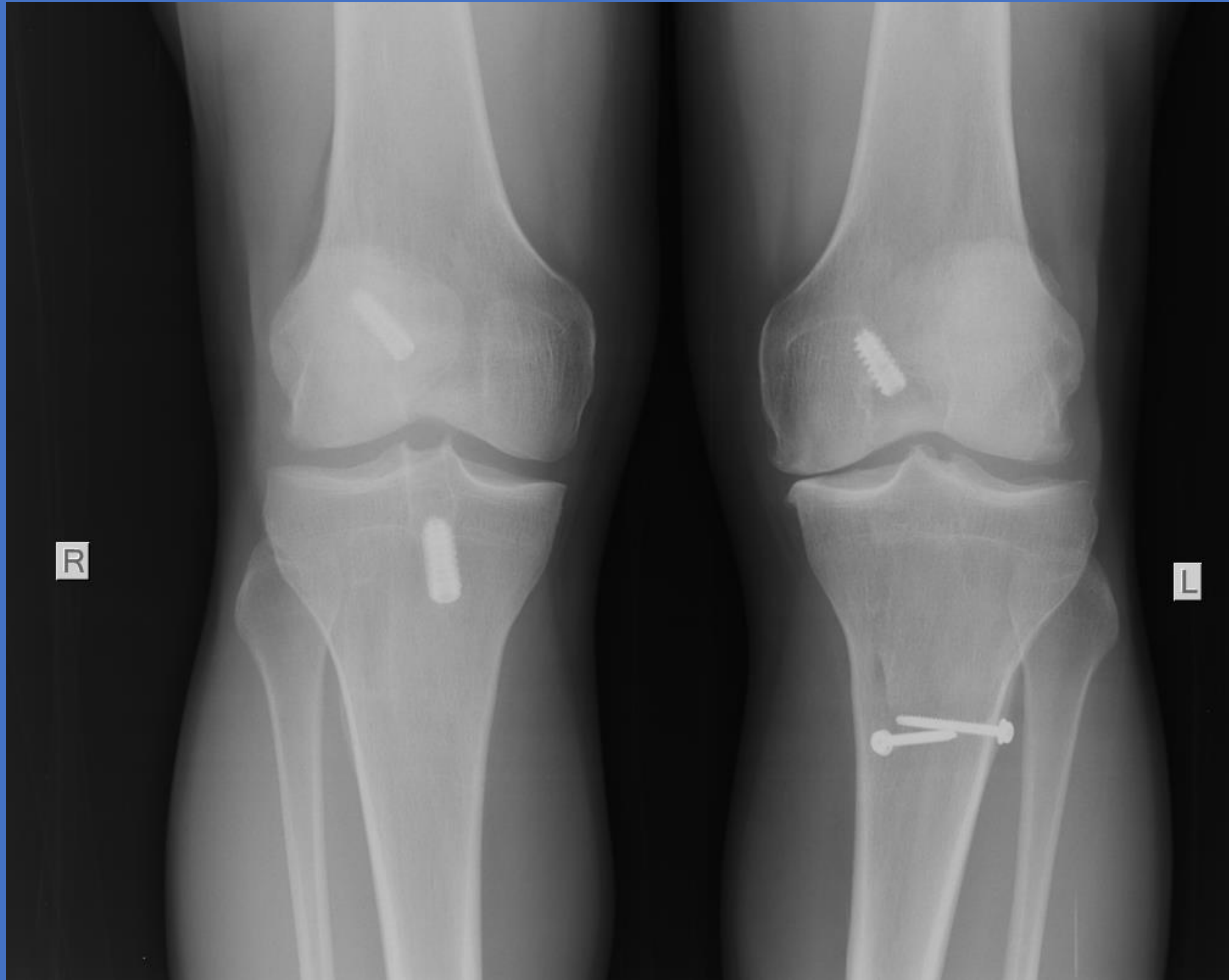
- Surgery
 - MACI MFC
 - MACI LFC
 - MACI Trochlea
 - HTO
 - TTO
 - Lateral Release

Post op fluoroscan images

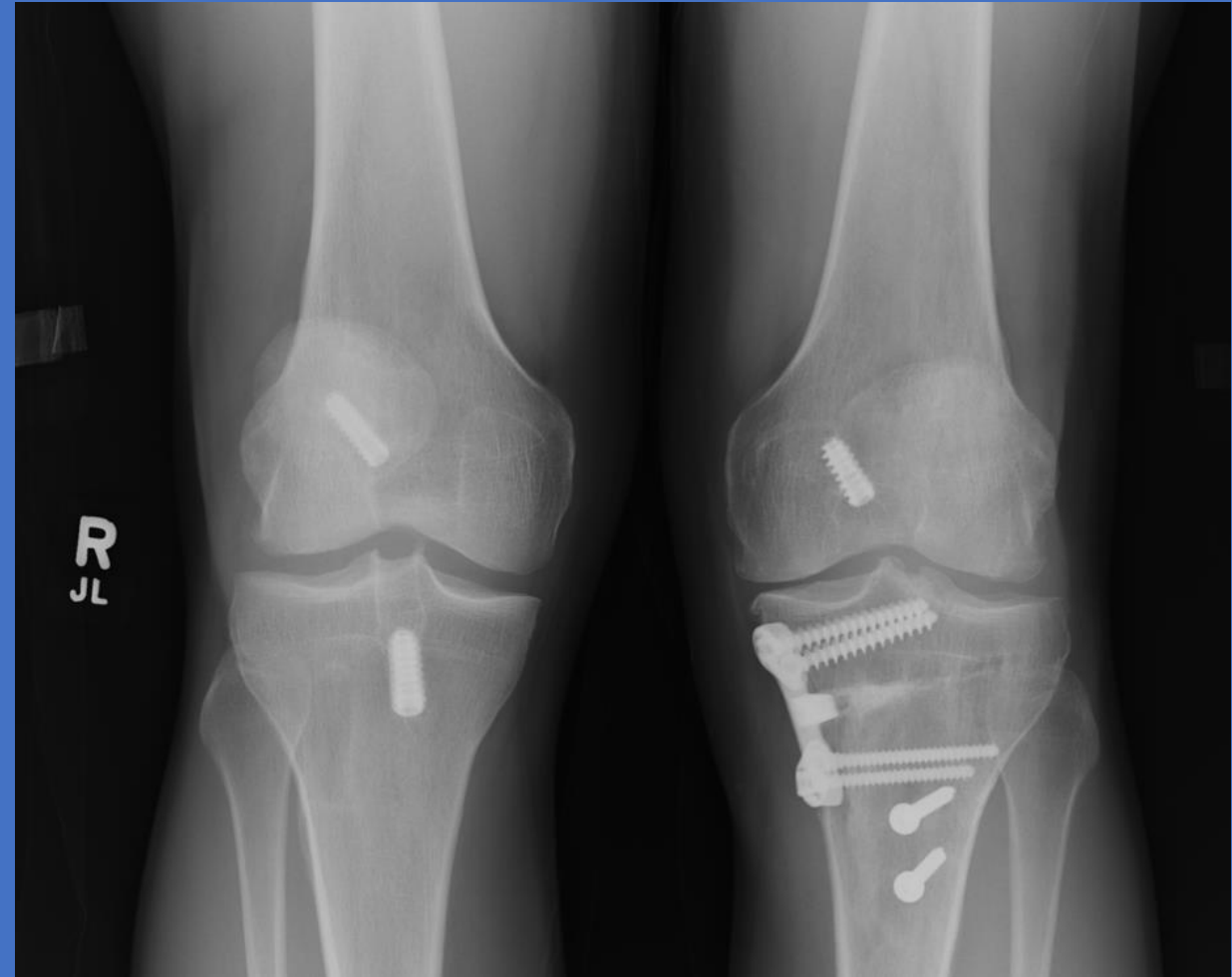


Before / After Alignment

Pre-op standing AP



Two years postop standing AP



Post-op Complications and Rehabilitation

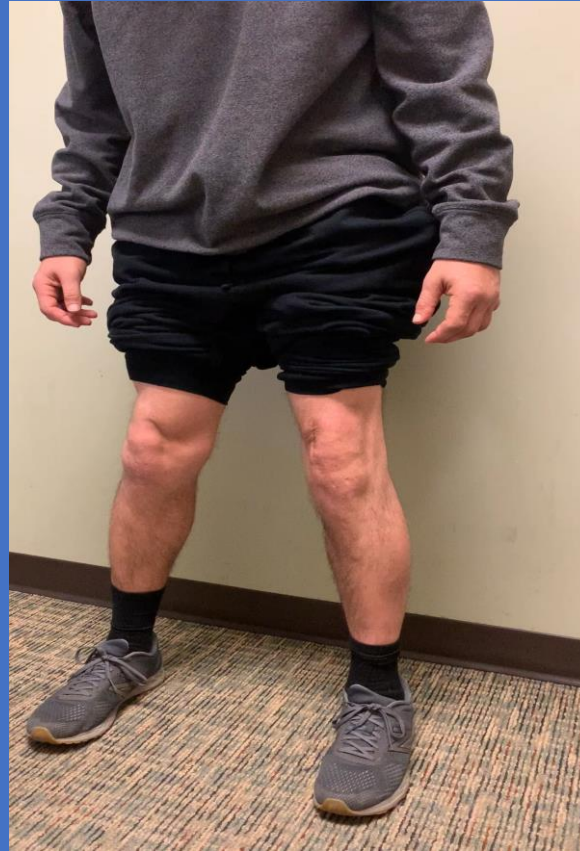Complications: None

Rehabilitation:

- CPM 0 to 30° for 2 weeks, 0 to 65° for 2 to 6 weeks
- ROM knee brace locked 0 to 30° for six weeks, progress ROM to pain tolerance at six weeks, 0-110° at six weeks, 0 to FROM at 12 weeks
- TTWB for 6 weeks, then progressive partial weightbearing 50 lbs every 1-2 weeks until FWB, FWB at 12 weeks and weaned from ambulatory assistive device once pain free
- Start formal physical therapy at 6 weeks postop with ROM, isometrics
- Progress physical therapy strengthening 12 weeks postop
- Sedentary duties at 12 weeks post-op, trial of full duty as Fed Ex deliveryman at one year post-op

Rehabilitation

Patient Squatting Video



Case #6

Patient Demographics

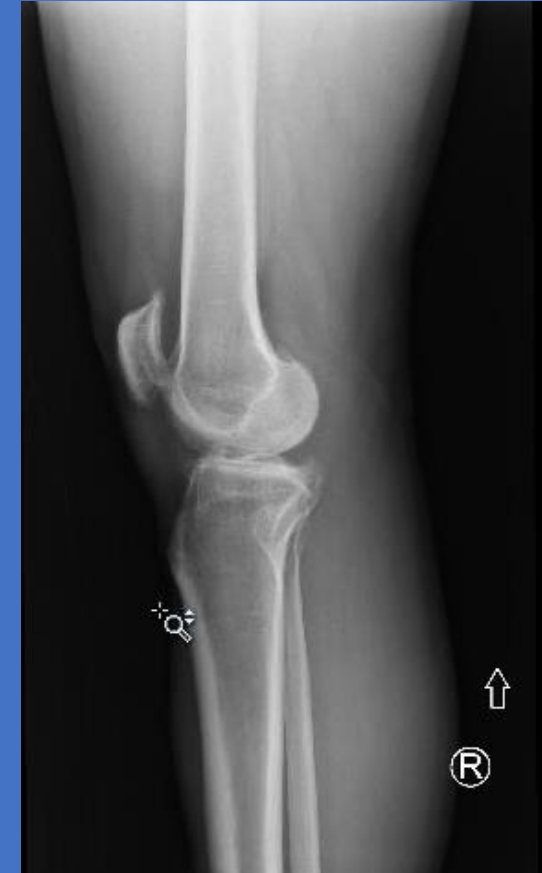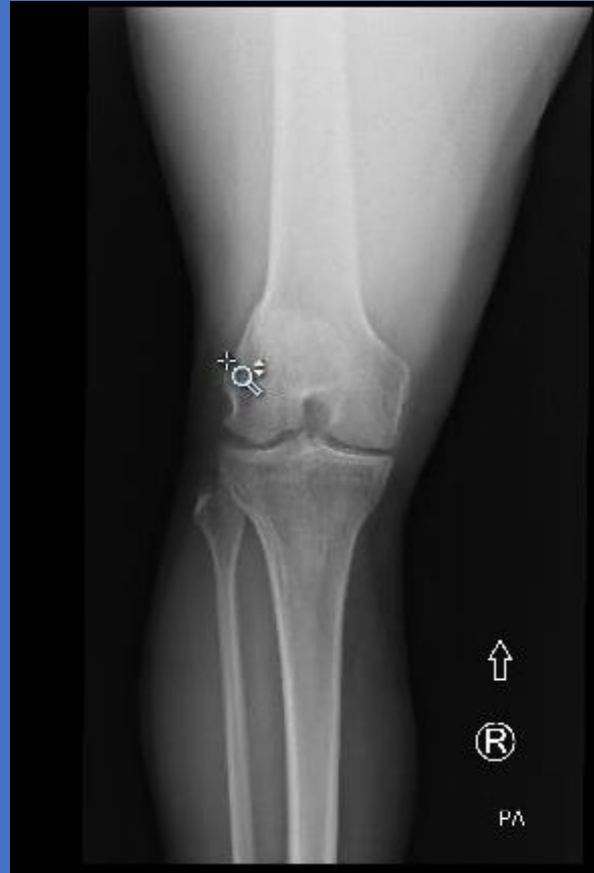Age/Gender:

- 42 year old male

Hx Presentation:

- 4 yr history of right knee injury while playing basketball
- Had a knee arthroscopy with partial medial menisectomy
- Several rounds of physical therapy and viscosupplementation
- No improvement

Pre-Images



Case #6

Patient Demographics

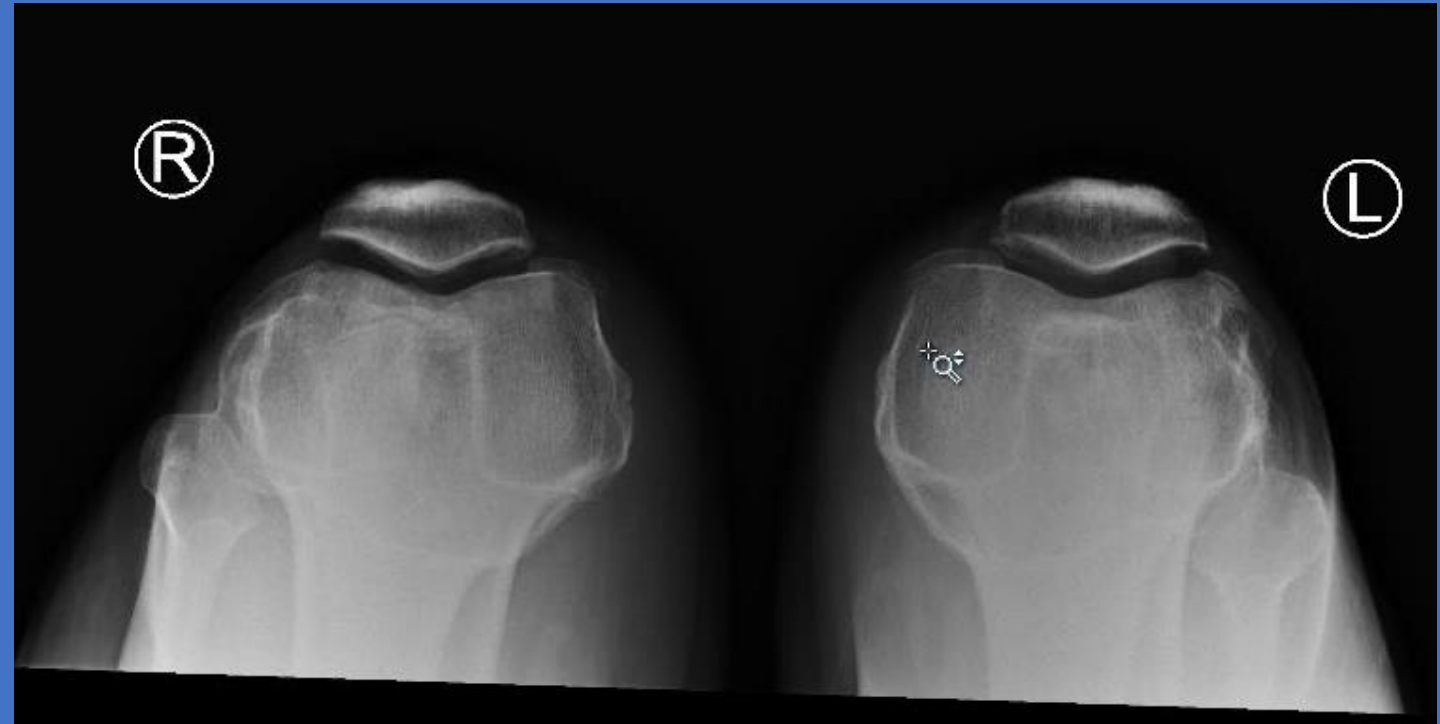Age/Gender:

- 42 year old male

Hx Presentation:

- 4 yr history of right knee injury while playing basketball
- Had a knee arthroscopy with partial medial meniscectomy
- Several rounds of physical therapy and viscosupplementation
- No improvement

Pre-Images



Case #6

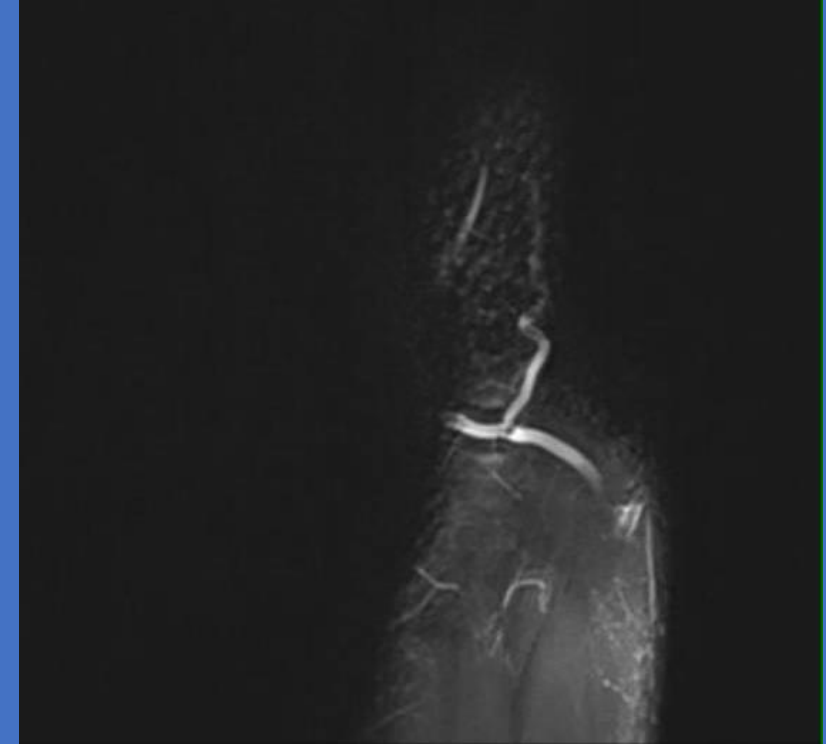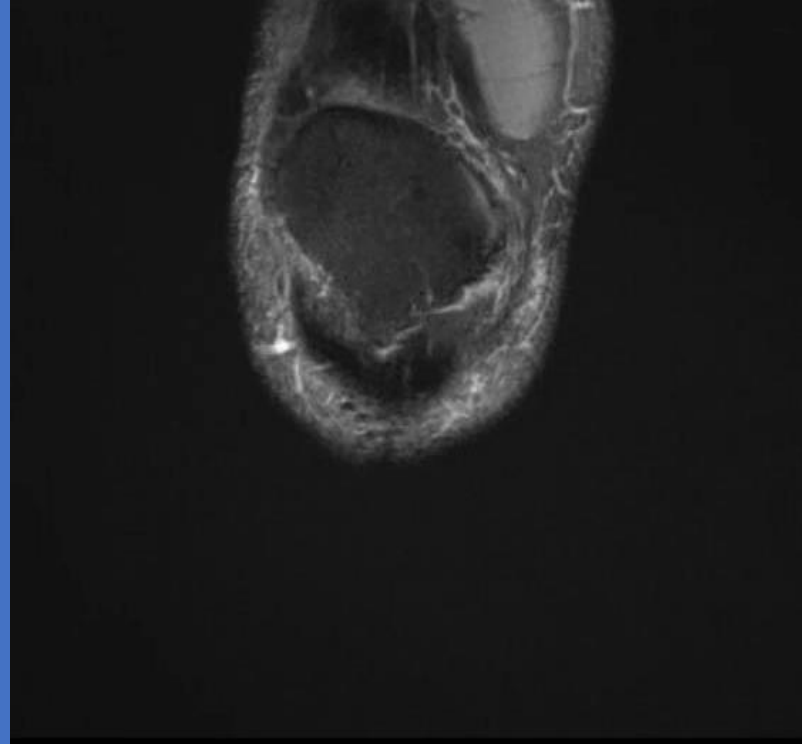Patient Demographics

Exam:

No effusion

- Full range of motion
- No ligamentous instability
- +1PF crepitus
- +MJLT
- No LJLT

Pre-Images



Case #6

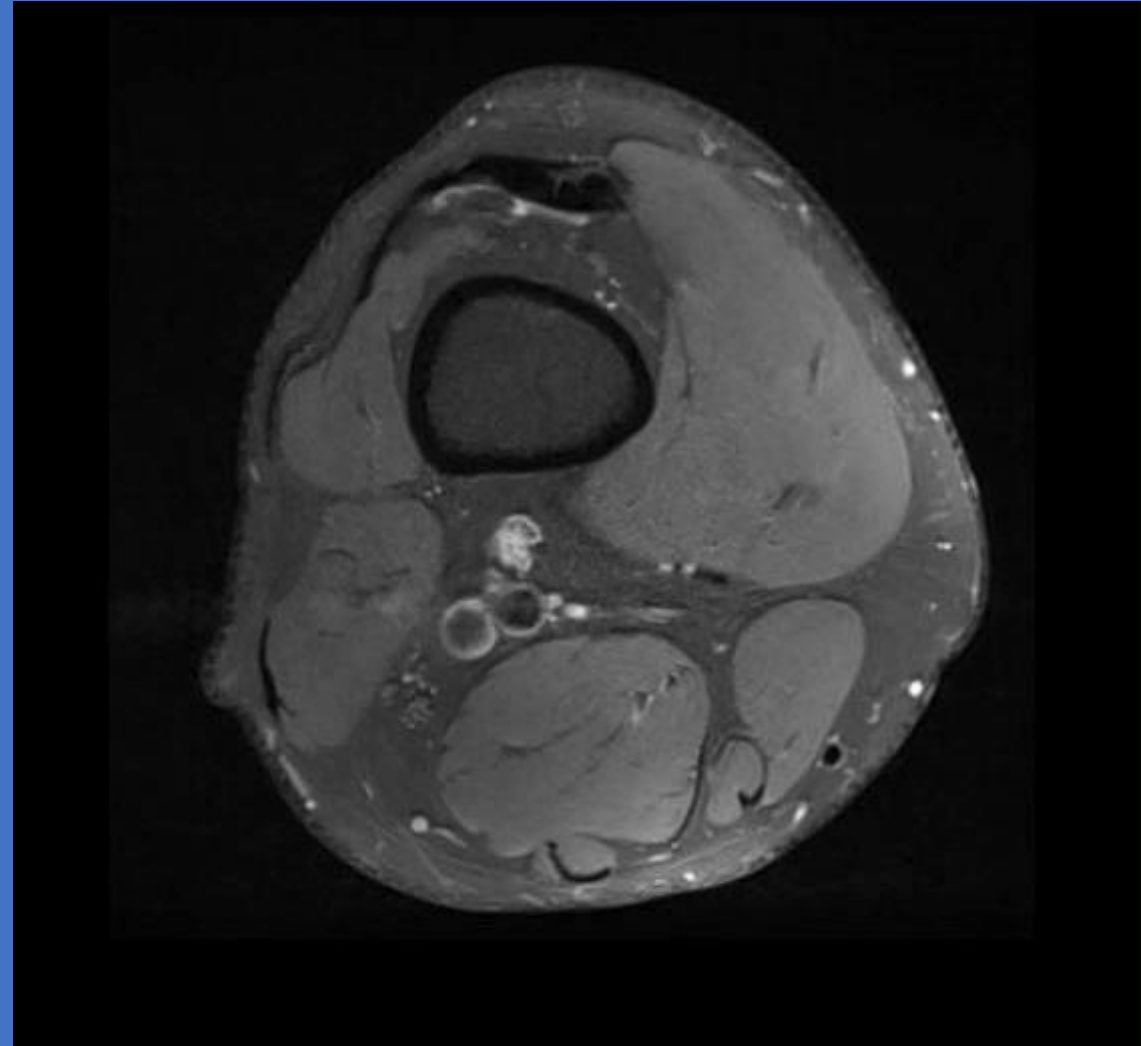
Patient Demographics

Exam:

No effusion

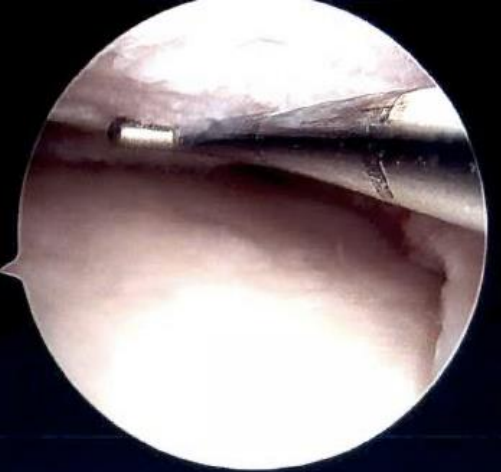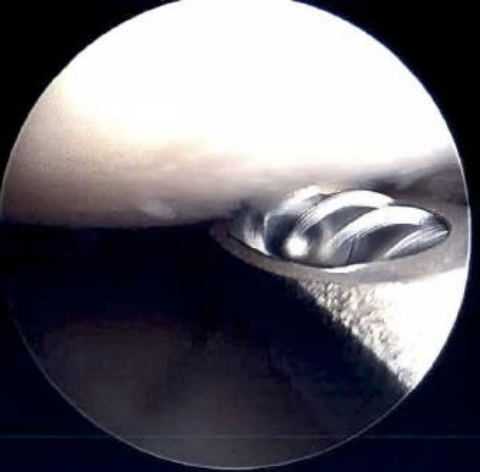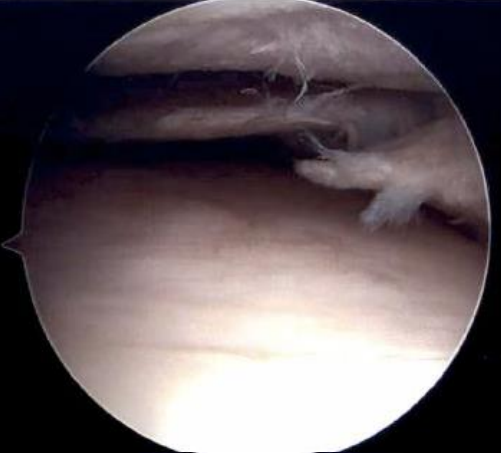
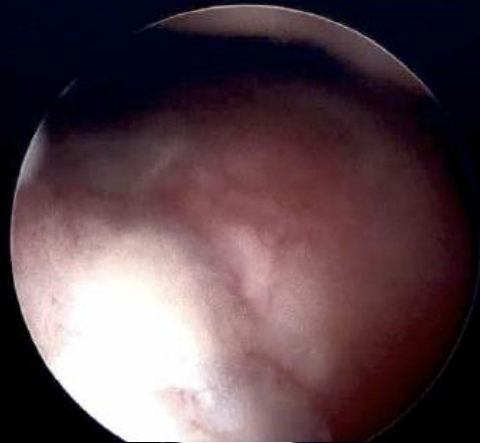
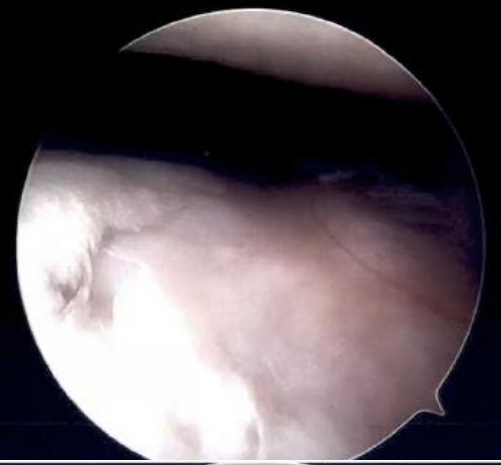
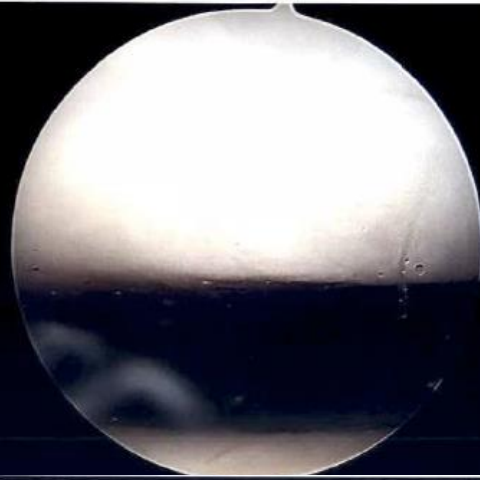
- Full range of motion
- No ligamentous instability
- +1PF crepitus
- +MJLT
- No LJLT

Pre-Images



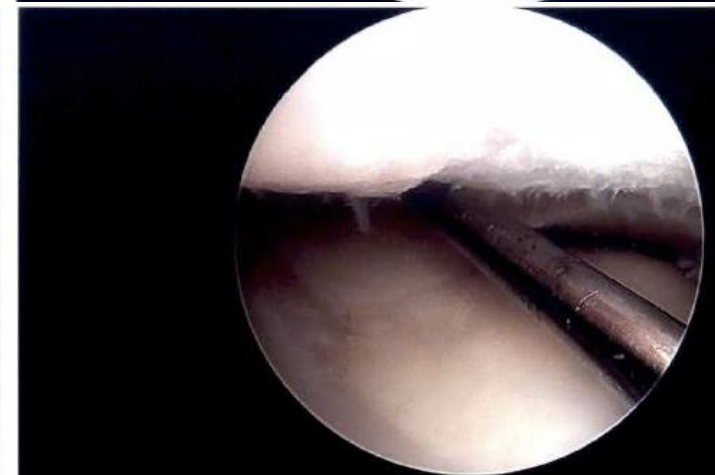
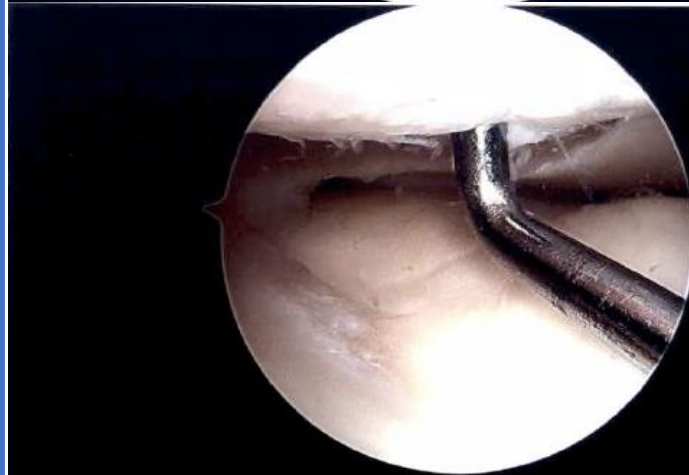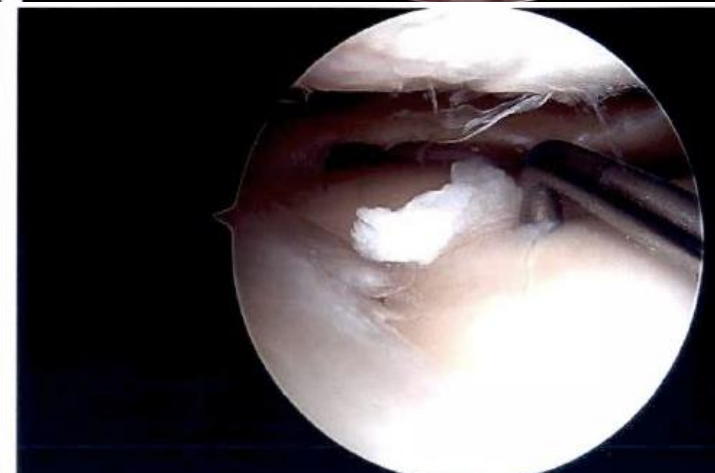
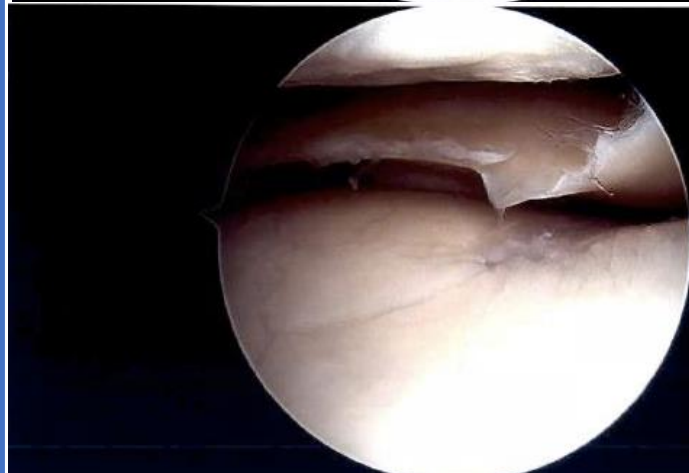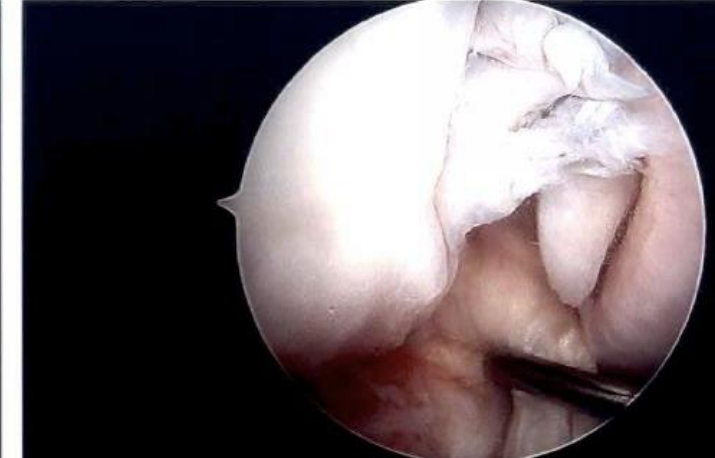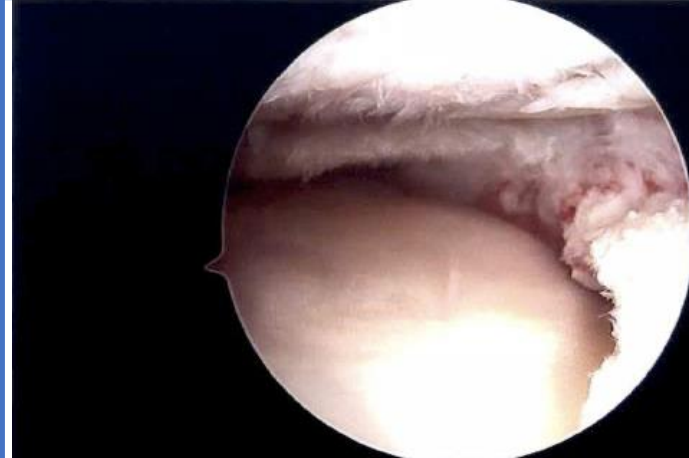Treatment

- Diagnostic Arthroscopy



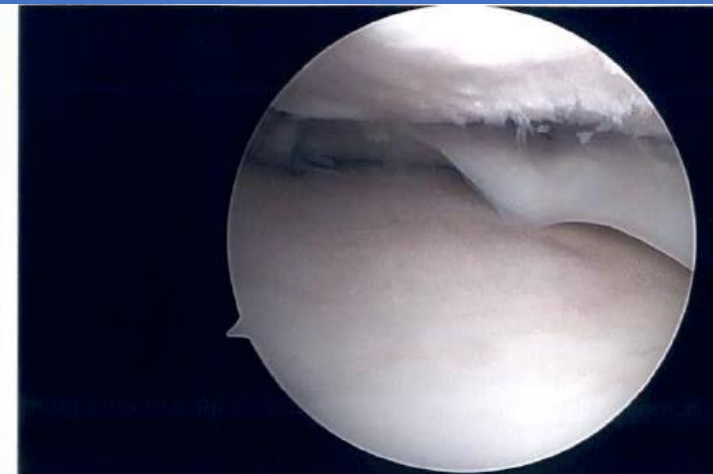
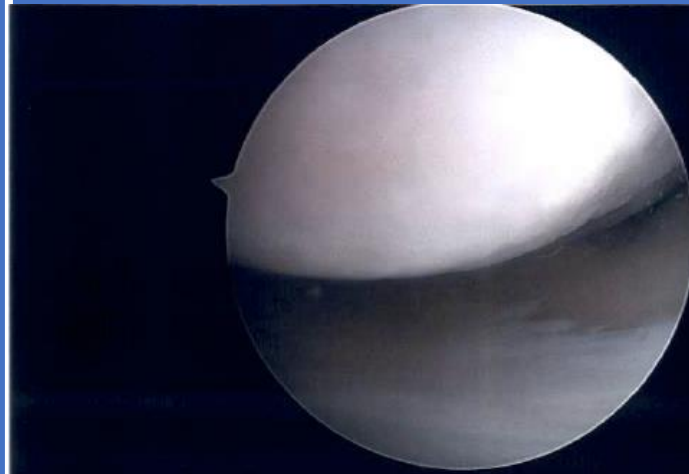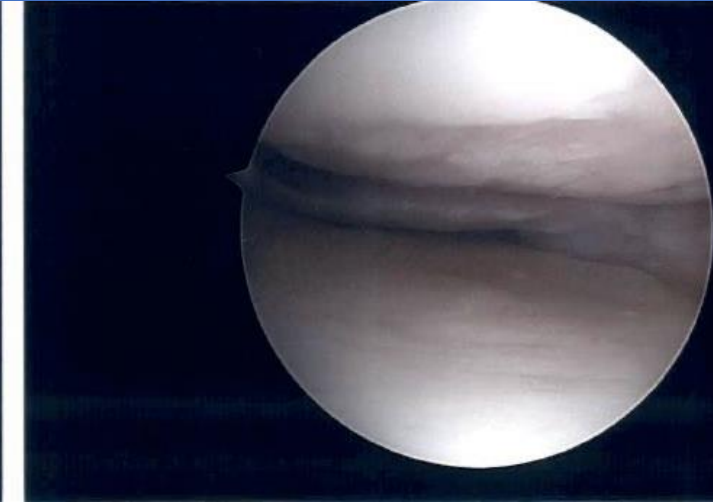
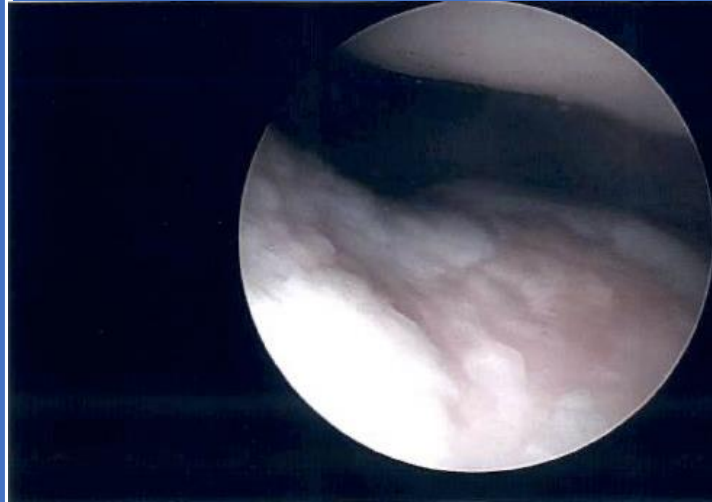
Treatment

- Diagnostic Arthroscopy
- Post operatively
 - Acute pain improvement
 - Still unable to return to volleyball
 - Elected to proceed with cartilage restoration
 - 6mo between biopsy and implant



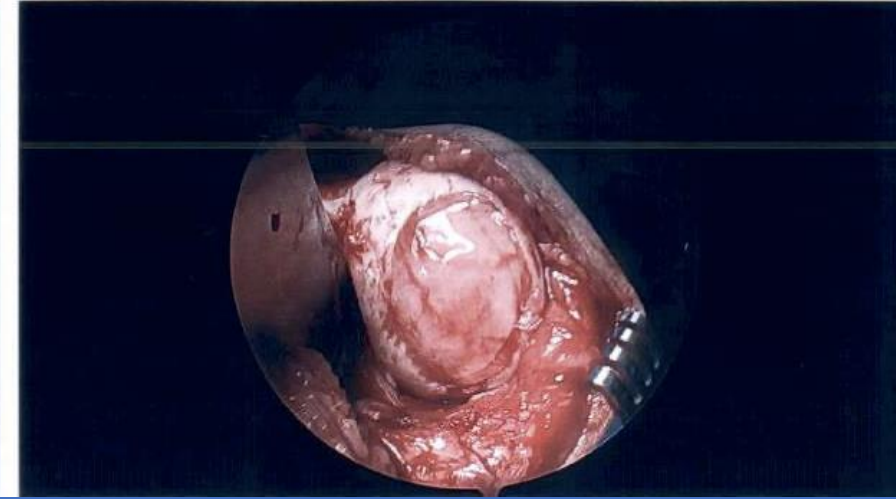
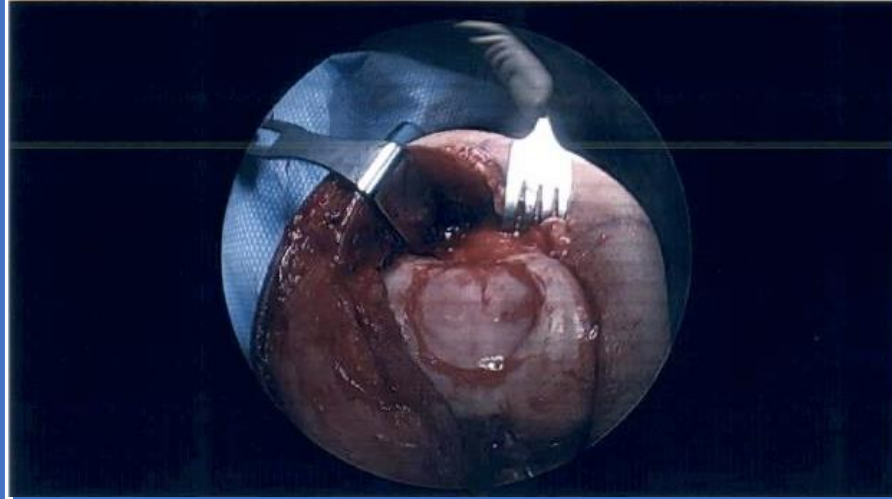
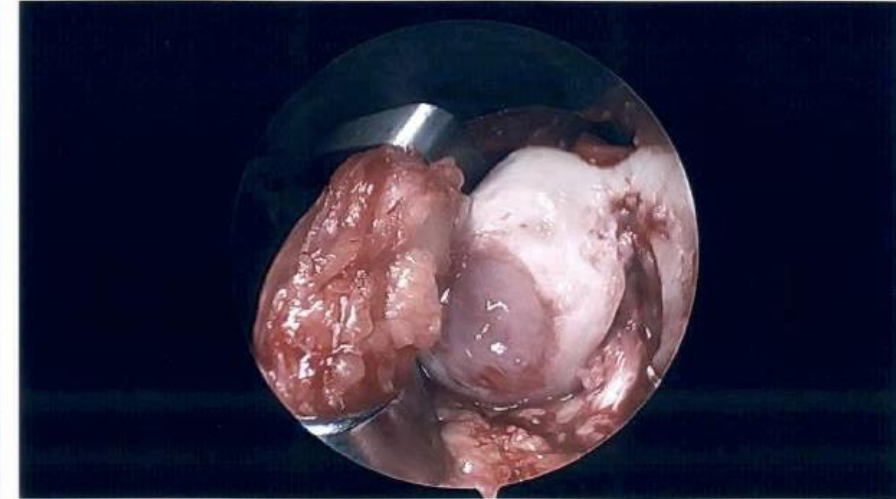
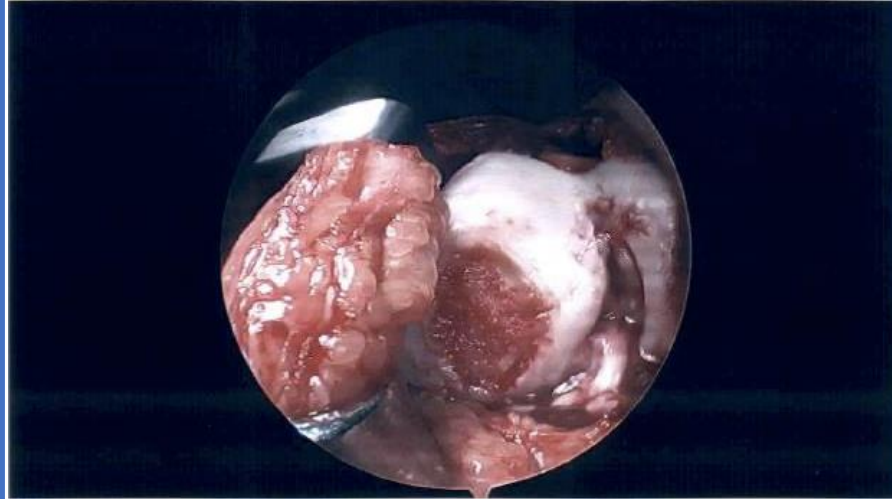
Treatment

- MACI Implant MFC, LFC, Trochlea
- Medial Meniscal Transplant



Treatment

- MACI Implant MFC, LFC, Trochlea
- Medial Meniscal Transplant



Rehab

- NWB
- 0-20° 2 weeks
- 0-90° 6 weeks
- BFR

- Progressive WB at 6 weeks to WBAT

- Had full motion at 5 months

- All pre-operative pain resolved

- Beach volleyball at 1 year mark

