

Common Pitfalls – Hand Tips & Tricks

Pre-op, Intra-op, and Post-op



Amy L. Ladd MD
Neil Harness MD
Nicole Schroeder MD
Robert Slater MD

COA Annual Meeting 2021

Ladd Disclosures

- None pertinent to this talk

Objectives

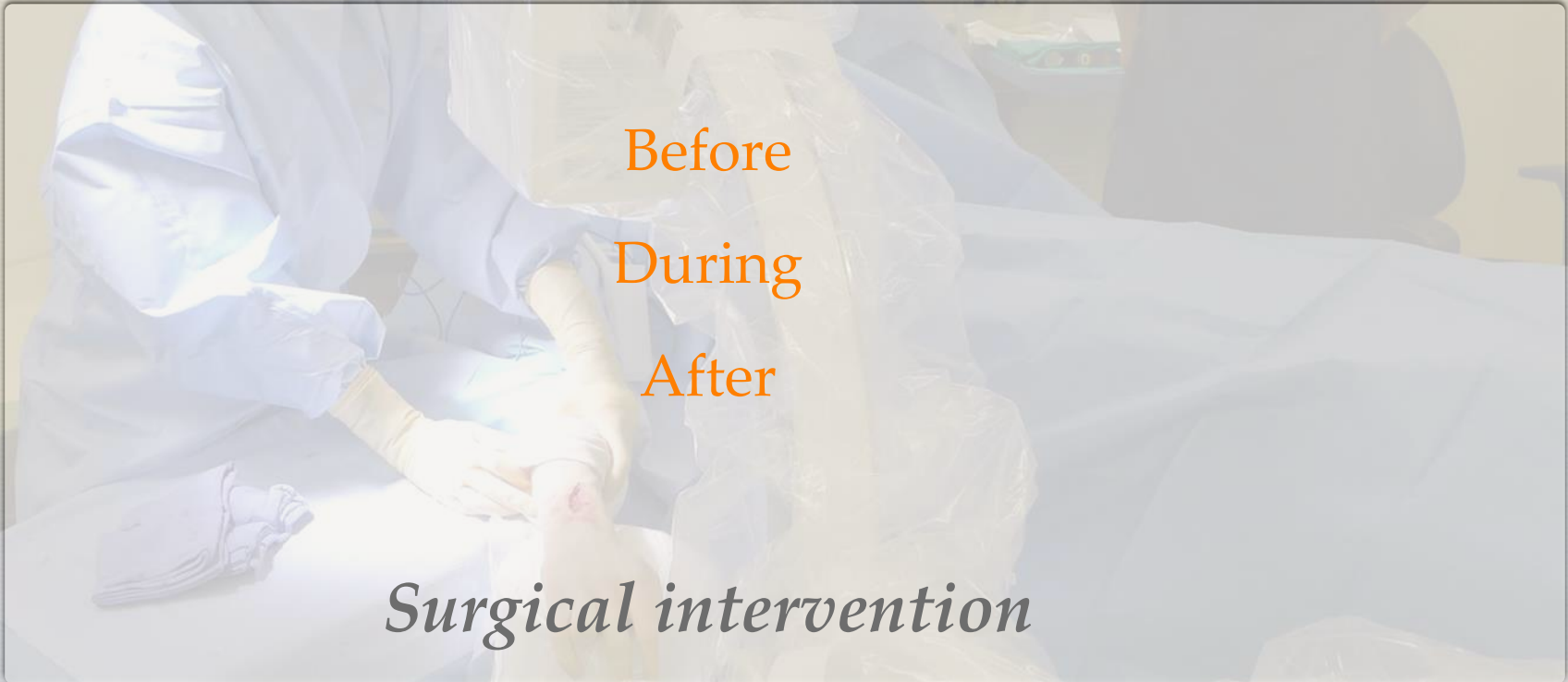Offer pearls and pitfalls of common hand problems

Before

During


After

Surgical intervention



Common hand conditions

- Carpal tunnel syndrome – Neil Harness MD
- Trigger finger – Nicole Schroeder MD
- Distal Radius Fracture – Robert Slater MD
- Potpourri - Amy Ladd MD

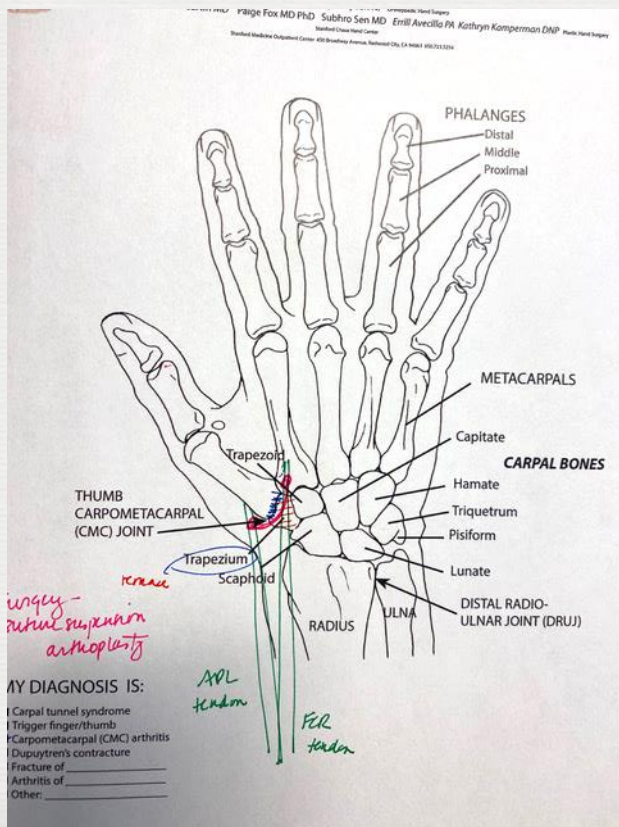


-Ladd-

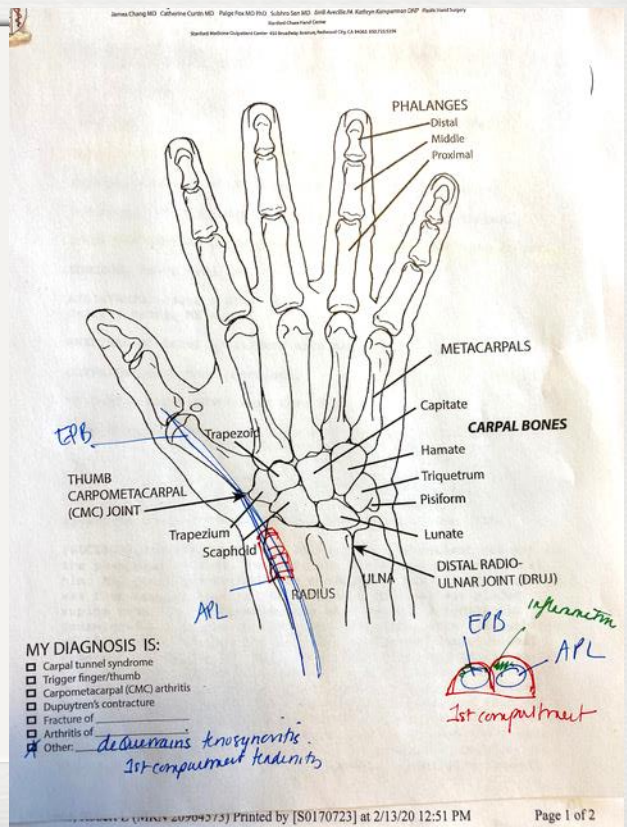
PRE-OPERATIVE *Pearl*



"Coloring Book" page



Draw procedure for patient



-Ladd-

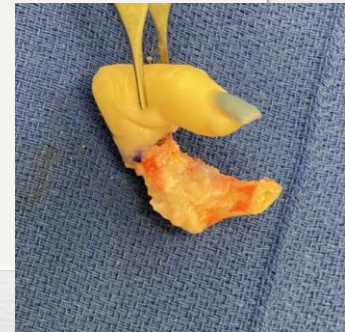
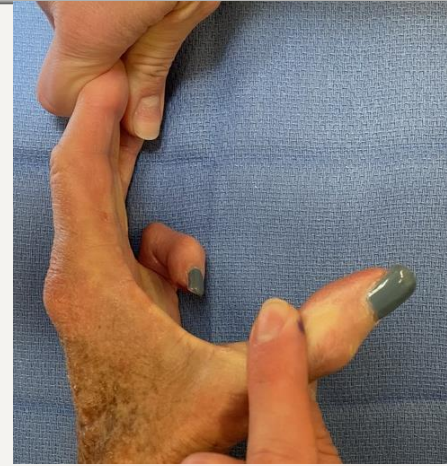
PRE-OPERATIVE *Pitfall*



Not reviewing notes before complex procedures

Examples

- Multiple fingers, locations, complex Dupuytren's
- Multiple arthroplasties for RA
- Tendon transfers + botox for CP
- Mix and match
 - *PIP mass, swanneck & snapping lateral band, fixed DIP contracture, Dupuytren's*



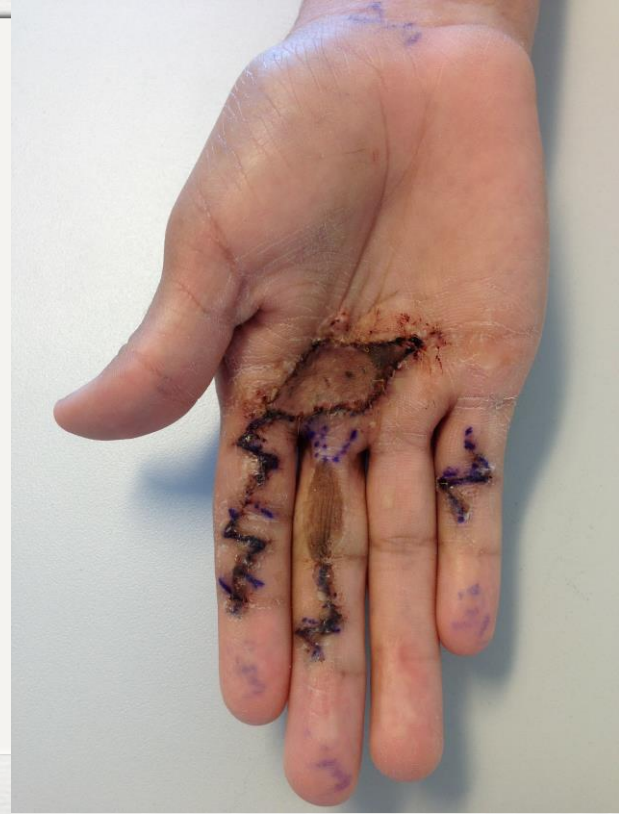-Ladd-

INTRA-OPERATIVE *Pearl*



Wound closure

- **Absorbable sutures and glue (Dermabond or generic)**
 - Small, volar wounds: 5-0 plain gut mattress sutures
 - Kids and nailbeds: 6-0 chromic
 - Dorsal wounds: 4-0 Monocryl



-Ladd-

INTRA-OPERATIVE *Pitfall*



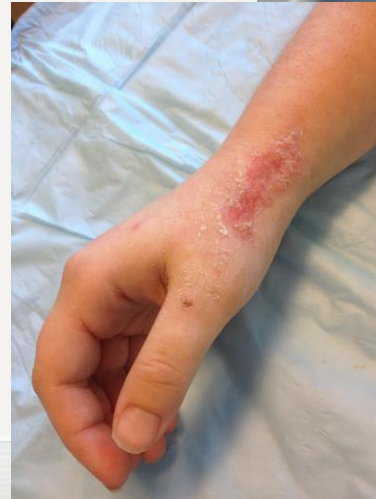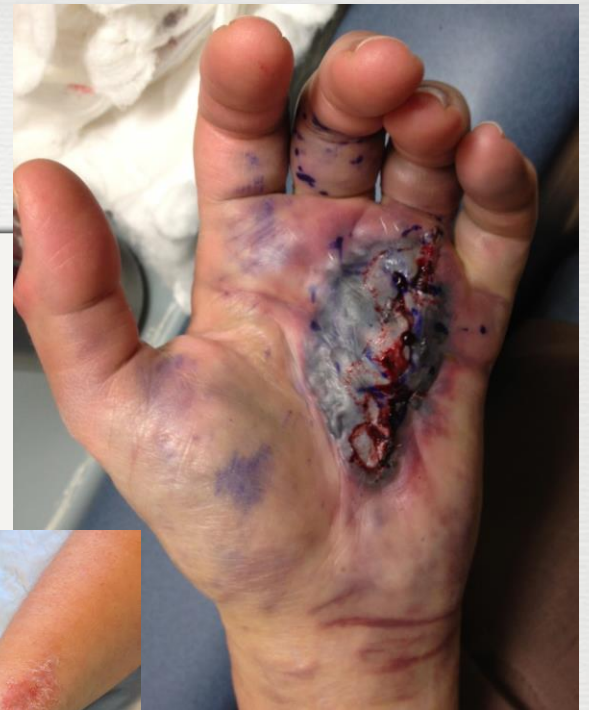Wound closure

- When **NOT** to use absorbable sutures

- Macerated or thin skin (mucous cyst)
- Known allergy

- When **NOT** to glue

- Patients on blood thinners, esp. Plavix
- Known allergy
- Questionable infection or tumor



-Ladd-

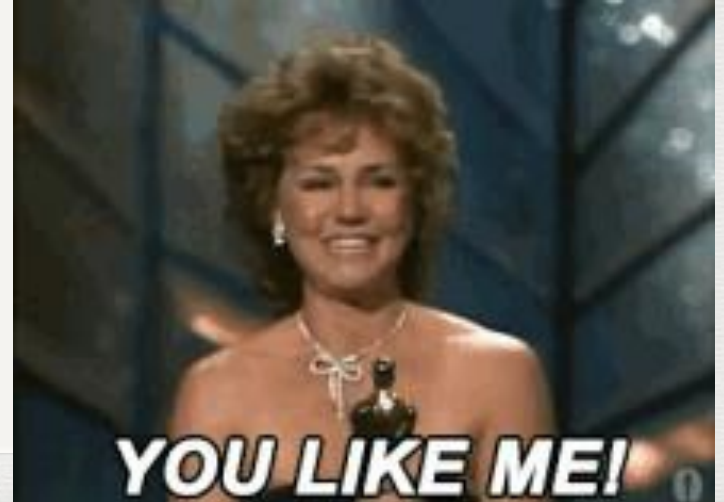POST-OPERATIVE *Pearl*



Next day phone call

- **Call to patient specifically**

- Different than recovery room and family member call
 - *(they never remember)*
- Catch pain or block issues early
- Genuine gratitude



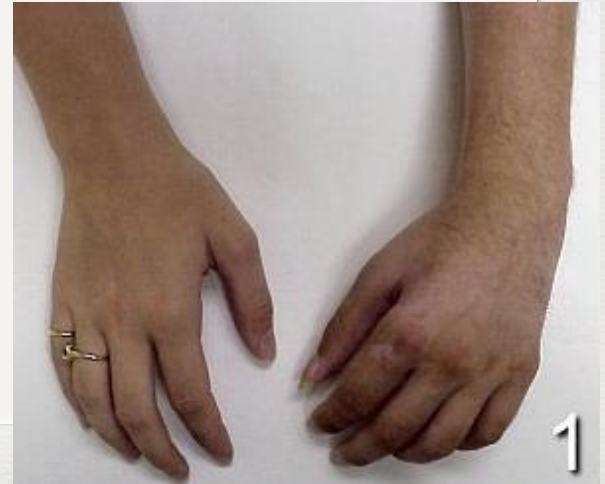-Ladd-

POST-OPERATIVE *Pitfall*



Not seeing certain patients early and personally

- **One week** (*compare 10-14 days with APP*)
 - Dupuytren's – wound and stiffness, CRPS
 - RA and OA multiple joints – alignment, motion
 - Flexor tendons



Thank you

