

# Tips and Tricks:

## Hip and Knee Arthroplasty - CASES



**STANFORD**  
HOSPITAL & CLINICS

*Stanford University Medical Center*



Department of  
Orthopaedic Surgery

**UCDAVIS**  
**HEALTH SYSTEM**

**Derek F. Amanatullah, M.D., Ph.D.**

Assistant Professor

Orthopaedic Surgery

Email: [dfa@stanford.edu](mailto:dfa@stanford.edu)

Website: [DrAmanatullah.com](http://DrAmanatullah.com)

Twitter: [@DrAmanatullah](https://twitter.com/DrAmanatullah)

**Erik N. Hansen, M.D.**

Associate Professor

Orthopaedic Surgery

Email: [erik.hansen@ucsf.edu](mailto:erik.hansen@ucsf.edu)

**Gavin C.T. Pereira, M.B.B.S.**

Assistant Professor

Orthopaedic Surgery

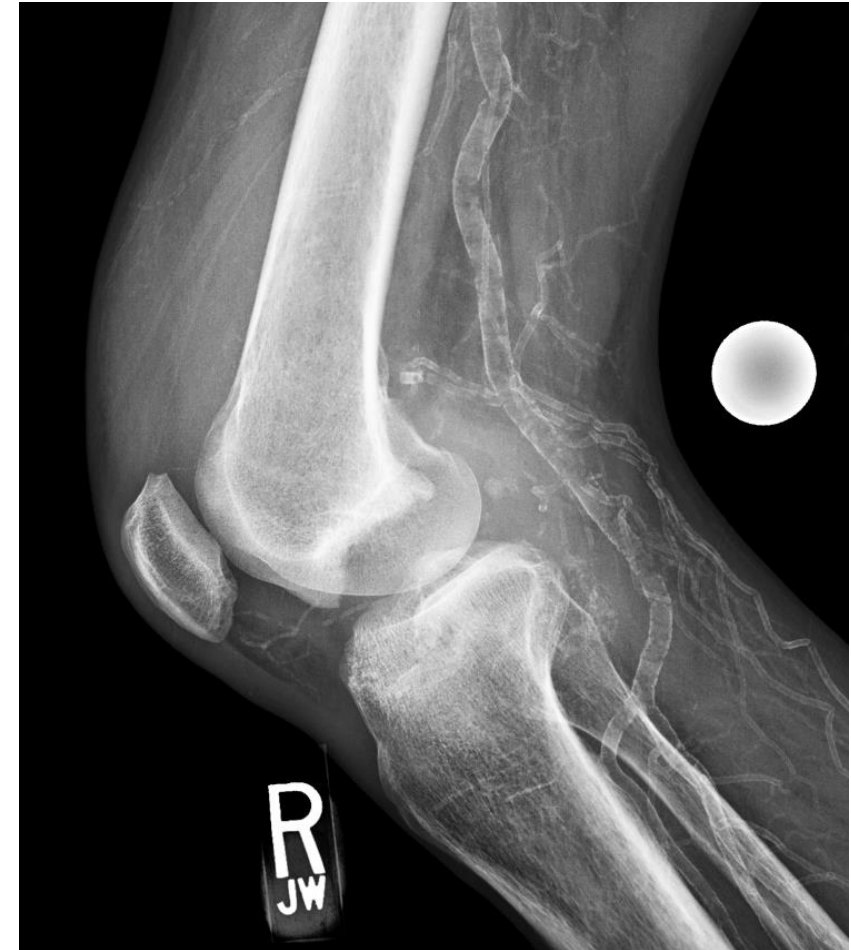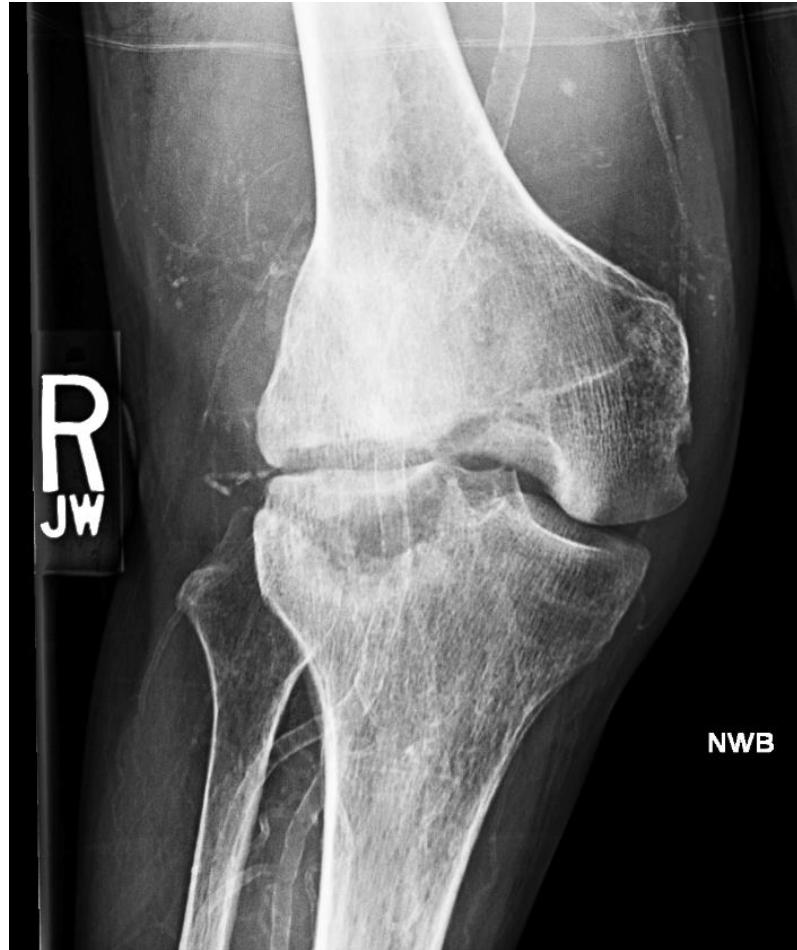Email: [gcpereira@ucdavis.edu](mailto:gcpereira@ucdavis.edu)

# Case 1: Total Knee Arthroplasty

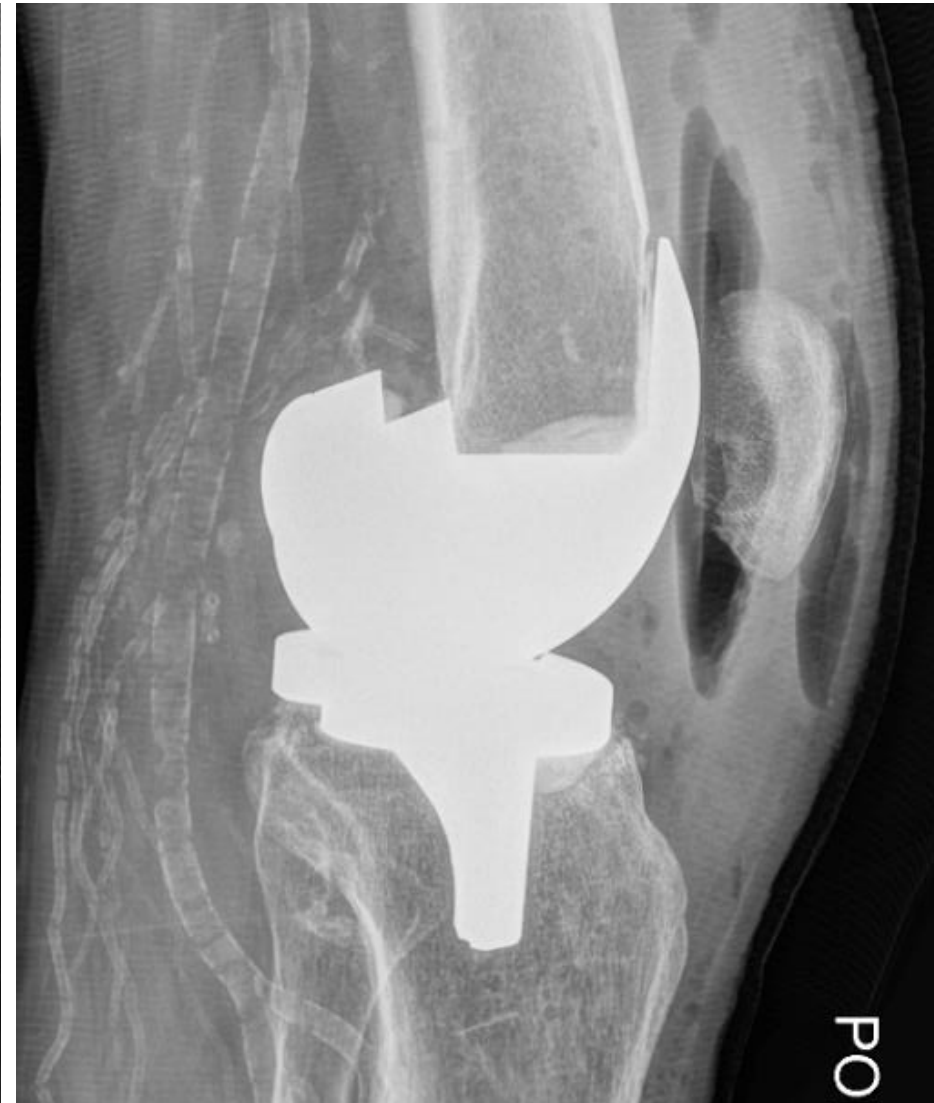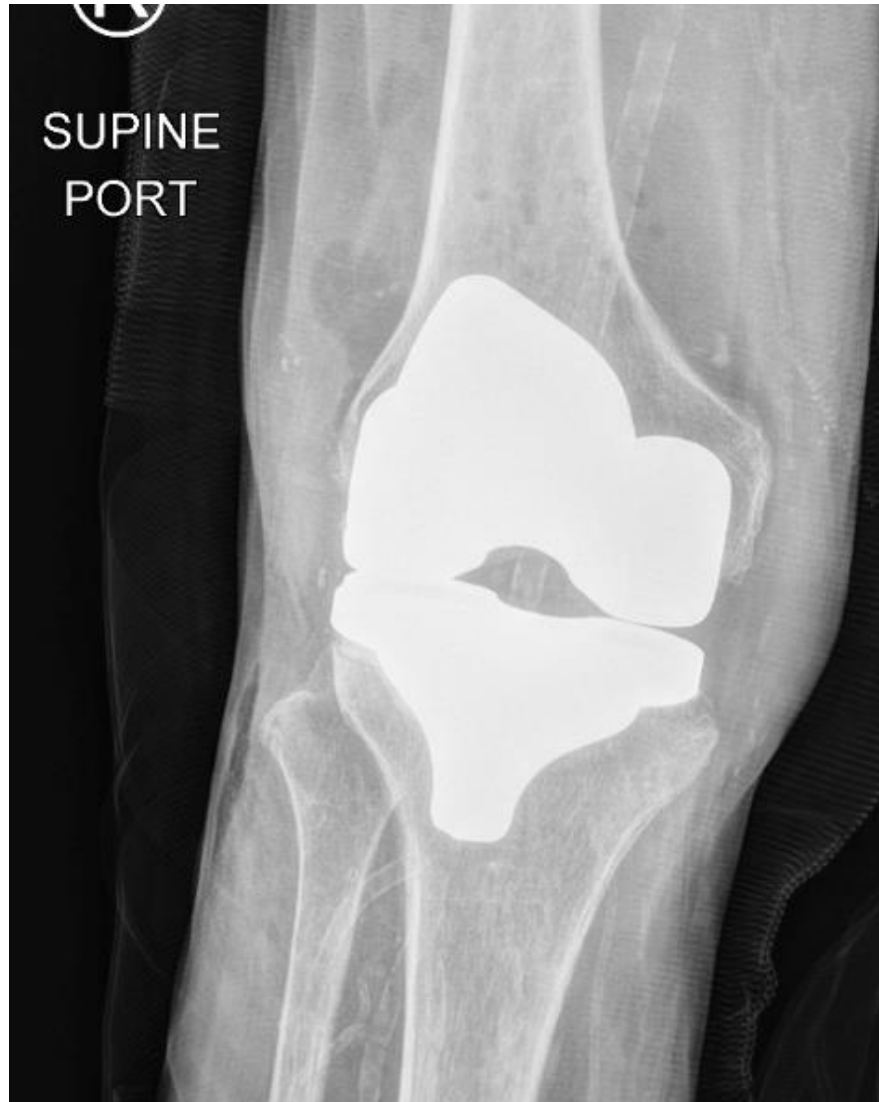45 Year Old, Male  
Post Fall  
Wheelchair Bound  
Using Brace  
Unstable

PMH: Vasculopathy  
BMI: 17.5 kg/m<sup>2</sup>

Albumin: 4.0 g/L  
ESR: 21 mm/h  
CRP: <0.8 mg/dL



# Case 1: Total Knee Arthroplasty

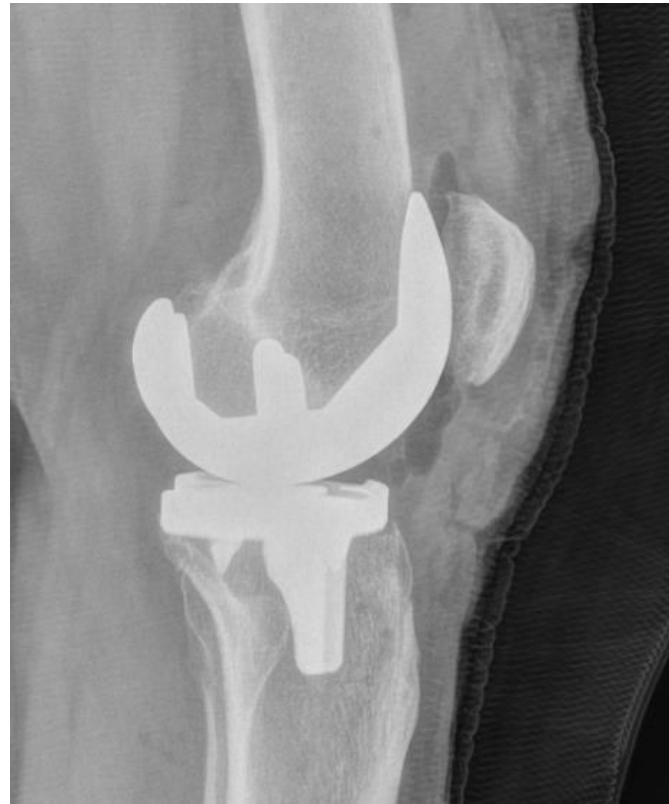

# Case 2: Total Knee Arthroplasty

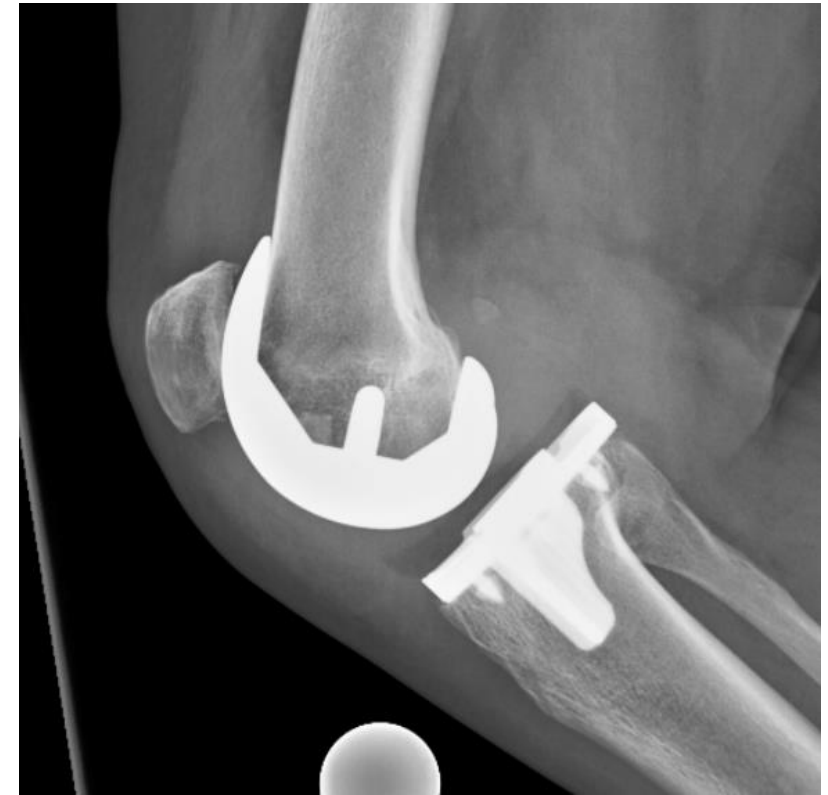59 Year Old, Female  
No known fall  
Now using walker

PMH: None  
BMI: 24.6 kg/m<sup>2</sup>

ESR: 36 mm/h  
CRP: <0.8 mg/dL



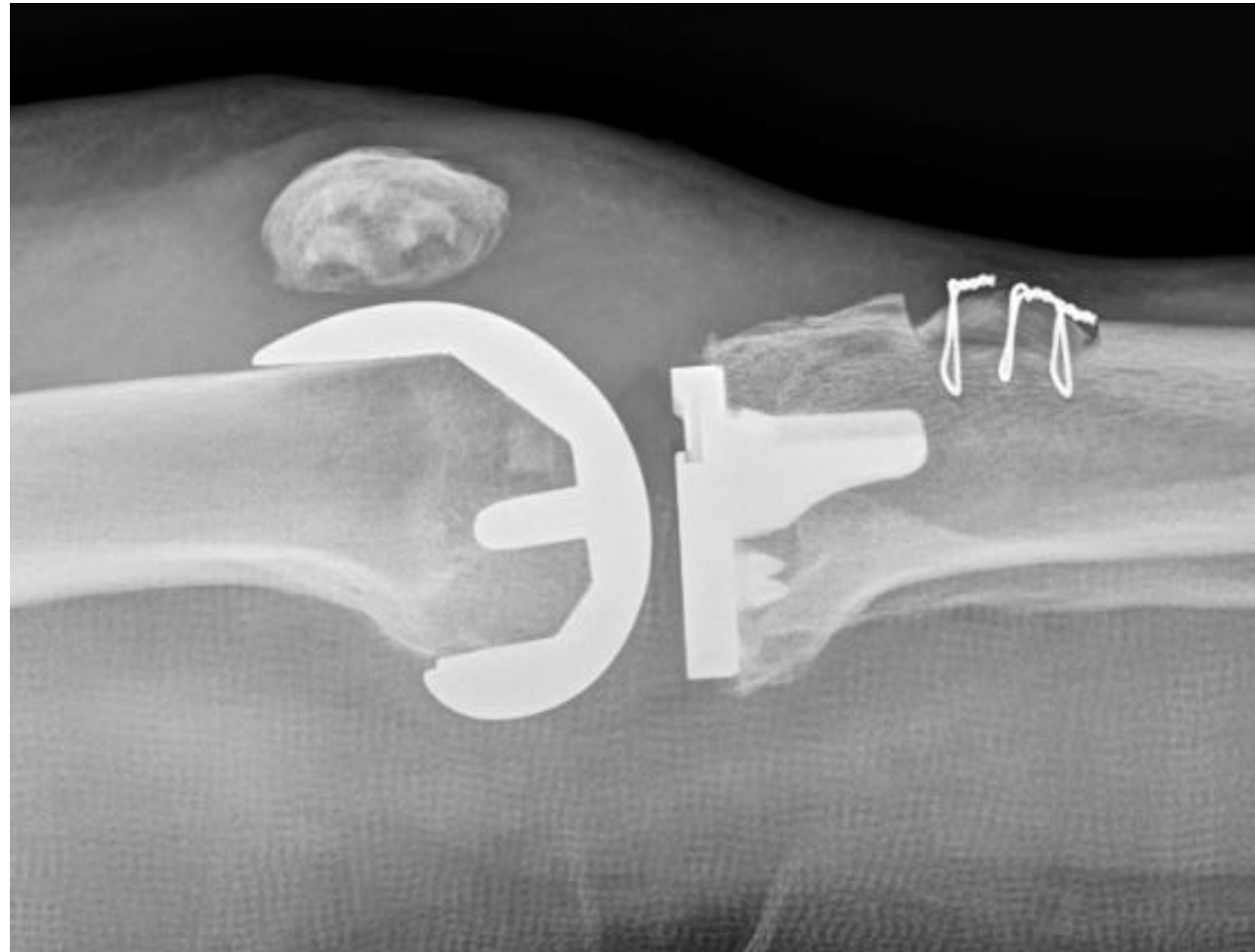POD #0



POD# 14



# Case 2: Total Knee Arthroplasty



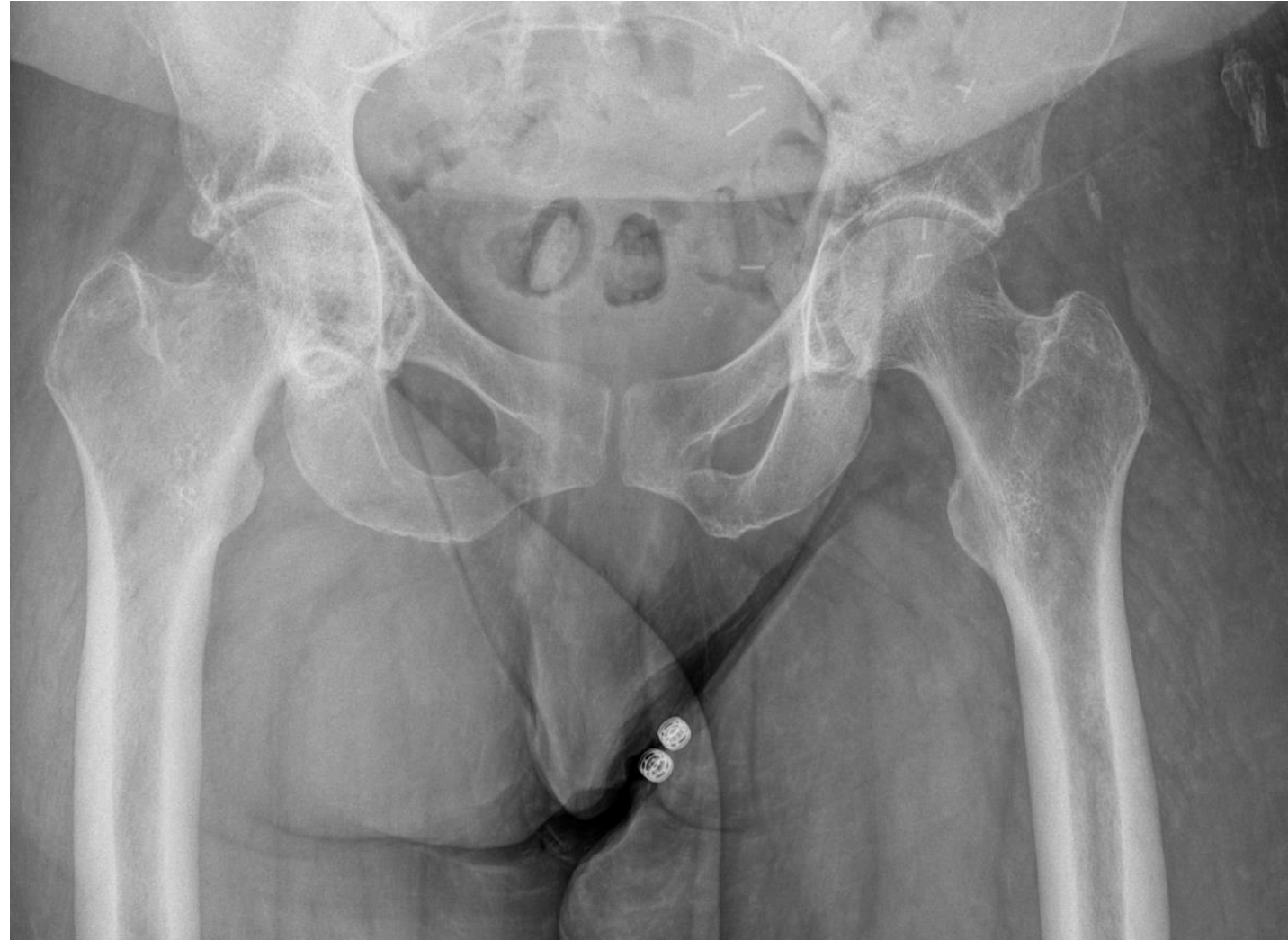# Case 1: Total Hip Arthroplasty

51 Year Old, Female  
Groin pain for decades  
Complex radiating pain  
Wheelchair bound  
No Relief with NSAIDs  
Negative Rhuem workup

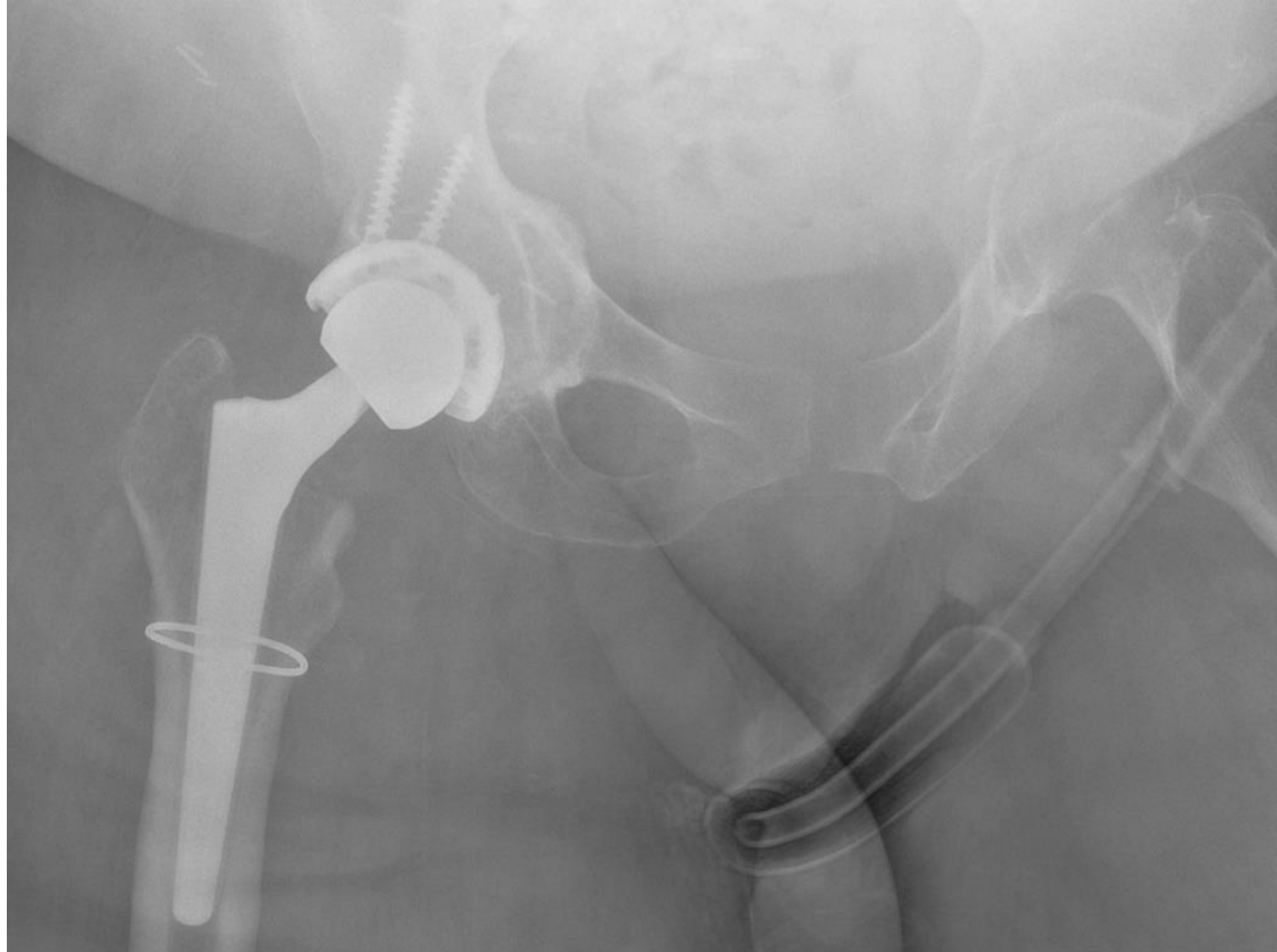
PMH: PVD  
PSH: Left Illiofemoral Bypass  
BMI: 42.5 kg/m<sup>2</sup>

Albumin: 4.2 g/L  
ESR: 32 mm/h  
CRP: <0.8 mg/dL

100% relief of groin pain  
and ambulatory after  
guided hip injection



# Case 2: Total Hip Arthroplasty



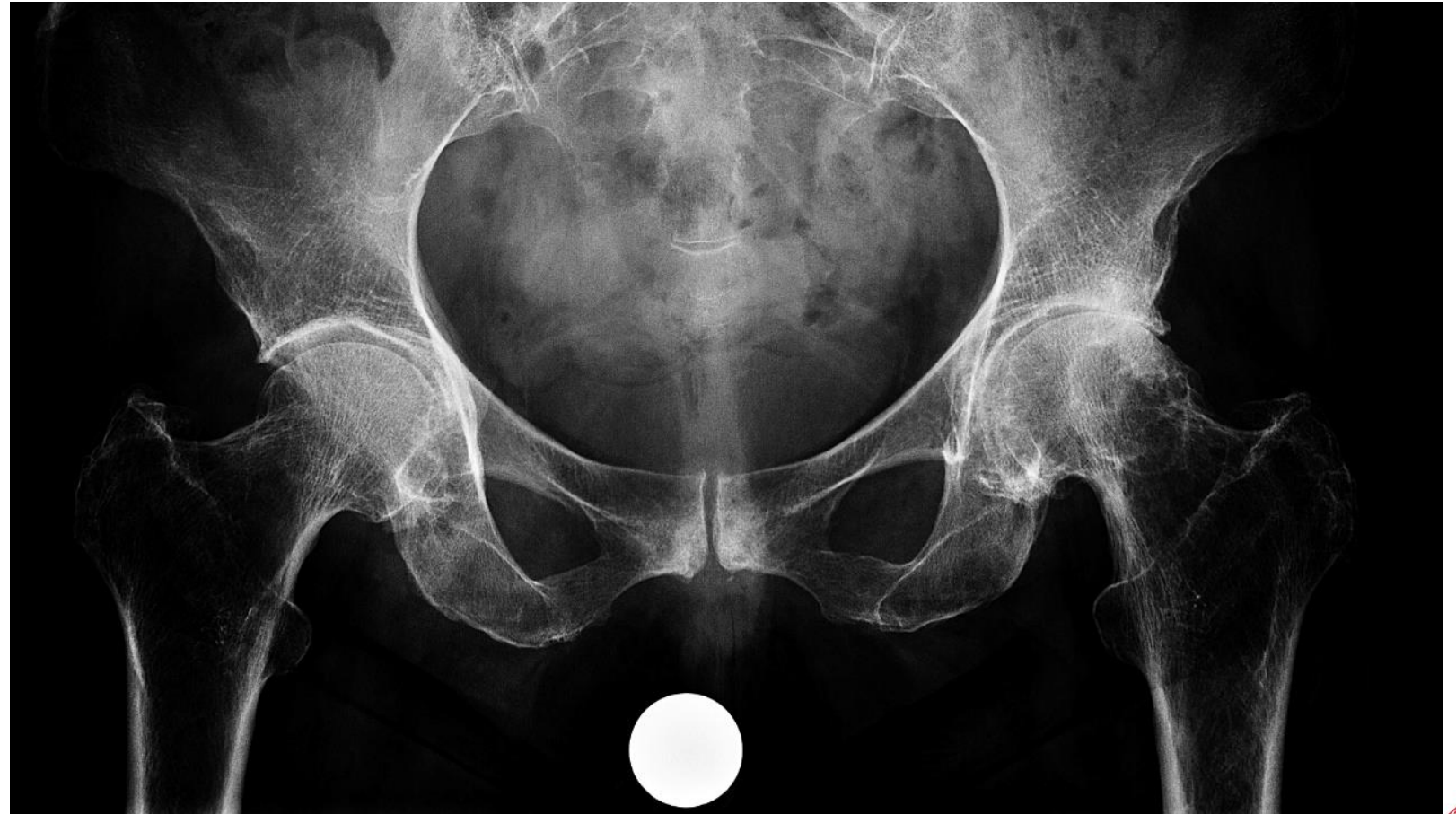
# Case 2: Total Hip Arthroplasty

72 Year Old, Female  
Groin pain for decades  
No radiating pain  
Ambulatory with a cane  
Relief with NSAIDs

PMH: HLP, CAD  
BMI: 22.4 kg/m<sup>2</sup>

Albumin: 3.8 g/L

80% relief of groin pain  
ultrasound guided hip  
injection





# Case 2: Total Hip Arthroplasty

