

Common Benign Bone Lesions

Carl Weinert, M.D.

Clinical Presentation

- Chief Complaint
 - Pain
 - Mechanical
 - Constant
 - Relieved by ?
 - Onset / Progression

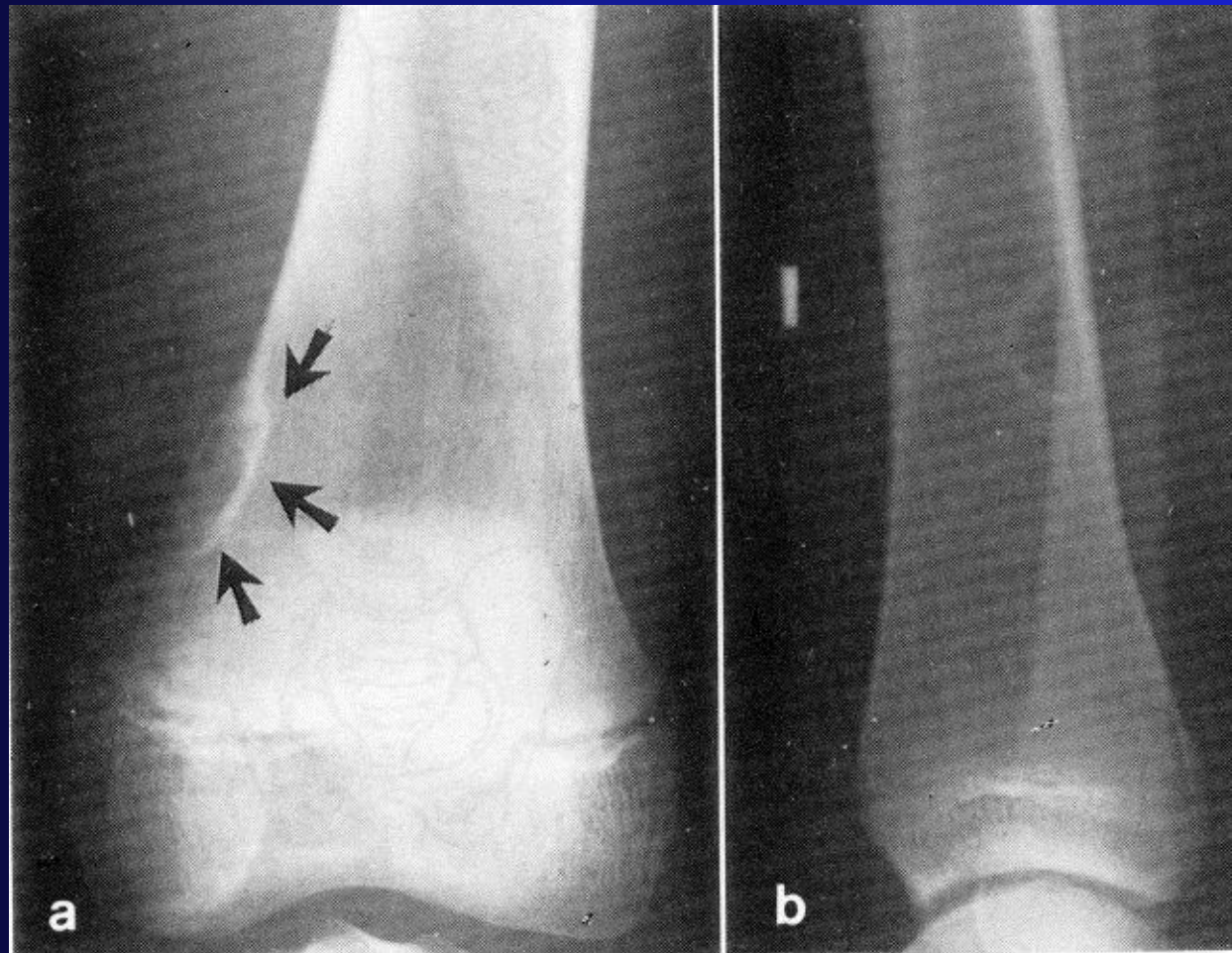
Clinical Presentation

- Chief Complaint
 - Mass
 - Size
 - Location
 - Change over time
 - Limp
 - Systemic Sx - rare even with malignancies

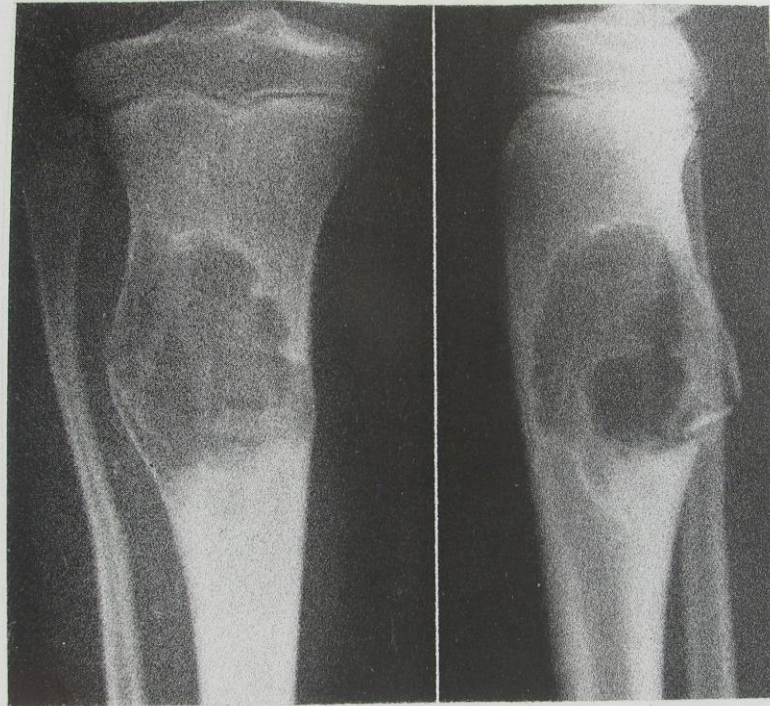
Exam

- Gait
- Atrophy
- Mass
 - Size
 - Location
 - Tenderness
 - Warmth
 - Mobility

Fibrous Cortical Defect

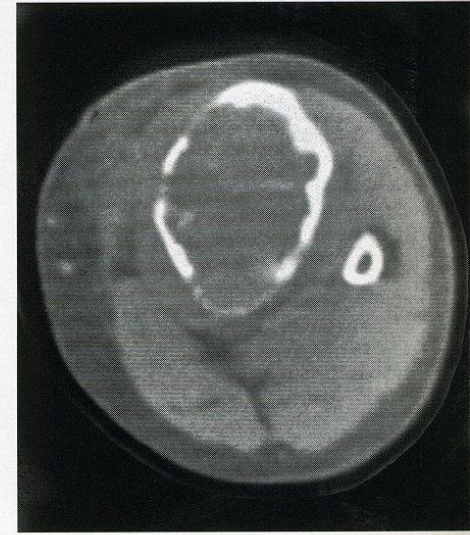
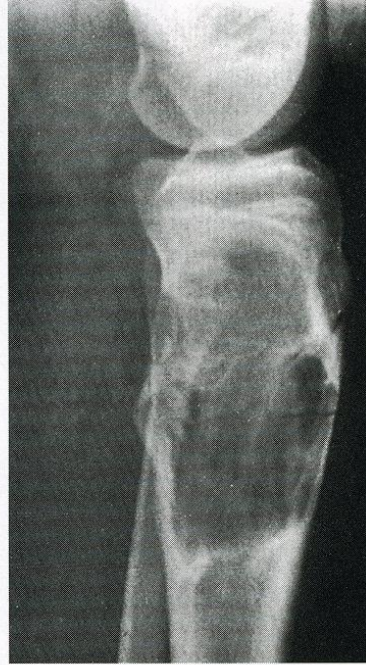
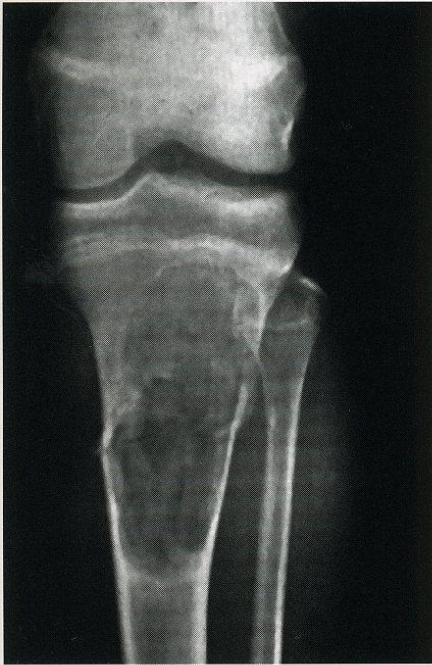
Nonossifying Fibroma

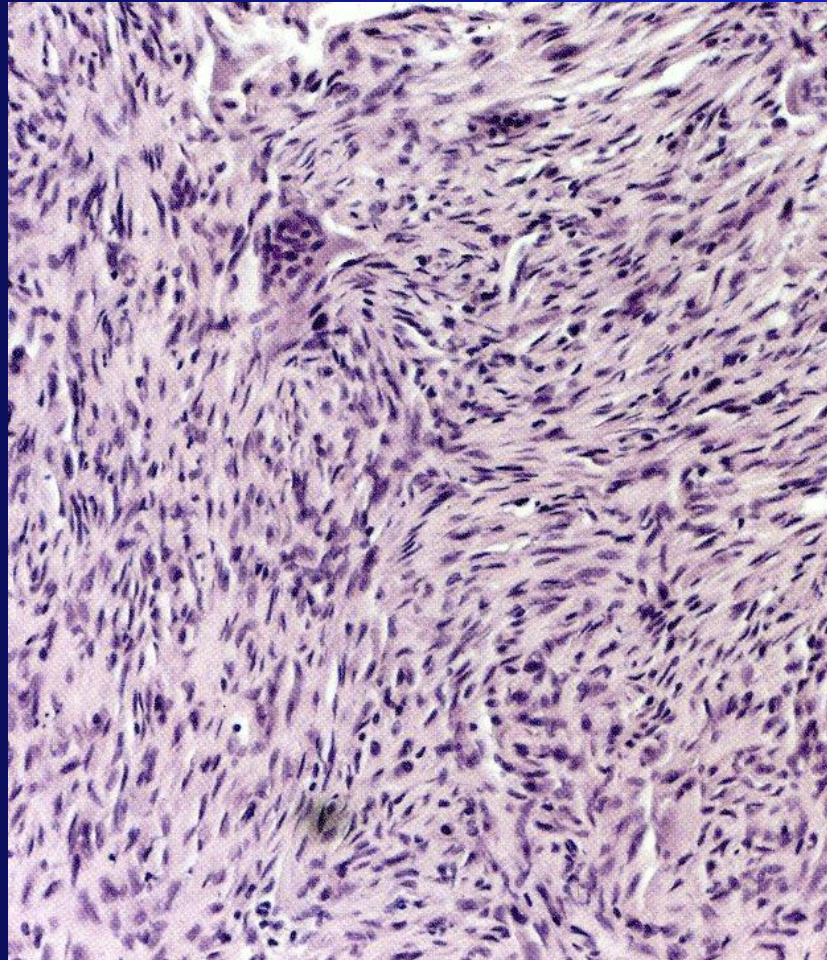


Fairly large histiocytic fibroma, in a boy aged 8 years, with pathologic fra

Nonossifying Fibroma



Nonossifying Fibroma



Osteochondroma

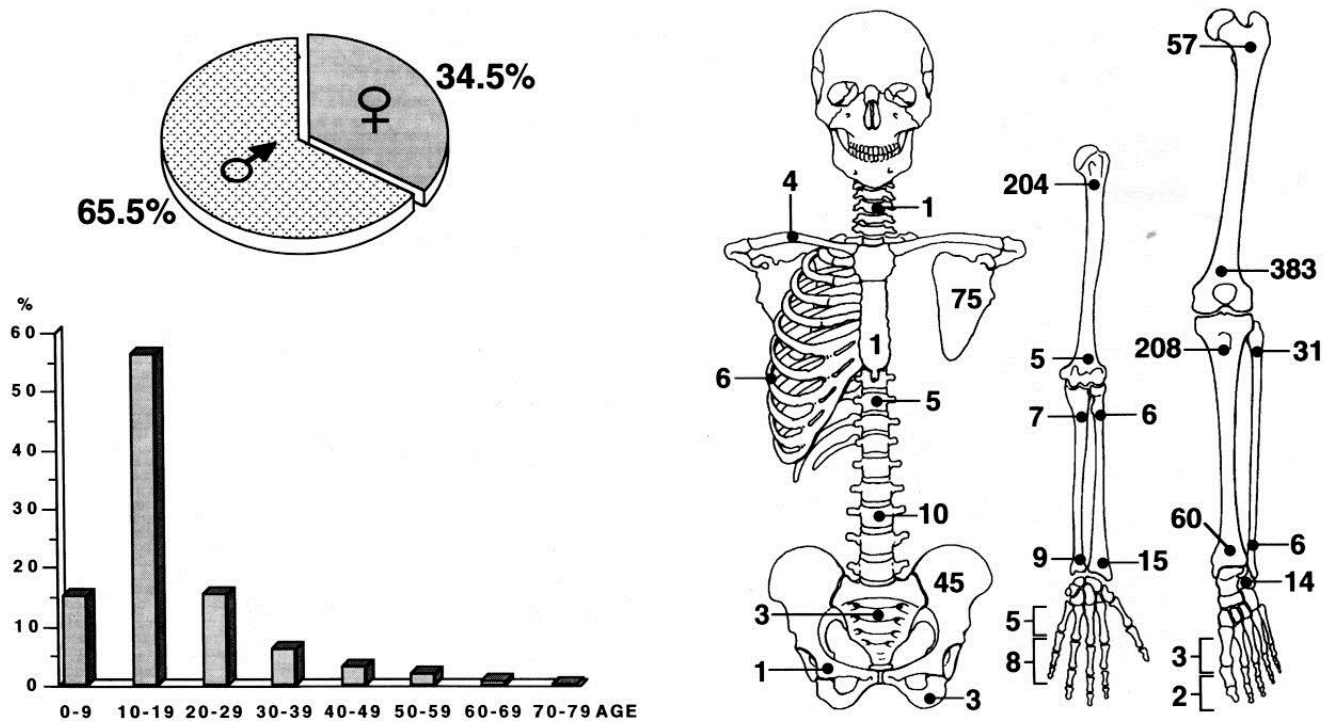
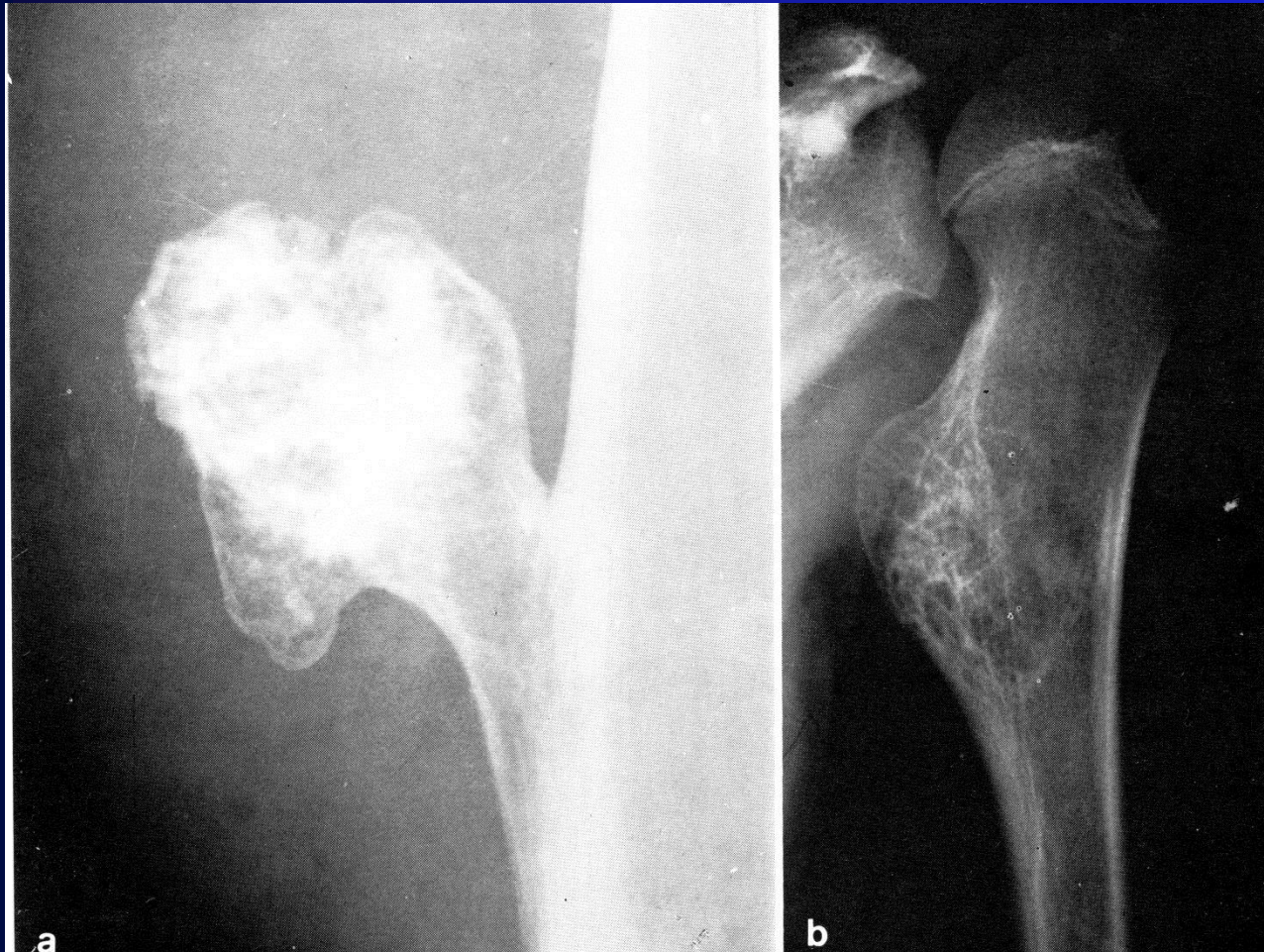
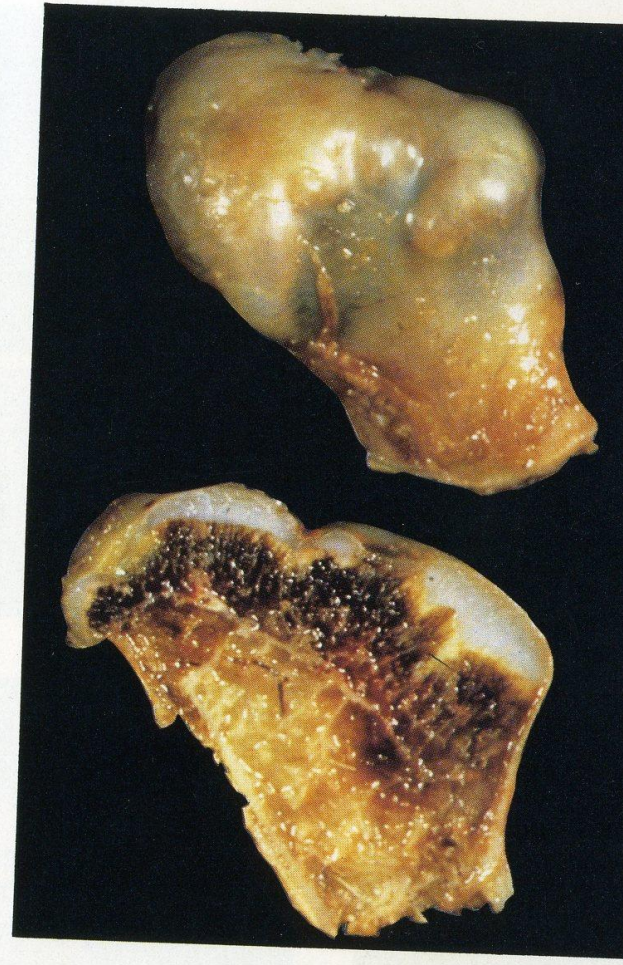
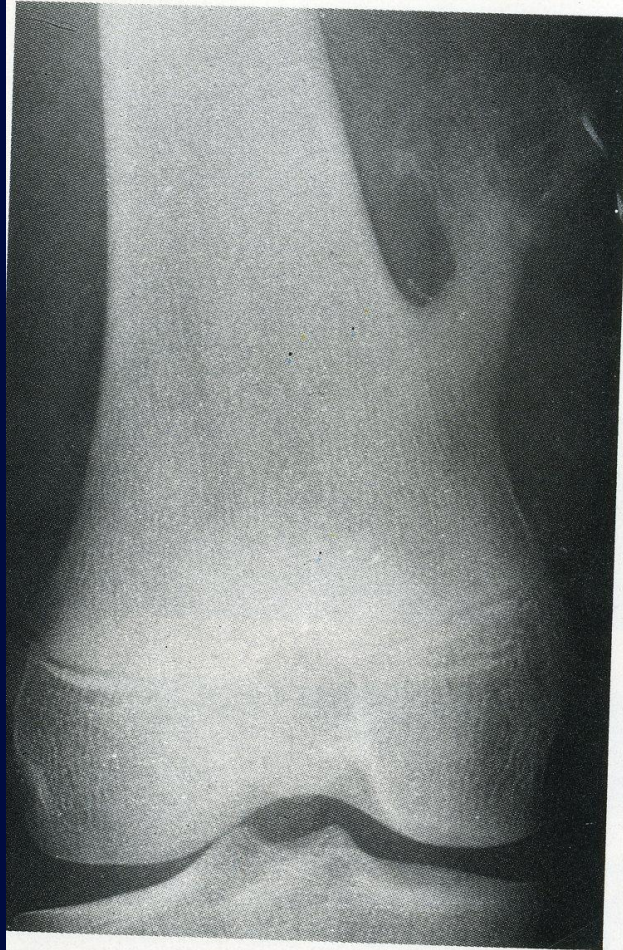
Fig. 9-1. Sex, age and localization in 1177 cases of solitary exostosis. (These are only cases submitted to surgery, and thus mainly large and/or symptomatic exostoses).

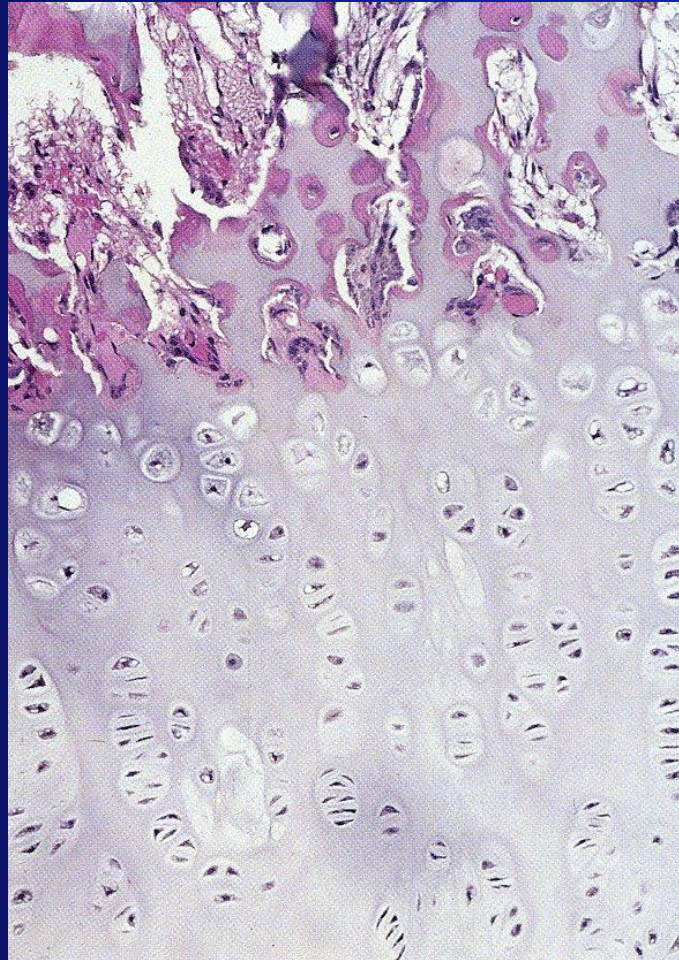
Osteochondroma



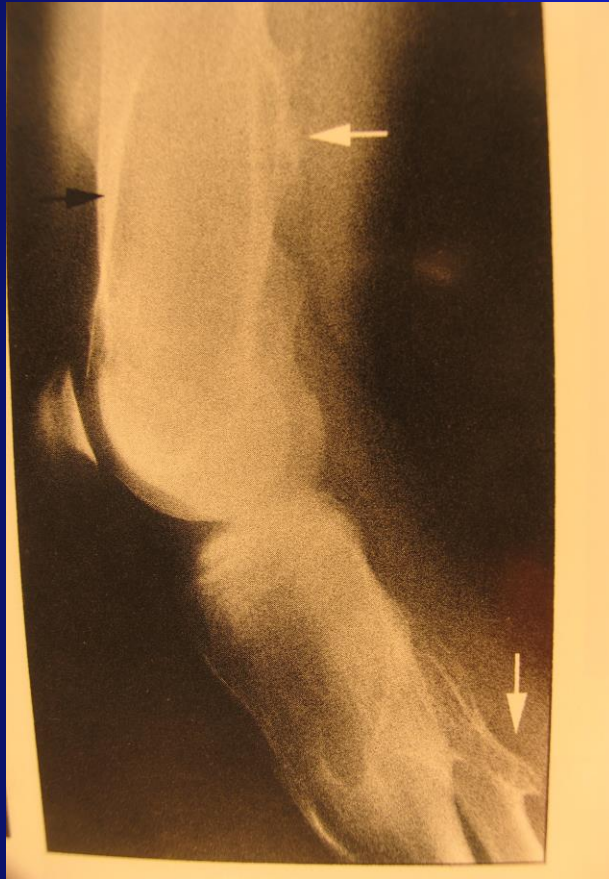Osteochondroma



Osteochondroma



Multiple Osteochondromatosis



Unicameral Bone Cyst

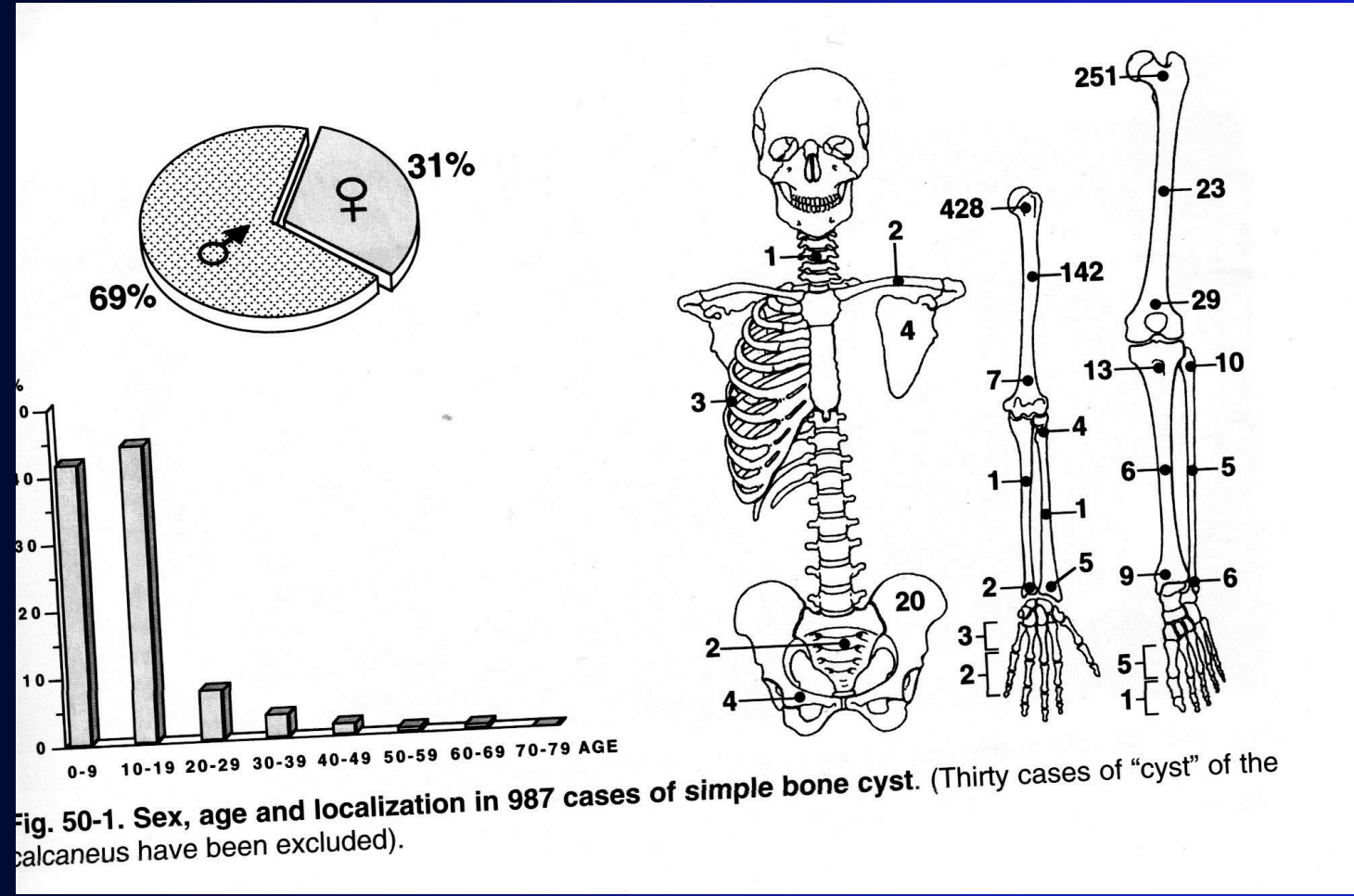
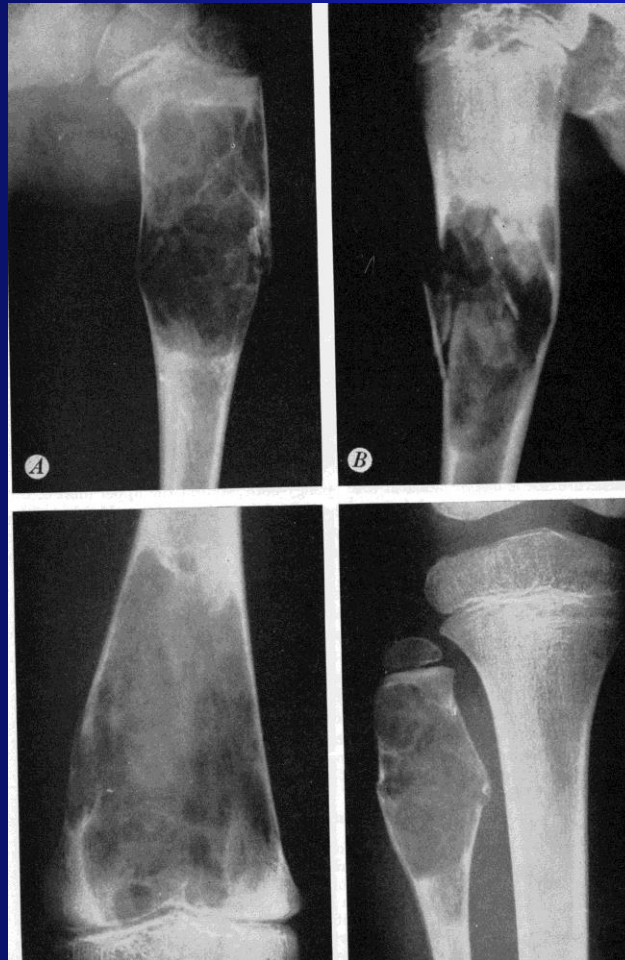
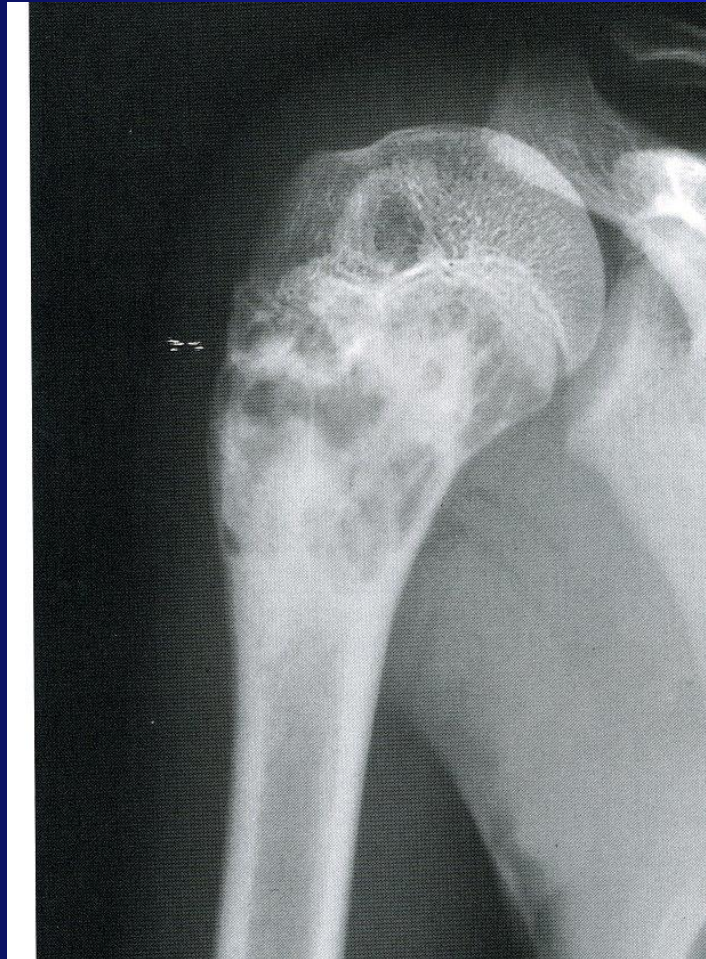
Fig. 50-1. Sex, age and localization in 987 cases of simple bone cyst. (Thirty cases of "cyst" of the calcaneus have been excluded).

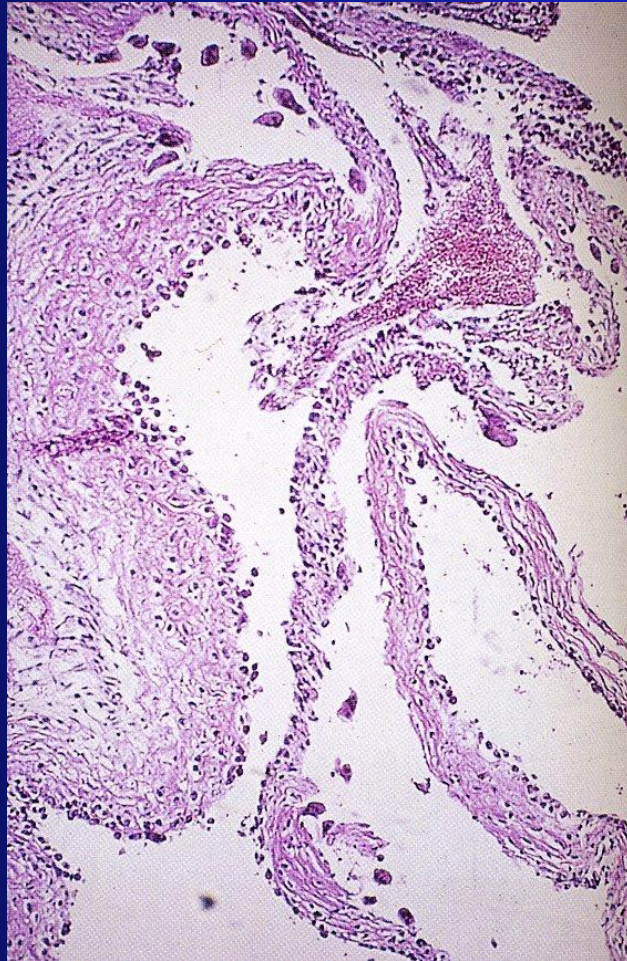
Unicameral Bone Cyst



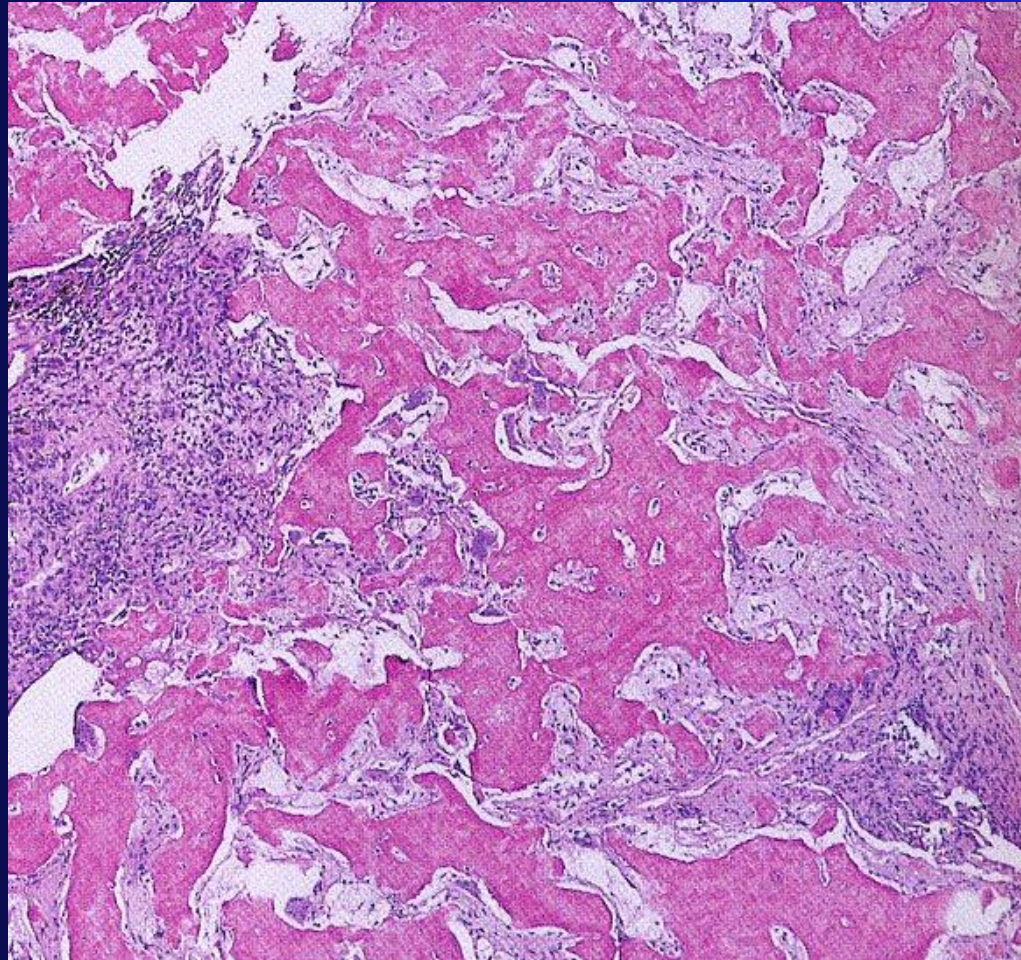
UBC



UBC



UBC POST FX



Osteoid Osteoma

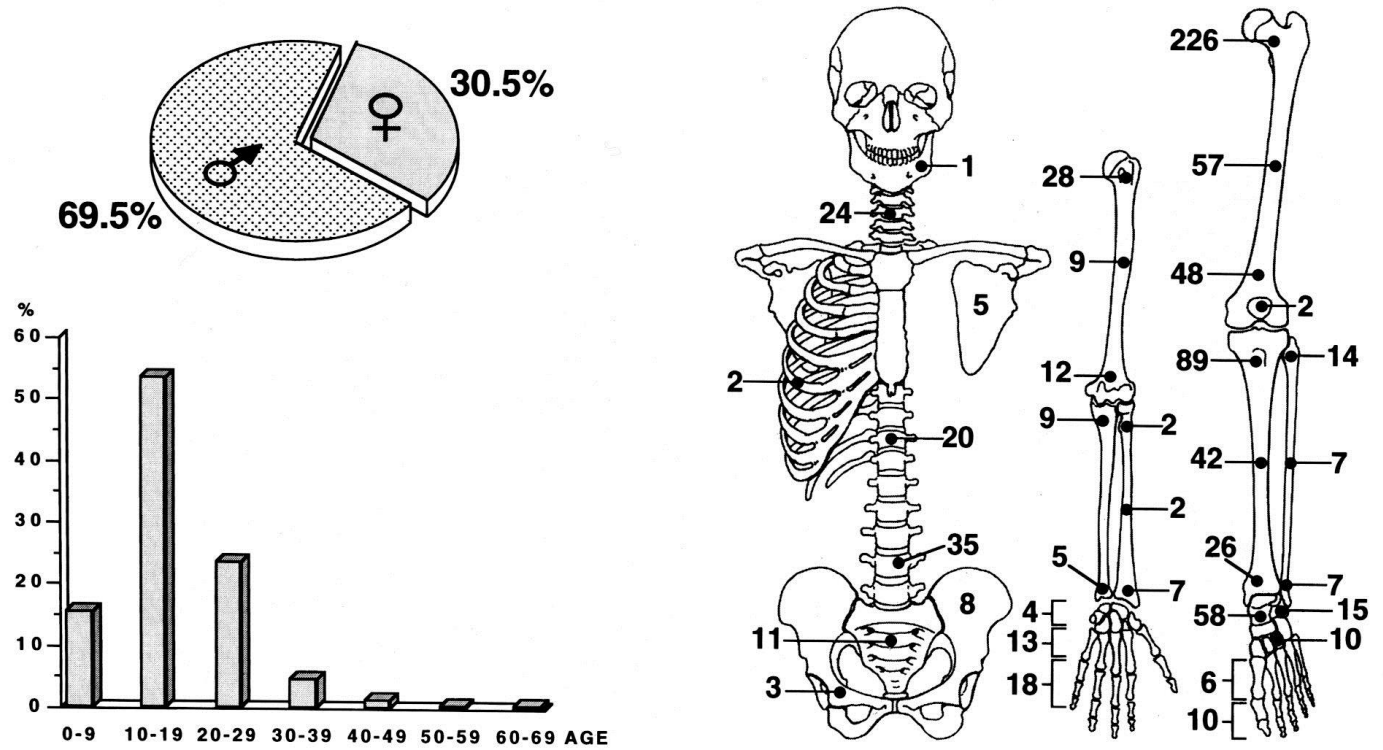


Fig. 25-1. Sex, age and localization in 836 cases of osteoid osteoma.

Osteoid Osteoma

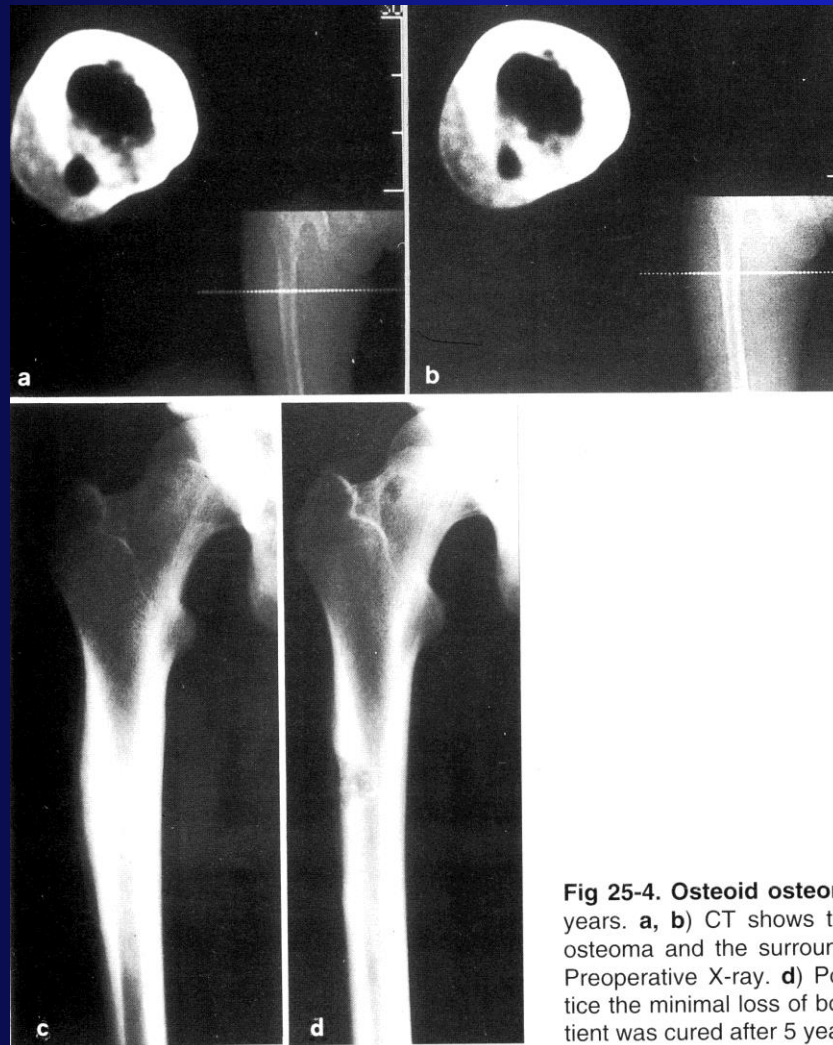
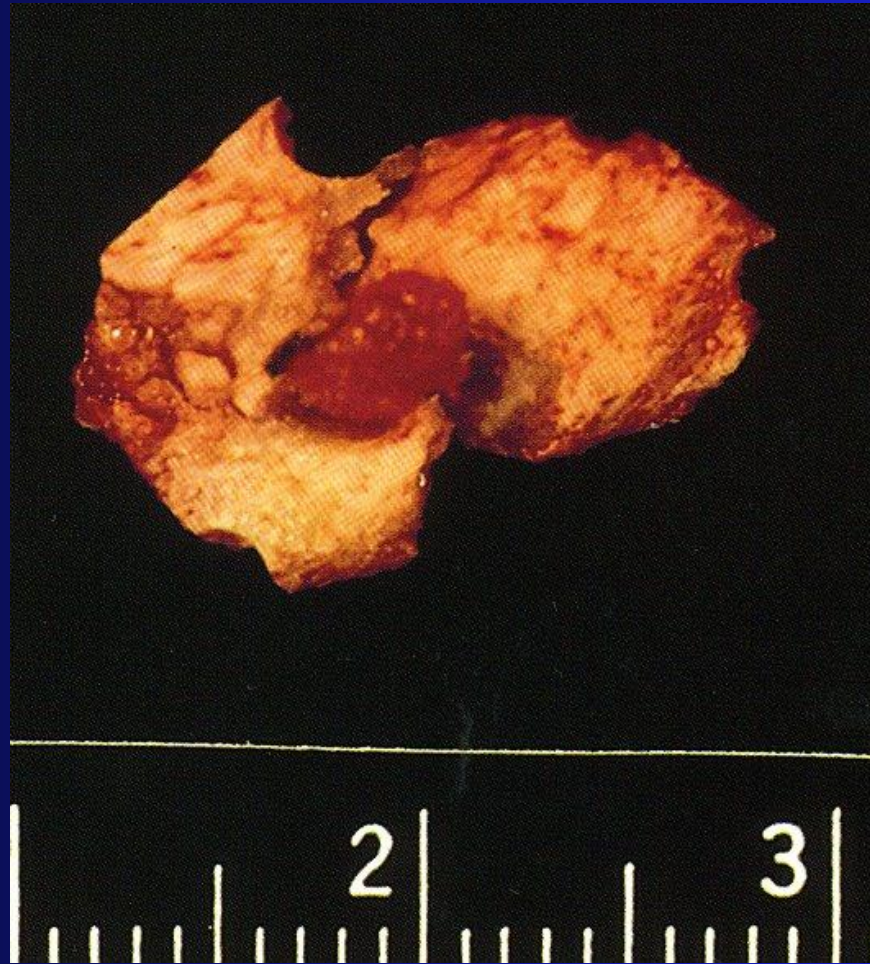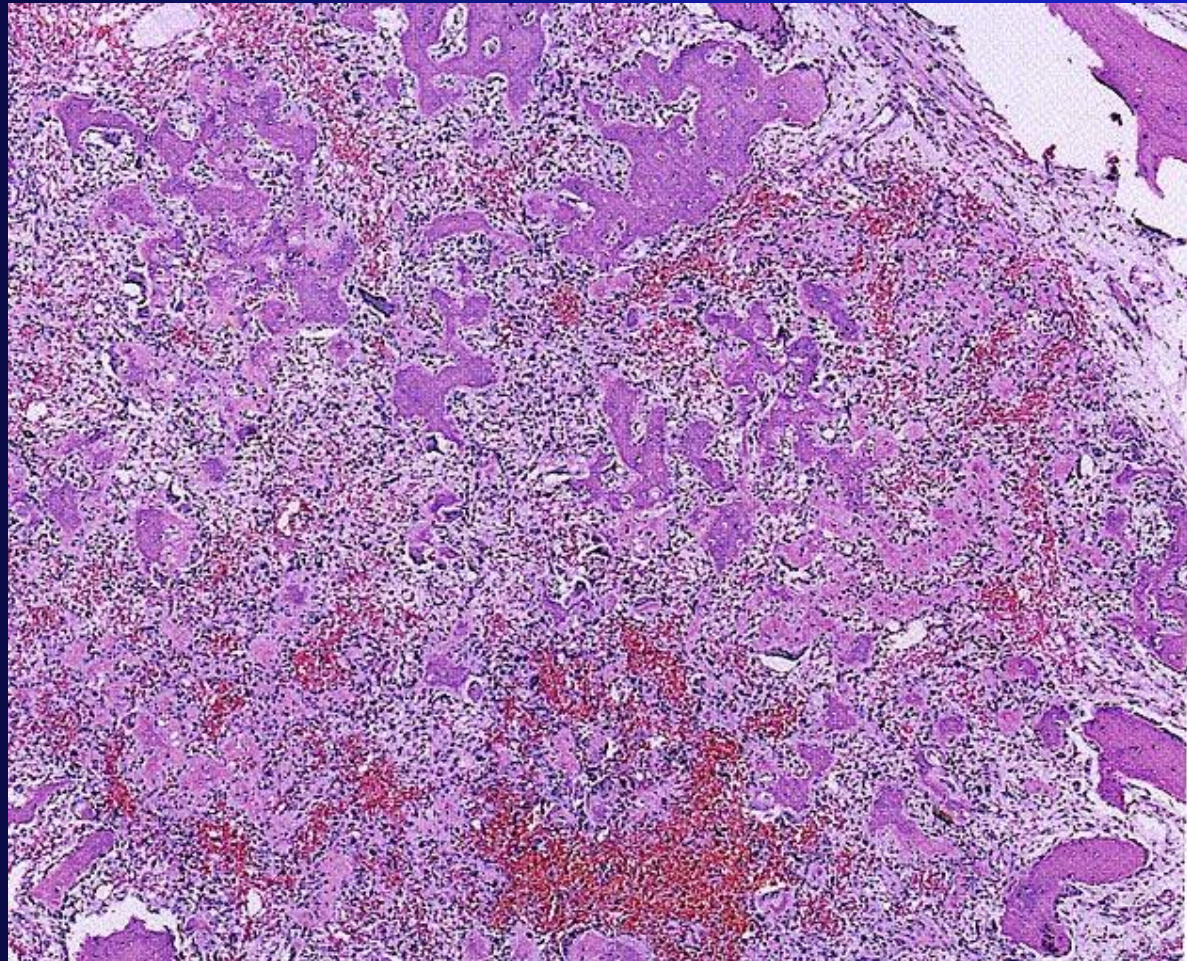


Fig 25-4. Osteoid osteoma, in a male aged 19 years. **a, b)** CT shows the intracortical osteoid osteoma and the surrounding bone reaction. **c)** Preoperative X-ray. **d)** Postoperative X-ray. Notice the minimal loss of bone substance. The patient was cured after 5 years.

Osteoid Osteoma



Osteoid Osteoma



Thank You

