

# Sports Medicine Rapid Fire

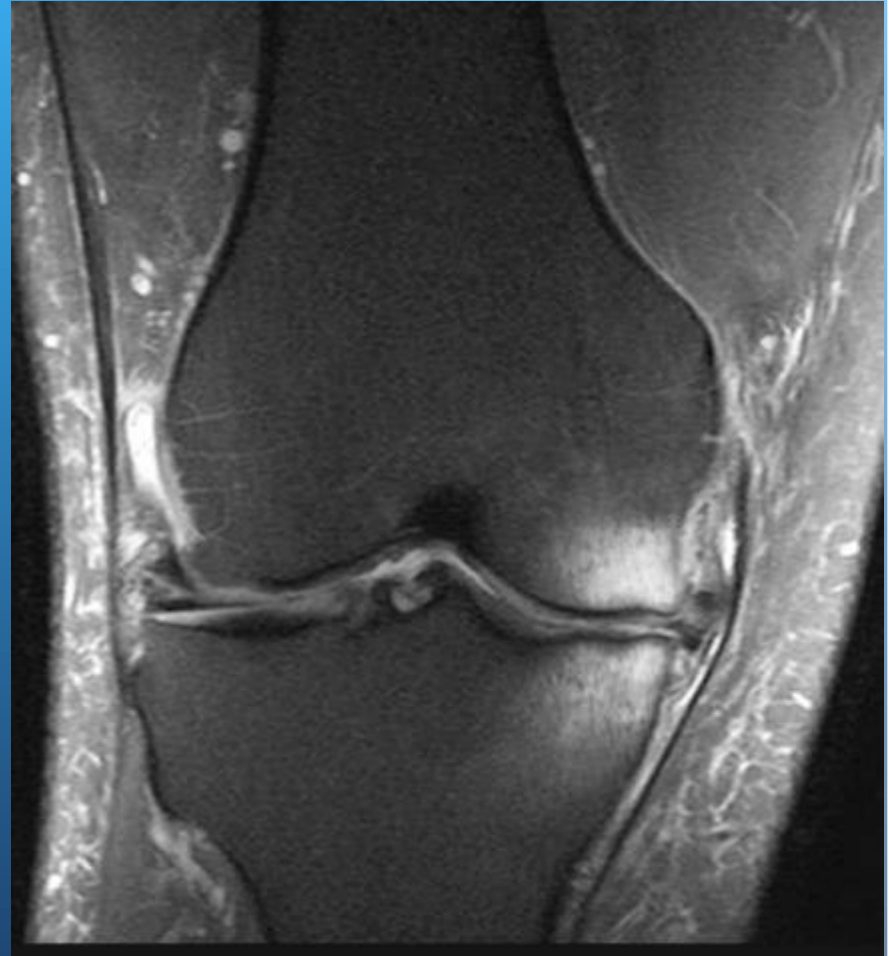Russell M. Nord, MD

COA 2018 Annual Meeting

San Francisco, CA

# Bone Marrow Lesion Treatment

- Who is treating these?
- Indications
- How much to inject?
- Post op protocol (WB restrictions)
- Results

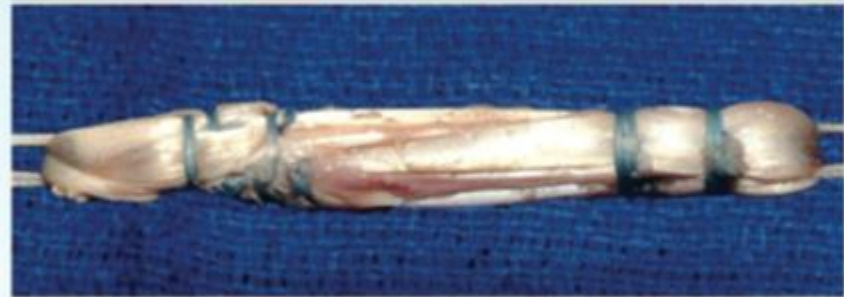

# ACL Graft Choice...

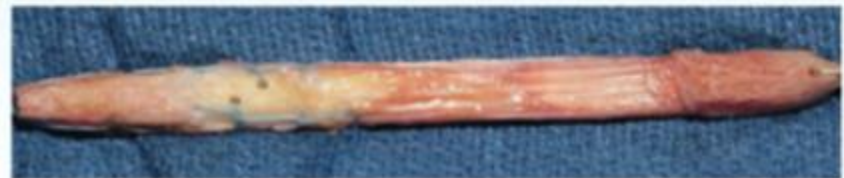- 17 yo M HS Football player
- 16 yo F HS Soccer player
- 25 yo recreational basketball player
- 50 yo recreational skier
  - Surgical Indications



A. *Achilles tendon*



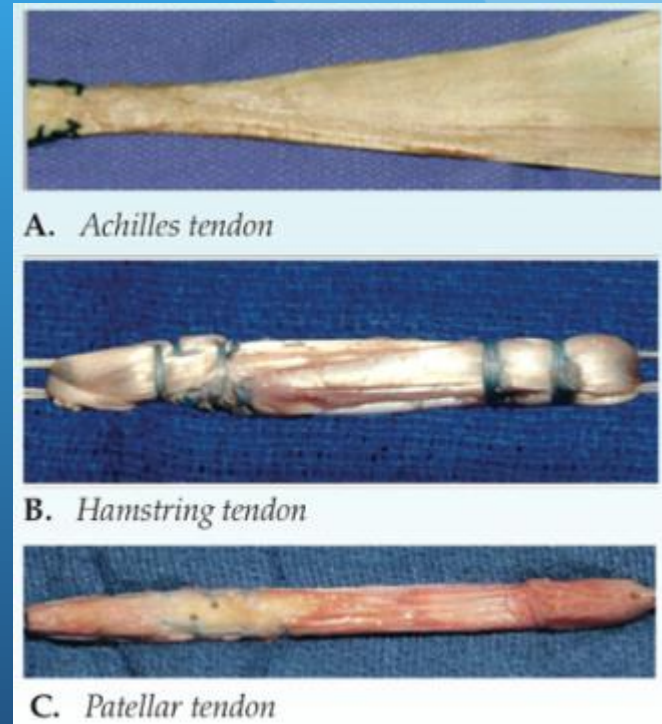
B. *Hamstring tendon*



C. *Patellar tendon*

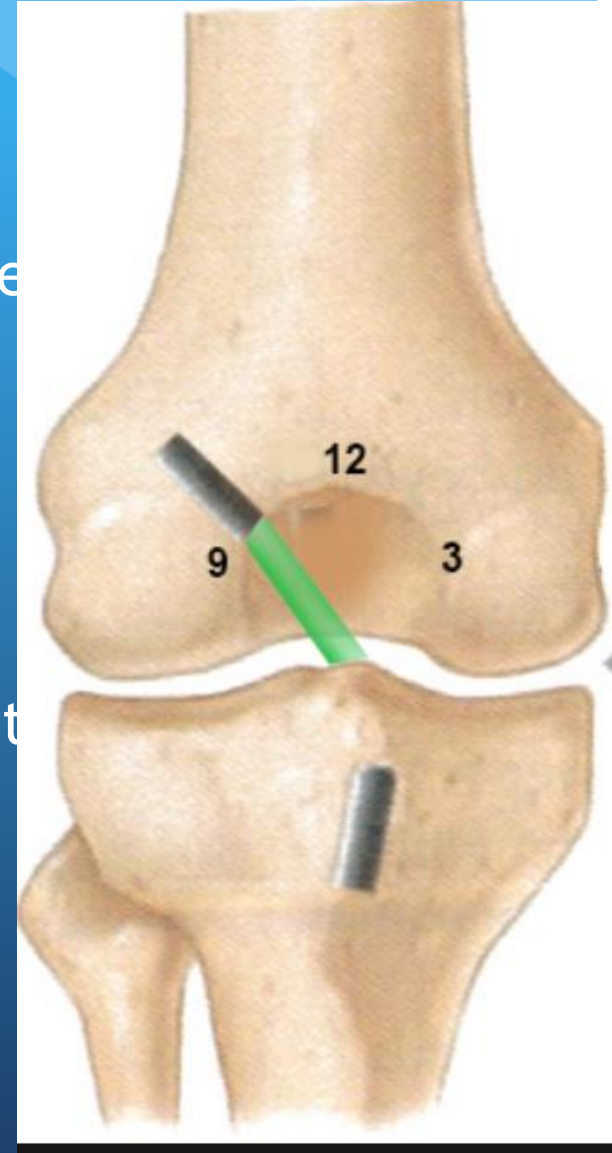
# ACL Graft Choice and Fixation (%'s)...

- BTB Autograft
- Semitendinosus and Gracilis Hamstring
  - Diameter Concerns?
- All-inside Quadrupled Semi-Tendinosis (+/- Gracilis) Hamstring
- Quad tendon
- Allograft - age of donor, irradiation???
  - BTB
  - Achilles
  - Soft tissue
  - Pre-sutured soft tissue
- How has this changed in the last 10 years?



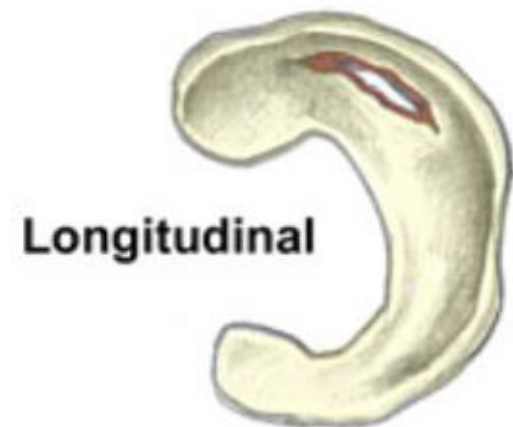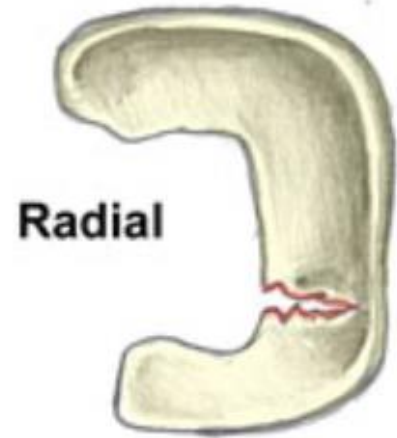# ACL Rapid Fire

- Medial portal vs. TransTibial?
  - Clock-face Goal
  - Target Old ACL Attachment?
- Outside-in, flexible reamer, straight reamer
- Hyperflex the knee?
- Tourniquet?
- Notchplasty?
- Post-op protocol - WB, ROM, CPM, Return to Play
  - Autograft vs. Allograft
- Anterolateral Ligament (ALL)
- AL Repair?
- Double Bundle?



# Meniscal Repair

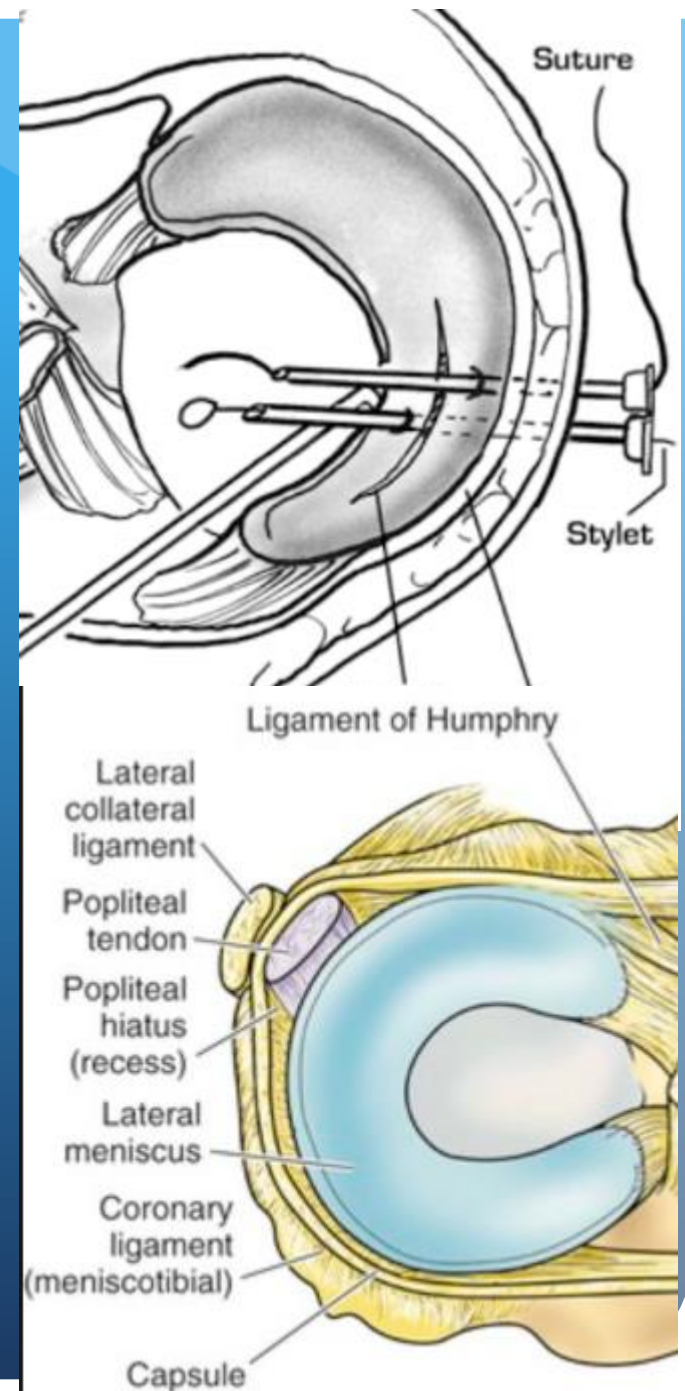
- Indications???
  - Red/White Zone Bucket Handle Chronicity - 33 yo
- Vertical/Bucket Handle Tears, Root Tears, Radial Tears, Horizontal Cleavage
  - Inside out
  - Outside in
  - All Inside
    - Preferred type of device
- Biologic Augmentation?
- Post op protocol
  - Function of tear type/size?
  - Bracing?





# Meniscal Repair

- Tell me about a patient/meniscal tear that you repair now, that you would have debrided 5 years ago.
- Tell me about a meniscal repair where your technique for its repair has changed in the last 5-10 years.
- Popliteal Hiatus?



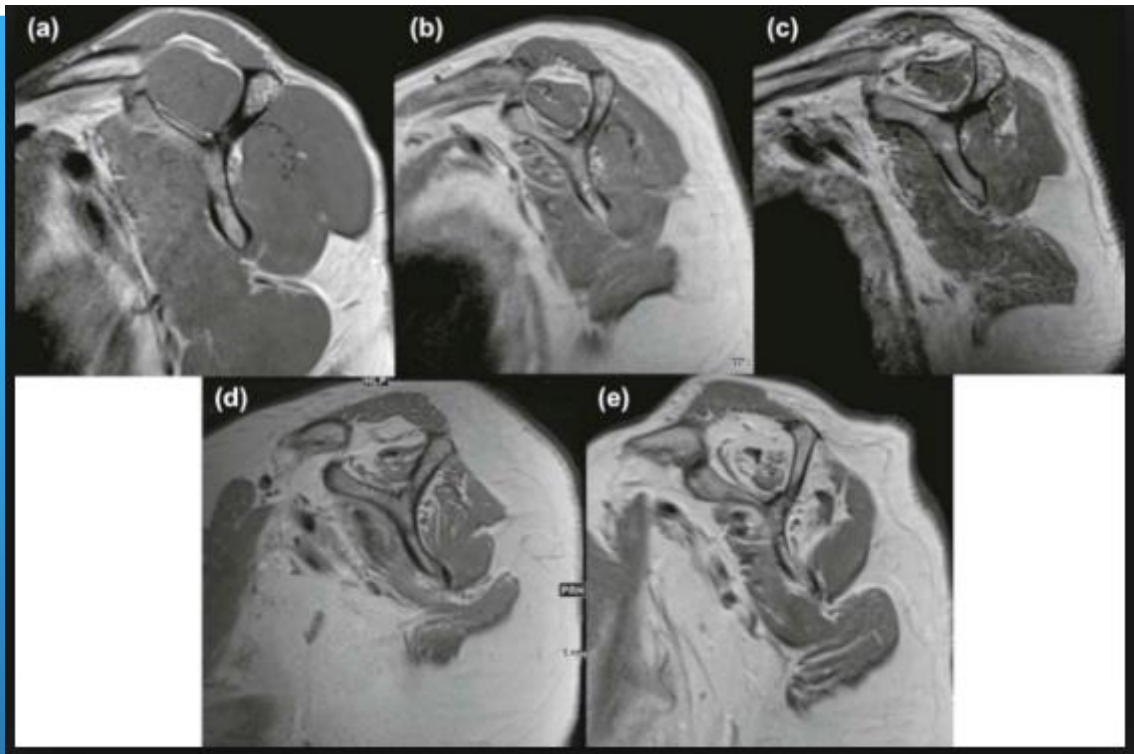




# Rotator Cuff

- 76F RHD R shoulder 1cm non-retracted, non-atrophied, atraumatic full thickness SS tear. Pain and weakness w SS testing
  - Is surgery always the way to go? Inject/PT?
    - Grade 2 atrophy
    - 2 cm tear, grade 2 atrophy
    - Large, retracted, atrophied, questionably repairable SS/IS tears
- Footprint prep - Bur, shaver, RF, microfracture, biologics?
- Acromioplasty?

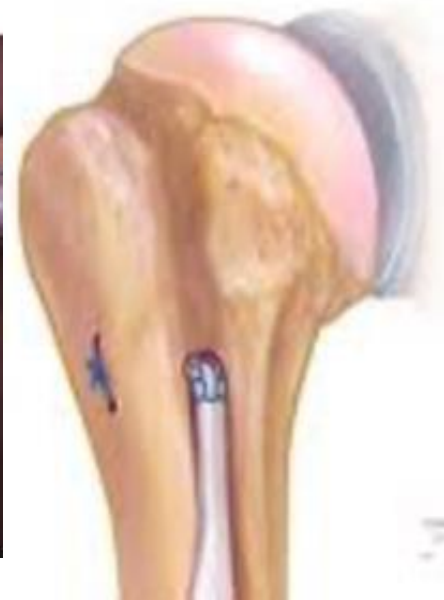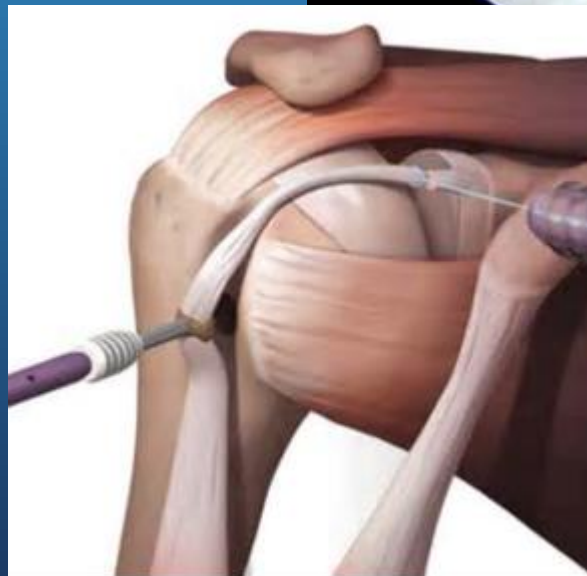
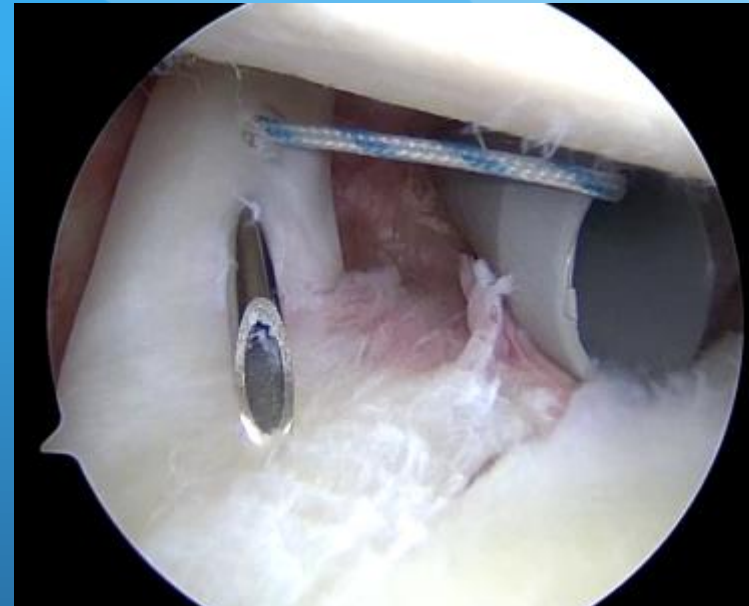
# Rotator Cuff



- What's your construct for a 1cm full thickness supraspinatus tear?
- What's your construct for a large U-shaped tear of the supraspinatus and infraspinatus?
- How do you handle a Grade 4 atrophied SS and IS tear retracted to the glenoid? Age 59? Age 70?

# Long Head of the Biceps Tendon

- What percent of rotator cuff repair cases also involve surgical management of the biceps?
  - Tenotomy?
  - Arthroscopic Tenodesis?
    - Technique
  - Open Tenodesis?
    - Technique
- What's your rehab after biceps tenodesis?



# AC Injuries

- Acute Surgery?
- Does technique depend on chronicity/type?

