

# WHEN TO REFER FOR HIP ARTHROSCOPY

**Dean K. Matsuda, MD**  
DISC Sports and Spine Center  
Marina del Rey



---

---

---

---

---

---

---

---

## DISCLOSURES

- **Royalties: Smith and Nephew, ArthroCare**
- **Consultant: Biomet**
- **Editorial Board member: Orthopedics Today**
- **Society Leadership:**
  - AAOS Adult Hip program committee
  - Director, Traveling Fellowship, Orthopedics Overseas

---

---

---

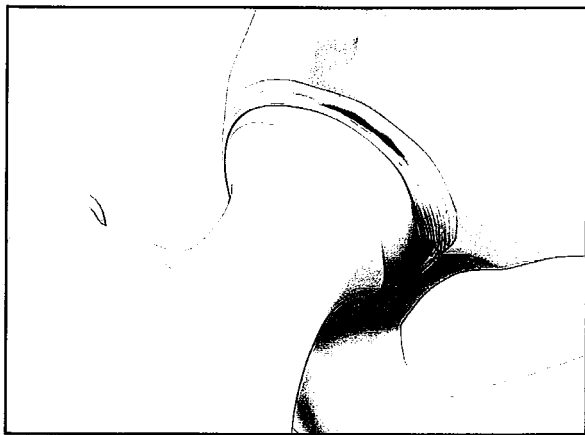---

---

---

---

---



---

---

---

---

---

---

---

---



---

---

---

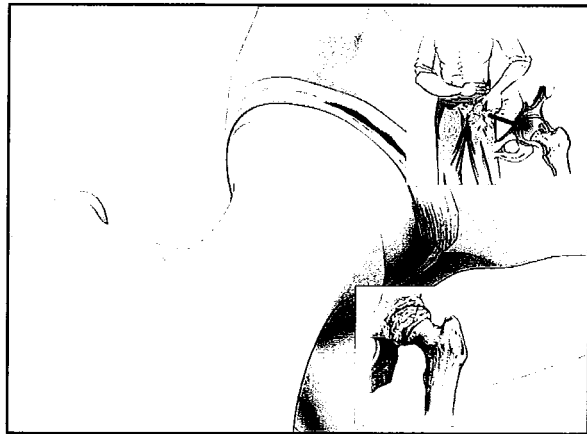
---

---

---

---

---



---

---

---

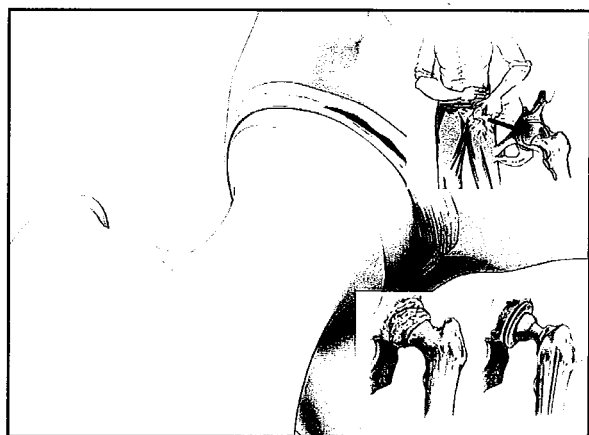
---

---

---

---

---



---

---

---

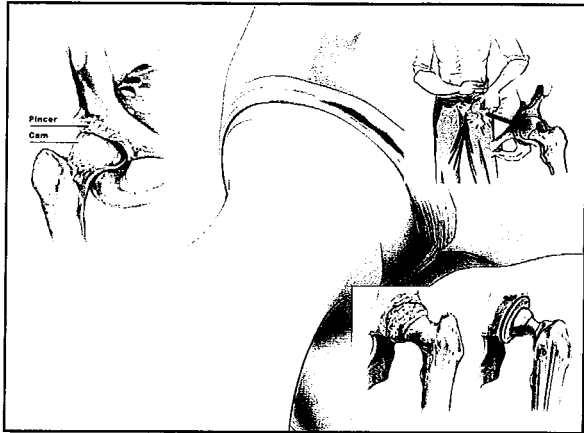
---

---

---

---

---



---

---

---

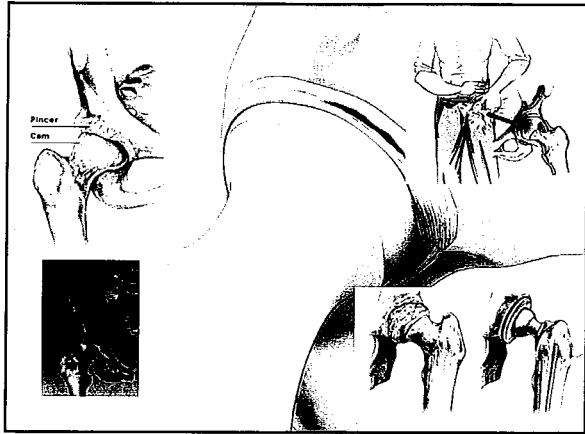
---

---

---

---

---



---

---

---

---

---


---

---

---

### Nonarthritic Hip Pain

- Anterior groin or lateral hip
- ± Mechanical symptoms
- Unresponsive to 3-6 months conservative measures
  - NSAID/Acetaminophen
  - Modify activities
- Age 15-55 ?



This block contains a text box with a title and a bulleted list of symptoms and characteristics for nonarthritic hip pain. To the right of the text is a small anatomical diagram of the hip joint, showing the femoral head and neck, and the acetabulum.

---

---

---

---

---


---

---

---

### Nonarthritic Hip Pain

- AP Pelvis
- Modified Dunn lateral views
- >2mm joint space



---

---

---

---

---


---

---

---

### Nonarthritic Hip Pain

- AP Pelvis
- Modified Dunn lateral views
- Cam FAI Bump



---

---

---

---

---

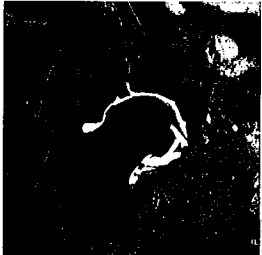
---

---

---

### Nonarthritic Hip Pain

- MR Arthrogram



---

---

---

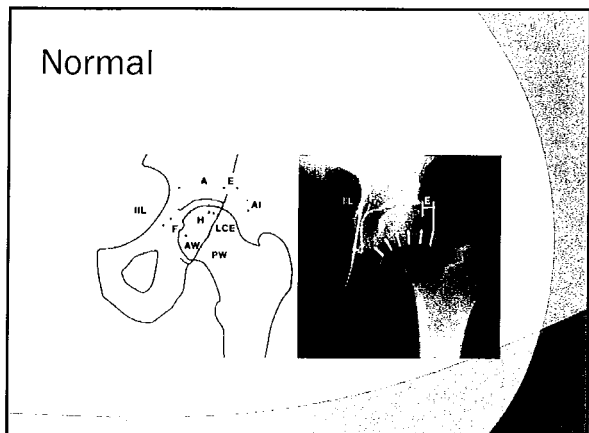
---

---

---

---

---



---

---

---

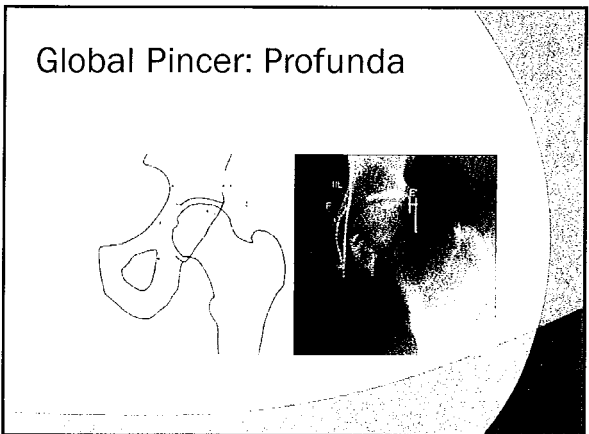
---

---

---

---

---



---

---

---

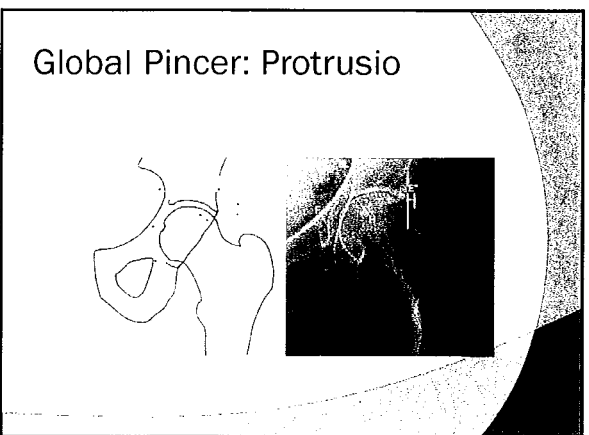
---

---

---

---

---



---

---

---

---

---

---

---

---



---

---

---


---

---

---

---

---



---

---

---

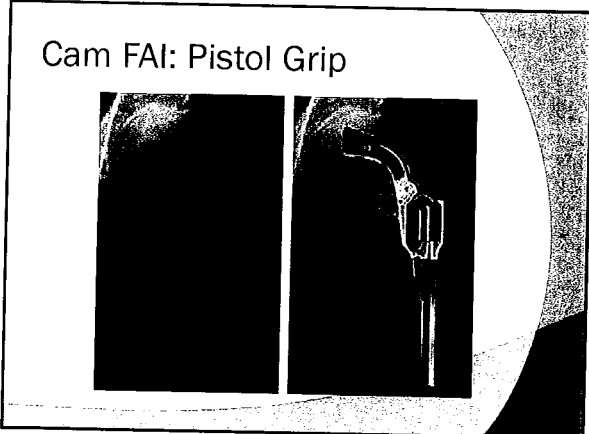
---

---

---

---

---



---

---

---


---

---

---

---

---



---

---

---

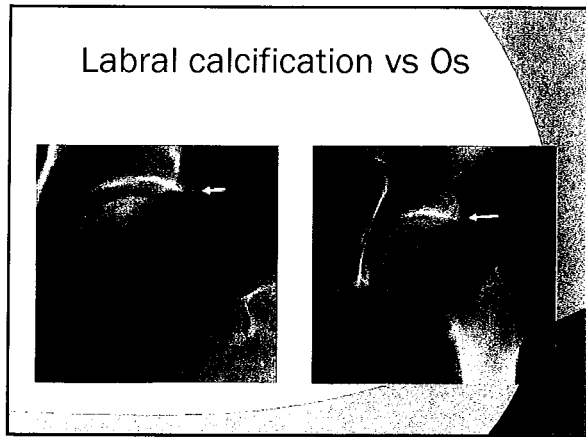
---

---

---

---

---



---

---

---

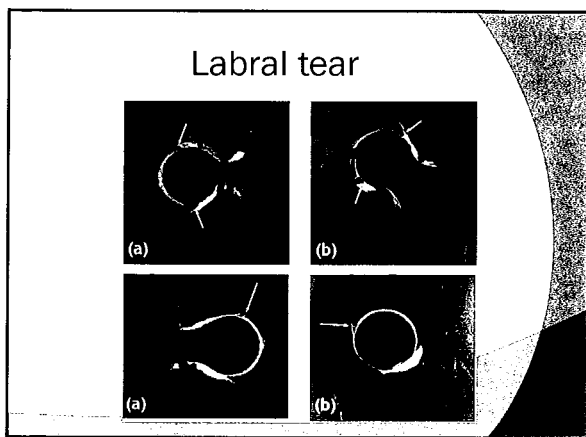
---

---

---

---

---



---

---

---


---

---

---

---

---



---

---

---

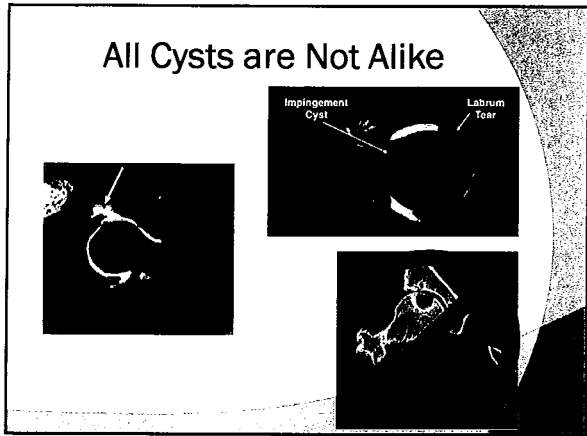
---

---

---

---

---



---

---

---

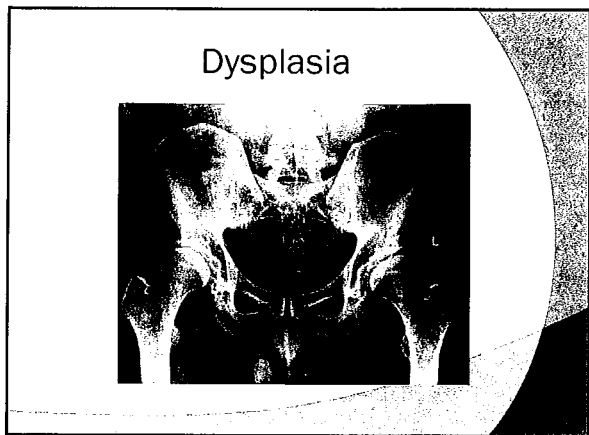
---

---

---

---

---



---

---

---

---

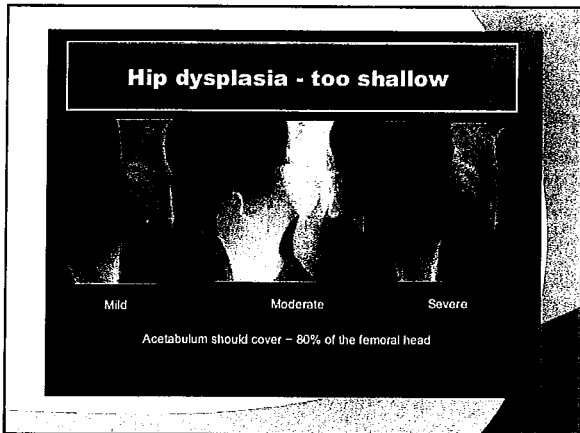
---

---

---

---





---

---

---

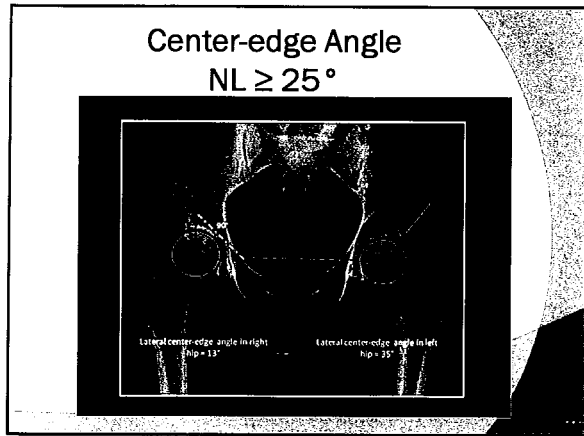
---

---

---

---

---



---

---

---


---

---

---

---

---



---

---

---

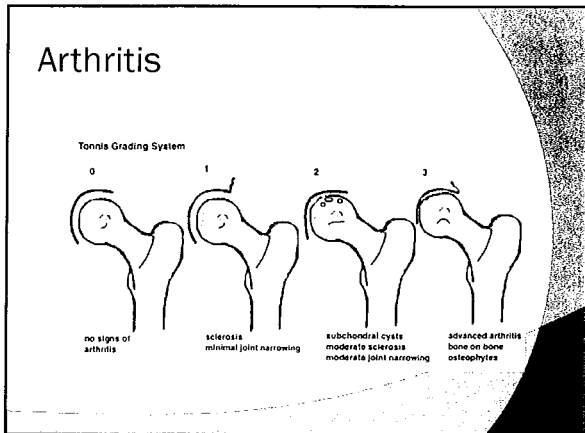
---

---

---

---

---



---

---

---

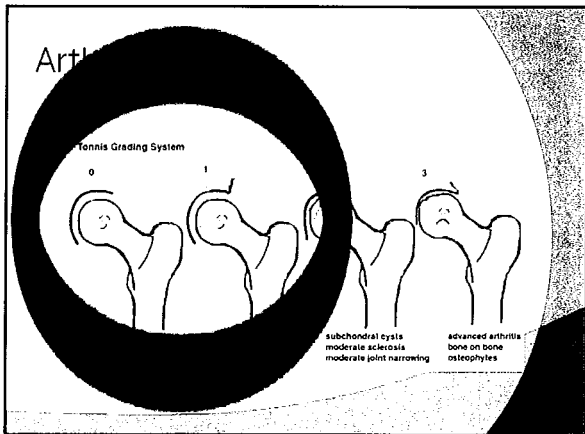
---

---

---

---

---



---

---

---

---

---

---

---

---



---

---

---


---

---

---

---

---



---

---

---

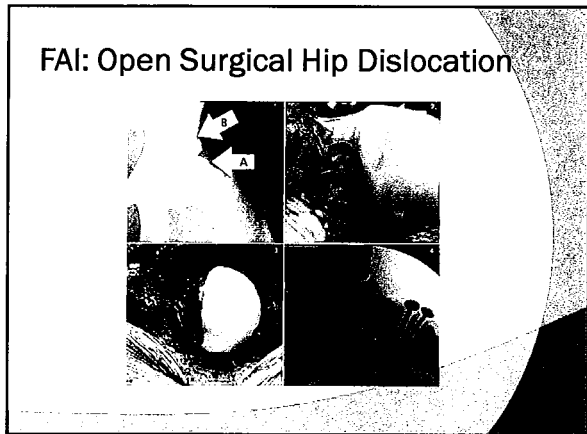
---

---

---

---

---



---

---

---

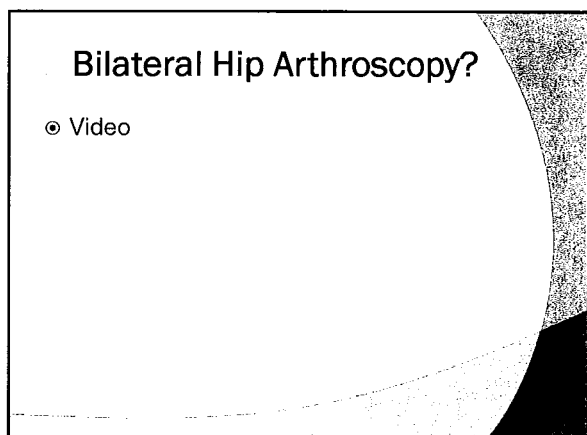
---

---

---

---

---



---

---

---

---

---

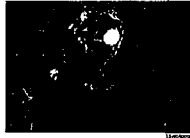---

---

---

## Buttock Pain?

- ⊙ If R/O Lumbar causation
- ⊙ **FAI** (10% posterior pain)
- ⊙ **Ischiofemoral Impingement**
- ⊙ **Proximal Hamstring Syndrome**
  - Ischial bursitis
- ⊙ **Deep Gluteal Syndrome** (Extra-spinal sciatic entrapment)



---

---

---

---

---

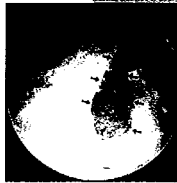---

---

---

## Lateral Pain?

- ⊙ **Trochanteric Bursitis**
  - CSI
  - MRI
    - Gluteus medius/minimus tear
    - RCT of Hip
- ⊙ **External Snapping Hip (ITB)**
  - Conservative



---

---

---

---

---

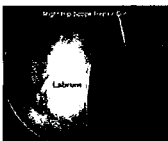
---

---

---

## What about in the ER?

- ⊙ Hip dislocation or fracture-dislocation
- ⊙ Septic Hip



---

---

---

---

---

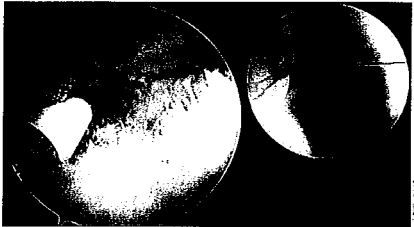
---

---

---

### What about in the THA?

- ⊙ Painful snapping hip after THA
- ⊙ Arthroscopic iliopsoas tenotomy



Guichard, Orthop Traumatol Surg Res. 2017

---

---

---

---

---


---

---

---

### TAKE HOME POINTS

- ⊙ Labral tears ← bony deformities (FAI, Dysplasia)
- ⊙ Nonarthritic hip pain
  - Flexion-induced groin or lateral
  - 2mm+ joint space
  - Tönnis 0, 1
  - Borderline dysplasia
  - Age?
- ⊙ Hip arthroscopy
  - Lateral: RCT of the Hip
  - Anterocentral: Osteitis pubis
  - Posterior: R/O Lumbar → DGS, HS, IFI
  - Hip dislocation, OC fxs
  - Septic hip
  - Painful snapping THA



---

---

---

---

---

---

---

---

### THANK YOU



---

---

---

---

---

---

---

---