Elbow Arthroscopic Osteocapsular Arthroplasty

Neil G. Harness, MD
Kaiser Permanente Orange County
University of California Irvine

UCIrvine

KAISER PERMANENTE®

Elbow Arthritis

- Rare in most general orthopaedic practices
  - Presents with pain and stiffness
- OA 1-2% of all cases of elbow arthritis
  - Trauma, RA, other arthritides make up the rest
- Primary OA
  - Almost exclusively men
  - High force

Elbow OA

- Symptoms
  - Stiffness
  - Locking (loose bodies)
  - Pain at end range of motion
  - Pain through all motion (late)

Elbow Arthritis

- Detailed history
  - Must assess for pain, stiffness, or both
  - Future functional demands/expectations
  - Prior tx – nsaids, PT, splinting, surgery
  - Hx of prior infection/ surgery.

UCIrvine

KAISER PERMANENTE®

Elbow Arthritis

- Signs
  - Flexion contracture 15-60 degrees
  - Variable flexion loss
- Functional motion
  - 30-130 degrees
- Flexion contracture tolerated better than loss of flexion

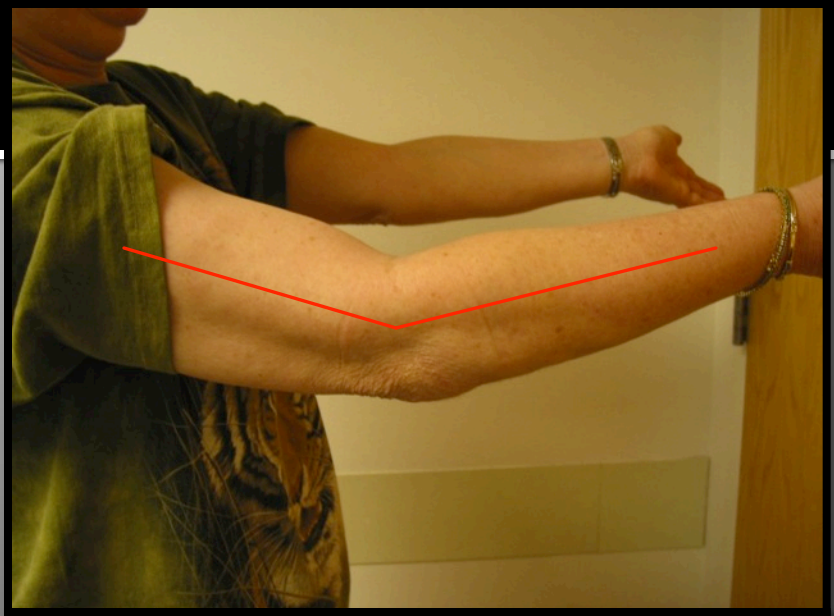

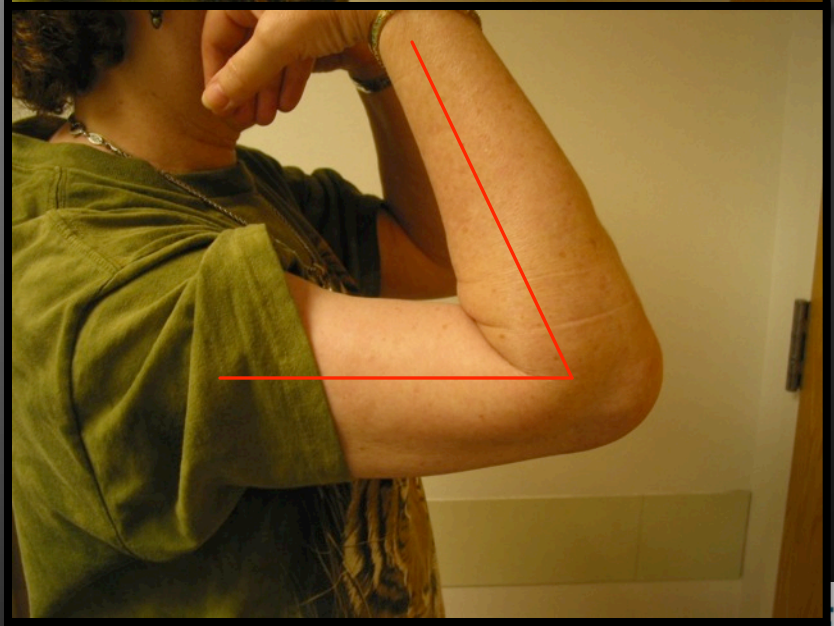

UCIrvine

KAISER PERMANENTE®

Radiographs

Radiographs

UCIrvine

KAISER PERMANENTE®

Elbow OA

- Coronoid osteophyte
  - Limits flexion
- Olecranon ostephyte
  - Limits extension
- Pain with terminal motion

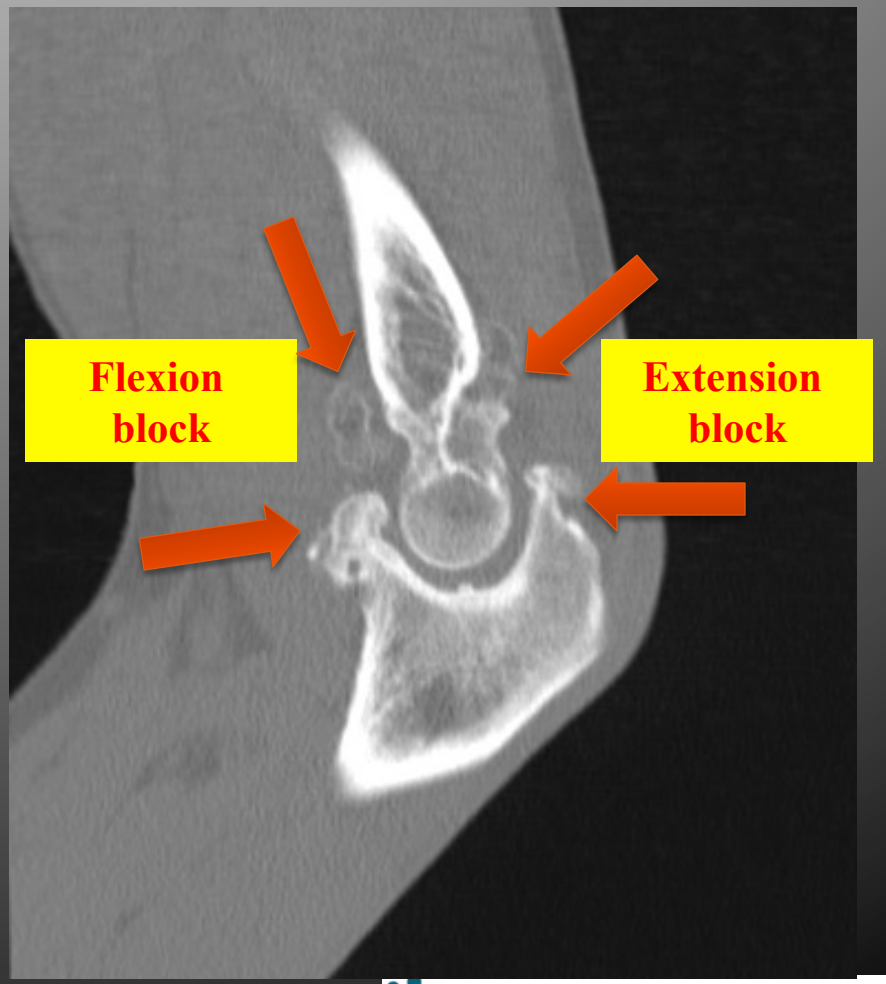

UCIrvine

KAISER PERMANENTE®

Surgical Indications

- Locking
  - Loose bodies
- Pain
  - Impingement
- Stiffness

UCIrvine

KAISER PERMANENTE®

Surgical Management

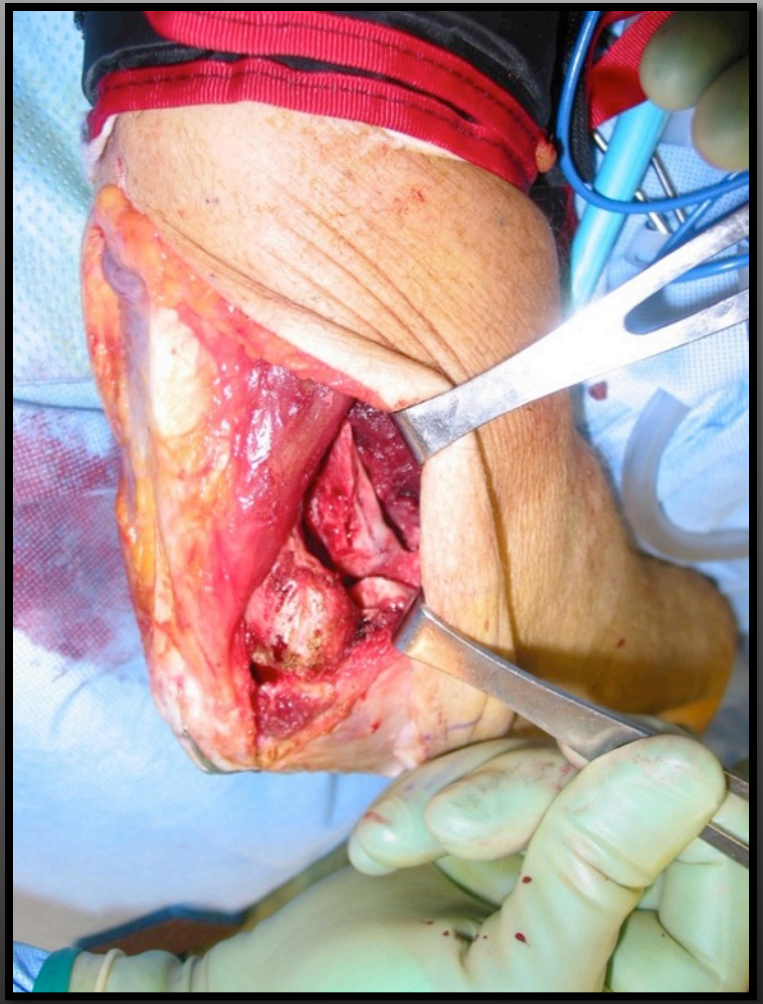

UCIrvine

KAISER PERMANENTE®

Open release – "OK"

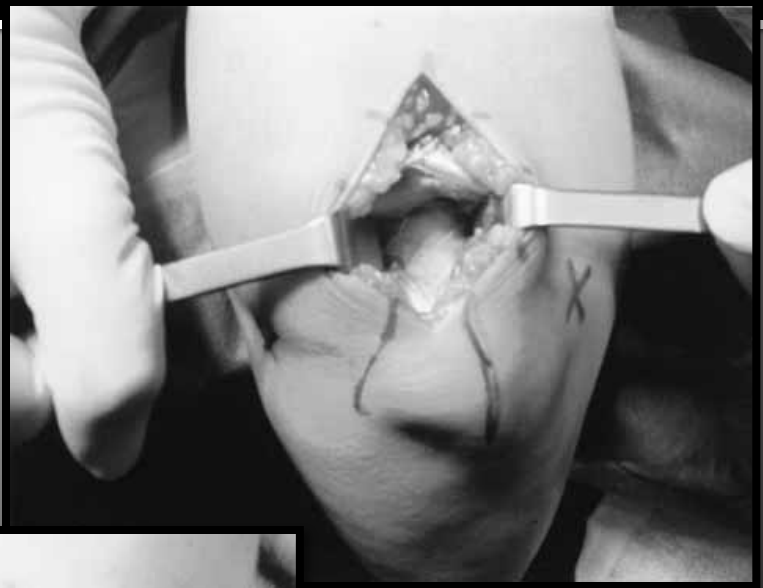

UCIrvine

KAISER PERMANENTE®

Elbow Arthroscopy

- Loose body removal
  - OA, OCD
- Synovectomy
  - OA, RA
- Capsular release
  - OA, post traumatic
- Osteocapsular arthroplasty
  - OA
- Fracture Management

UCIrvine

KAISER PERMANENTE®

History

- Burman, 1931: used a 3 mm endoscope in a cadaver, concluded elbow was unsuitable for examination
- Watanabe, 1971: developed 1.7 mm arthroscope for several small joints
- Ito, 1979: 226 cases of elbow arthroscopy in Japanese literature

History

- Hempfling, 1983: prone position for elbow arthroscopy described in German literature
- Andrews and Carson, 1985: reviewed technique and portal anatomy
- Poehling, 1989: prone approach along with proximal medial portal

Osteocapsular Arthroplasty

- O'Driscoll
  - 3D reshaping of bones
  - Capsular release
    - Anterior/Posterior
  - Osteophyte excision
    - Coronoid/Olecranon spur
    - Coronoid/olecranon fossa

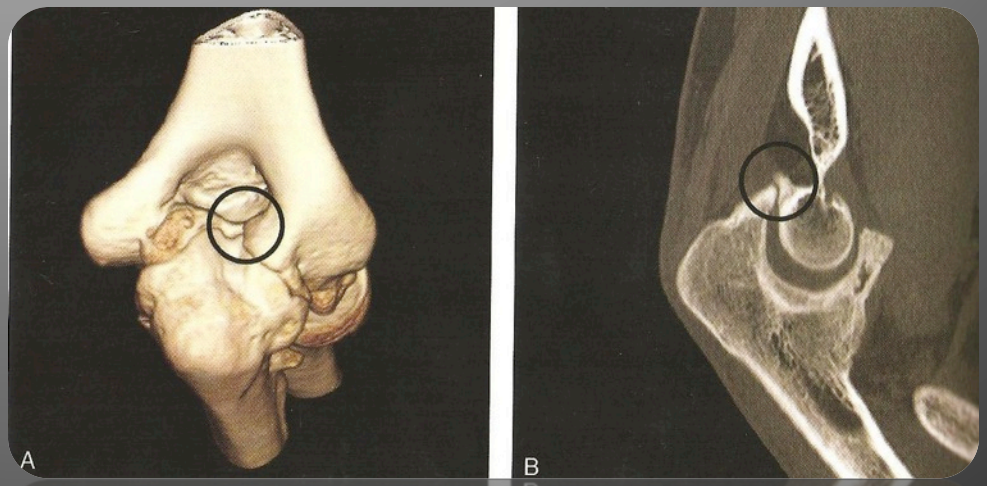

UCIrvine

KAISER PERMANENTE®

Arthroscopic Release

- Advantages
  - Limit contractures
  - Less risk of HO
  - Low morbidity
  - Less pain and earlier rom
  - Less damage to surrounding musculature
  - Decreased recovery period
  - Improved articular inspection
  - Improved cosmesis

UCIrvine

KAISER PERMANENTE®

Arthroscopic Release

- Disadvantages
  - Technically demanding
  - Requires experience

UCIrvine

KAISER PERMANENTE®

Arthroscopic tx of OA

- Contraindications
  - Lack of experience
  - Severe joint stiffness
    - Loss of flexion > 90
    - +/- ulnar nerve transposition
  - Advanced articular cartilage loss or bony deformity

UCIrvine

KAISER PERMANENTE®

Osteocapsular arthroplasty

- Obstacles
  - Decreased working room/view
  - Nerves at greater risk
  - Intraarticular volume
    - Contracture 6ml
    - Normal 25 ml

Tiger Country

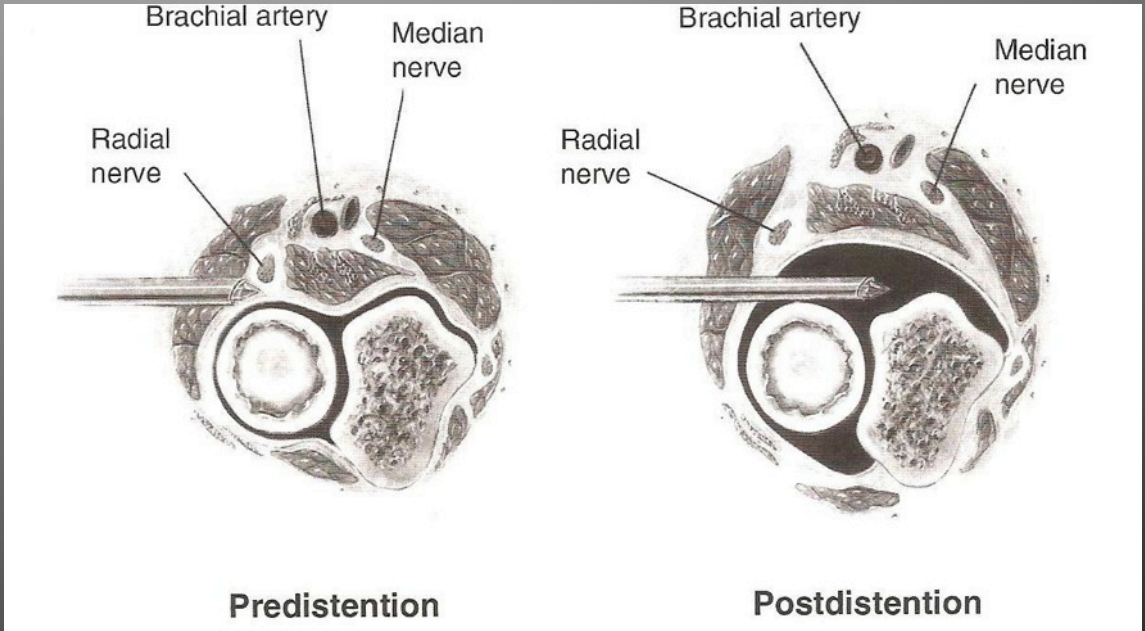

UCIrvine

KAISER PERMANENTE®

Portal Location

- Proximal anteromedial
- Anterolateral
- Proximal anterolateral
- Direct lateral "soft spot"
- Anteromedial
- Posterolateral
- Straight posterior

UCIrvine

KAISER PERMANENTE®

Proximal Anteromedial Portal

- Varied
  - 2 cm proximal
  - 1 cm prox, 1 cm ant
  - 2 cm prox, 2 cm ant
- flexors / pronator
  - center of joint
  - anterior surface of humerus

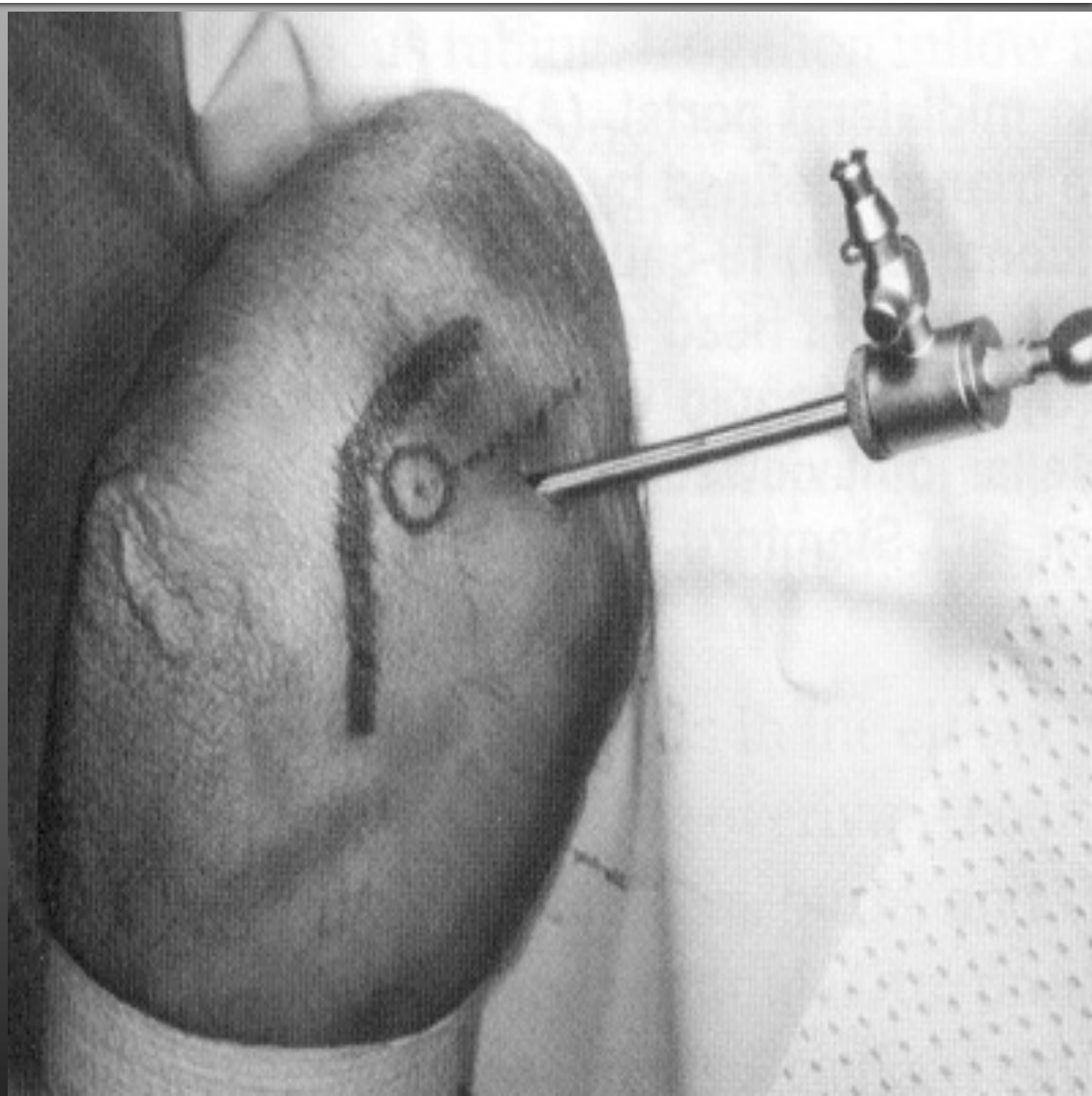

UCIrvine

Proximal Anteromedial Portal

- Post antebrachial cutaneous nerve
  - 2.3 mm
- Median nerve
  - 12.4 to 22.3mm
  - Brachial Artery

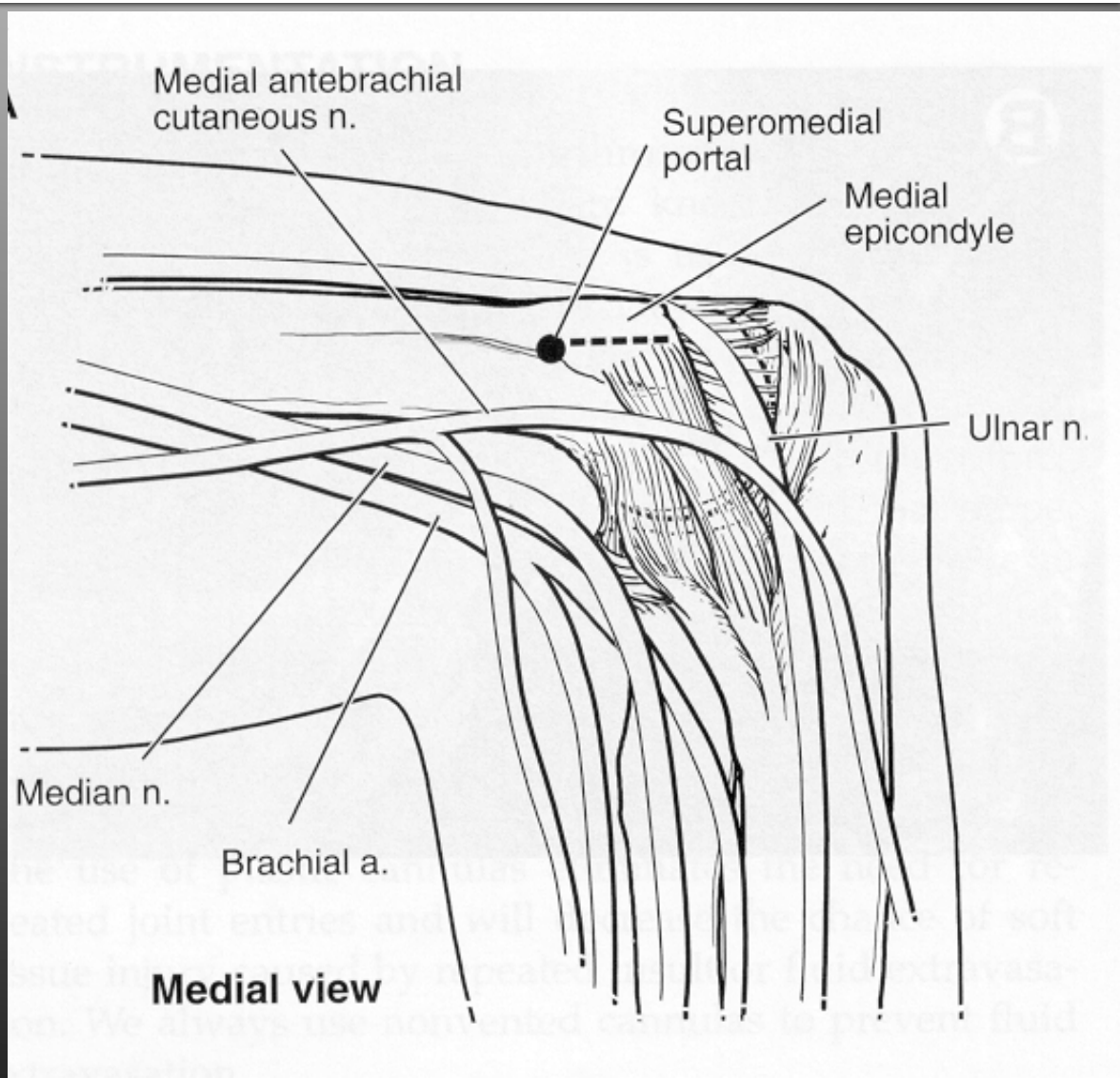

UCIrvine

Proximal Anteromedial Portal

- Ulnar Nerve
  - 12 to 23.7 mm
  - no risk - trocar ant to IM septum
- Contraindicated
  - nerve transposition
  - subluxing ulnar nerve

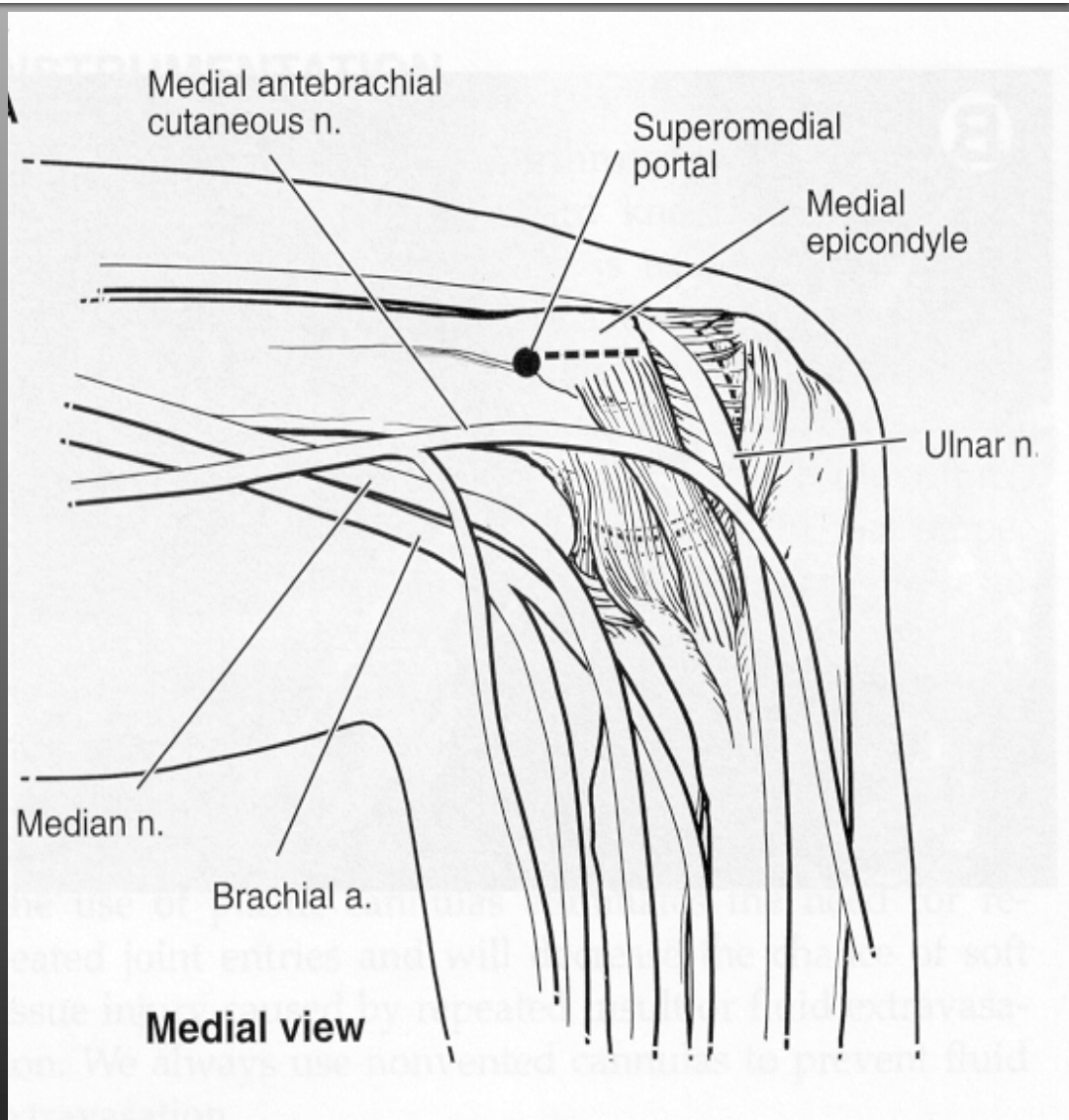

UCIrvine

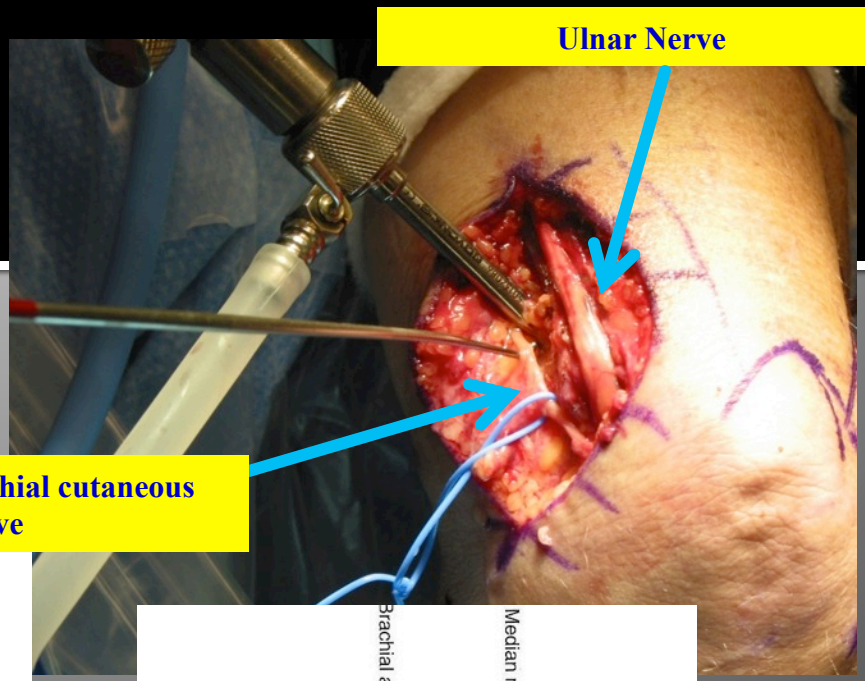

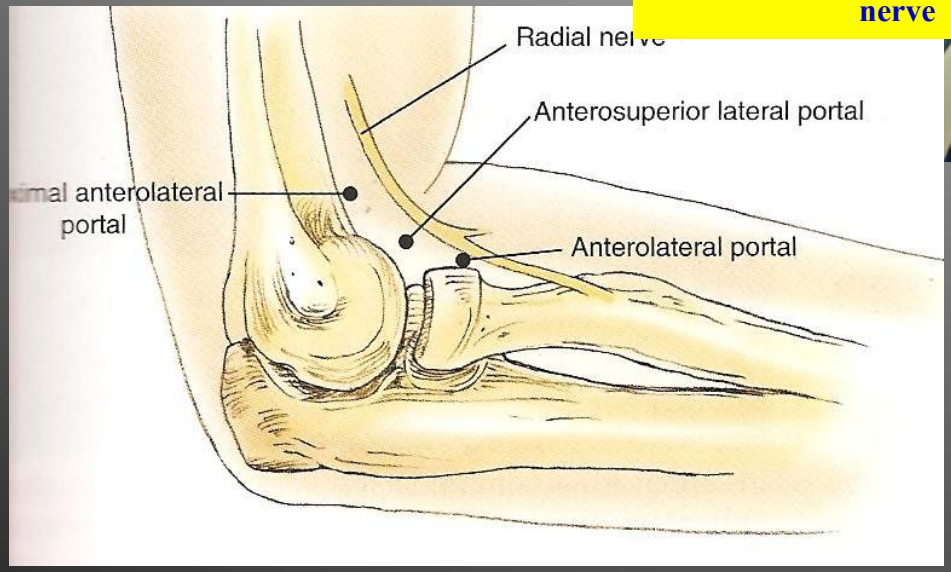

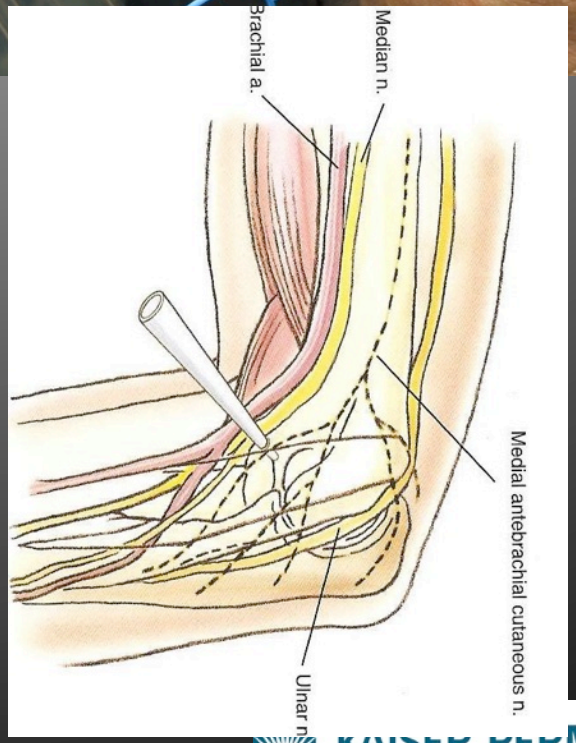

UCIRVINE

KAISER PERMANENTE®

Anterolateral Portal

- 1 cm ant to Lat E
- 2 cm distal to Lat E
- Soft spot
- Trocar aim to joint center
- Thru ECRB + Lateral capsule deep to the radial nerve

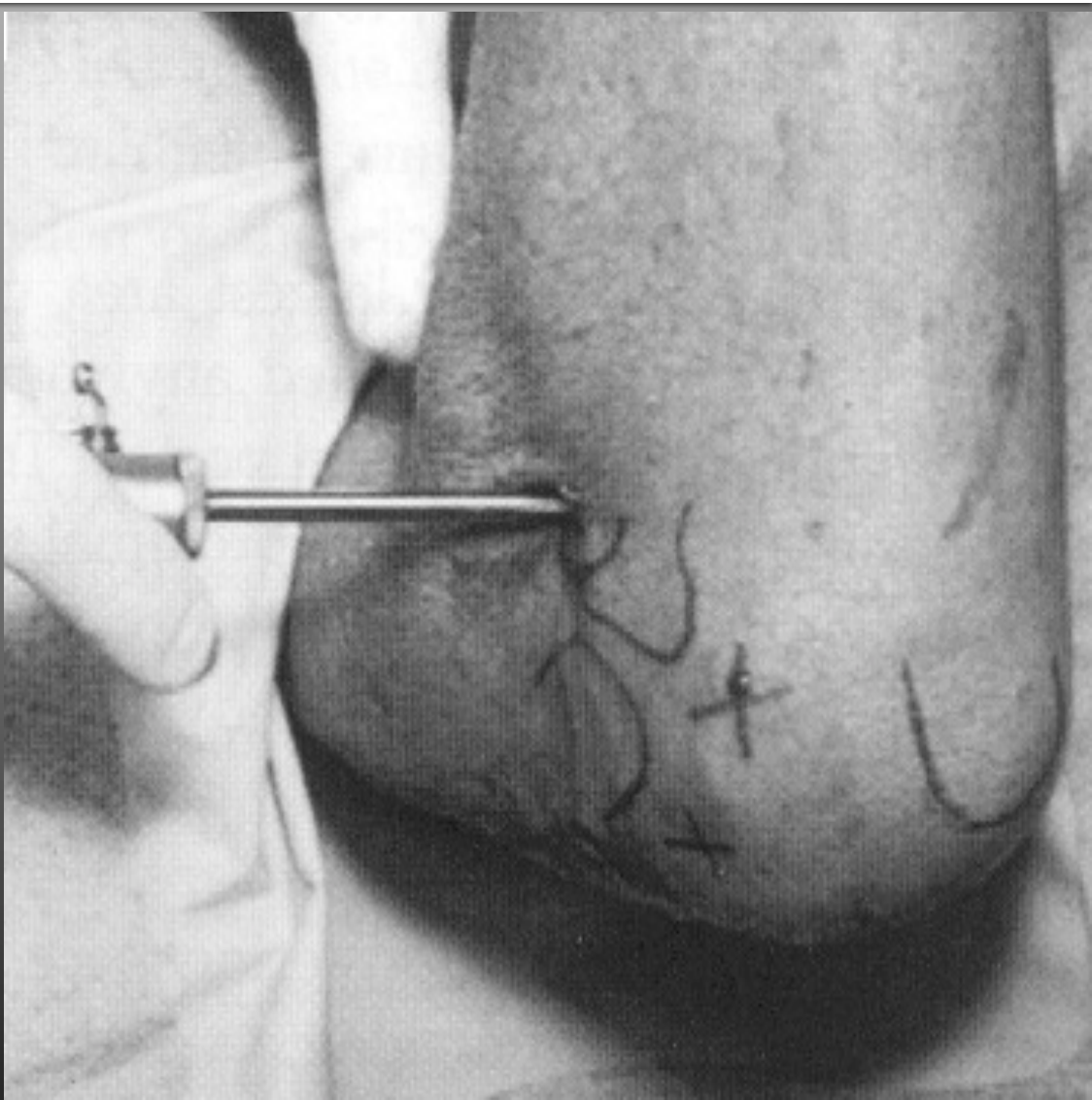

UCIrvine

Anterolateral Portal - At Risk

- Radial nerve
  - 2 mm to 11 mm
- Lateral antebrachial cutaneous superficially

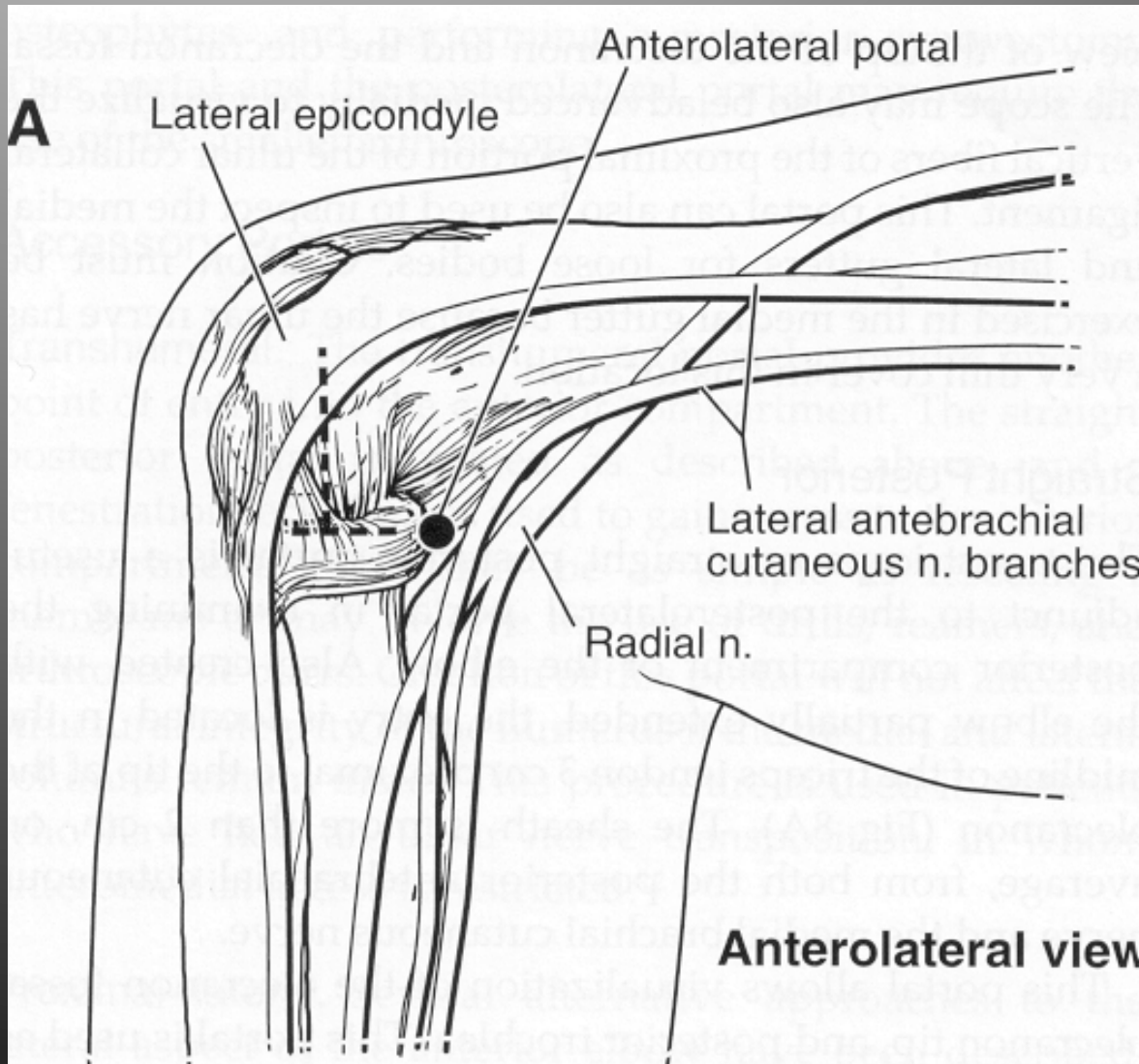

UCIRVINE

Posterior Portal

- 3 cm prox to olecranon
- posterior compartment
- slight flexion, blunt trocar advanced anteriorly toward olecranon fossa
- thru triceps

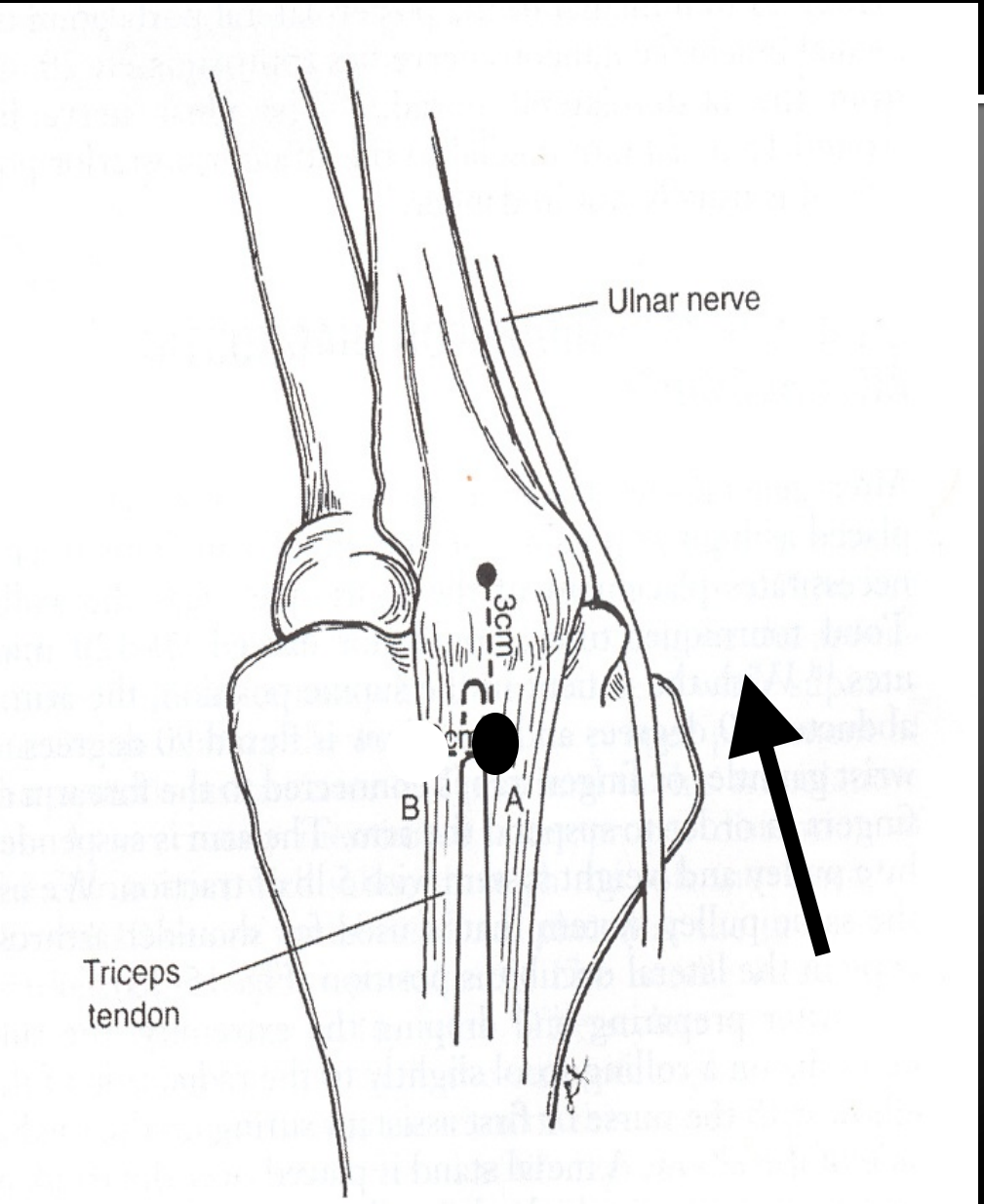

UCIrvine

Posterior Portal

- Minimal
  - ulnar nerve medially
  - radial nerve laterally
  - posterior branch of the lateral anterbrachial cutaneous nerve

UCIrvine

KAISER PERMANENTE®

Posterior Lateral Portal

- 3 cm prox to olecranon
- Lateral edge of the triceps tendon
- elbow in 45 deg flex to relax triceps
- blunt trocar directed toward center of olecranon fossa

UCIrvine

KAISER PERMANENTE®

Posterolateral Portal

- minimal

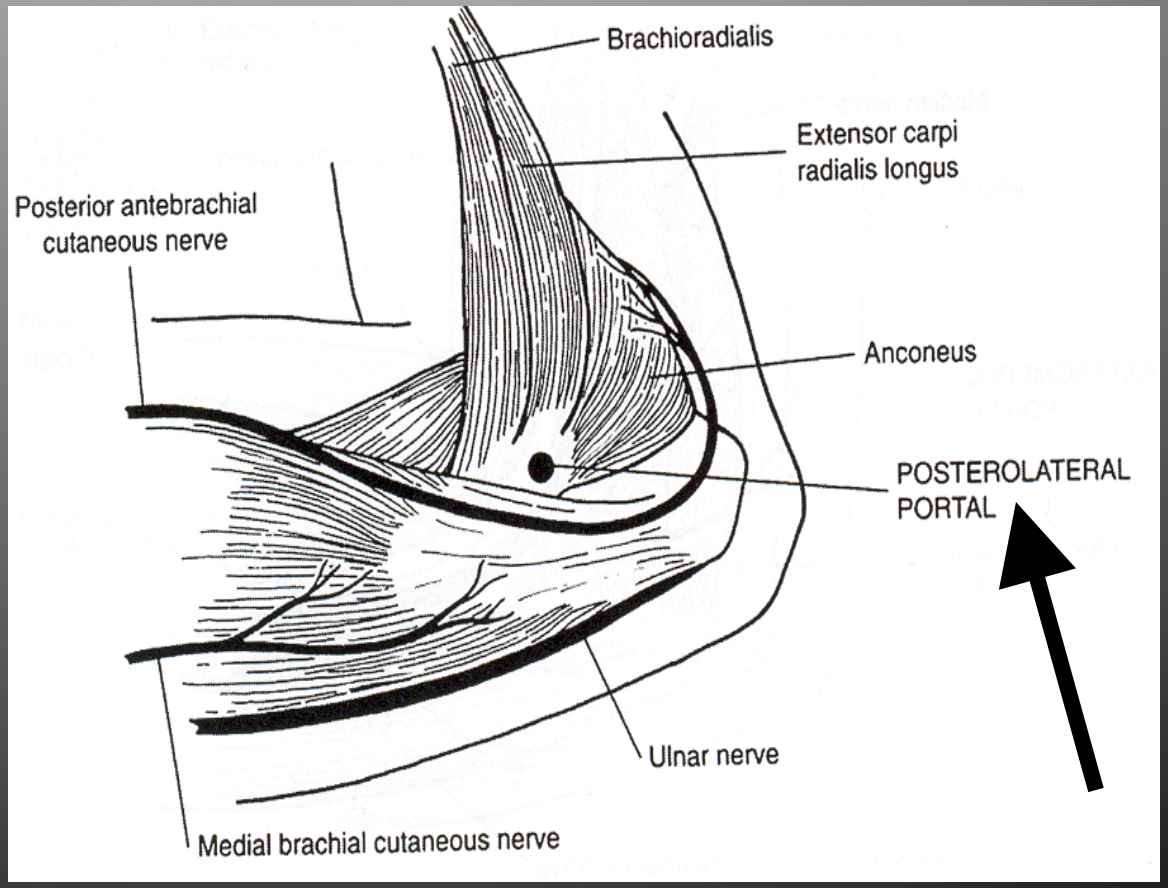

UCIrvine

KAISER PERMANENTE®

Proximal Lateral Portal

- 2 cm prox lat epi
- 2 cm ant lat epi
- center of the joint
  - contact with anterior humerus
- brachioradialis and brachialis

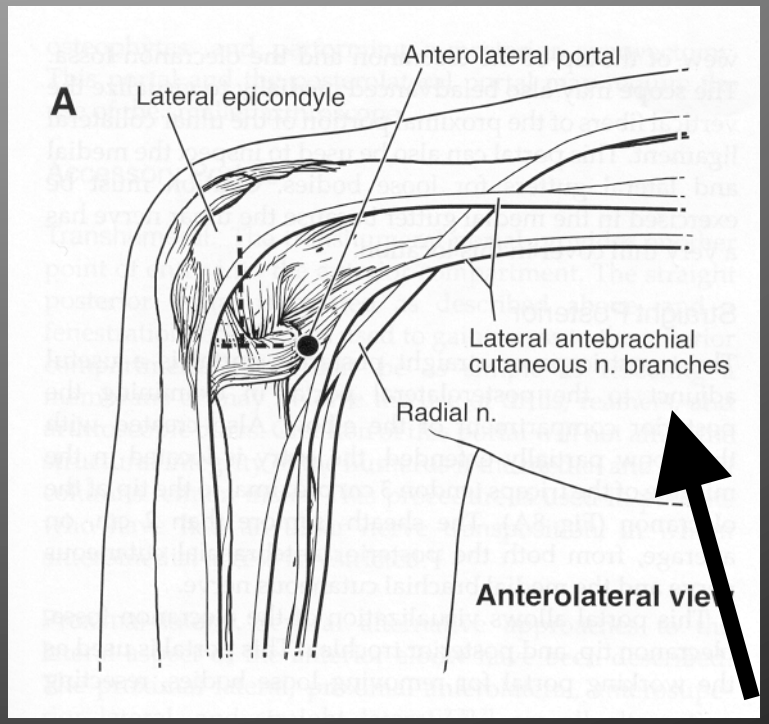

UCIrvine

KAISER PERMANENTE®

Proximal Lateral Portal - At Risk

- Radial nerve
  - 9.9 to 14.2mm from portal
- Posterior branch of lateral antebrachial cutaneous
  - lies on average 6.1mm from portal

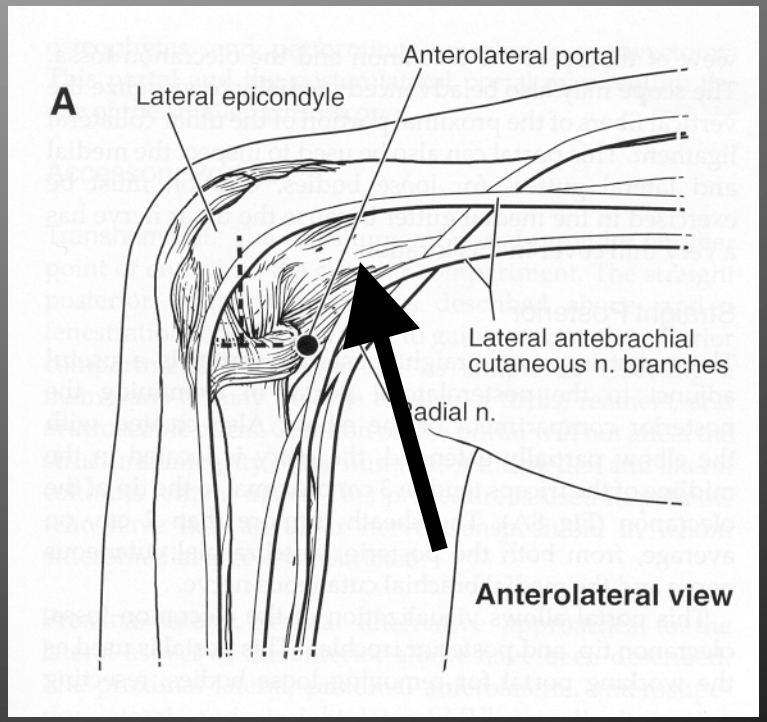

UCIrvine

KAISER PERMANENTE®

Patient Positioning

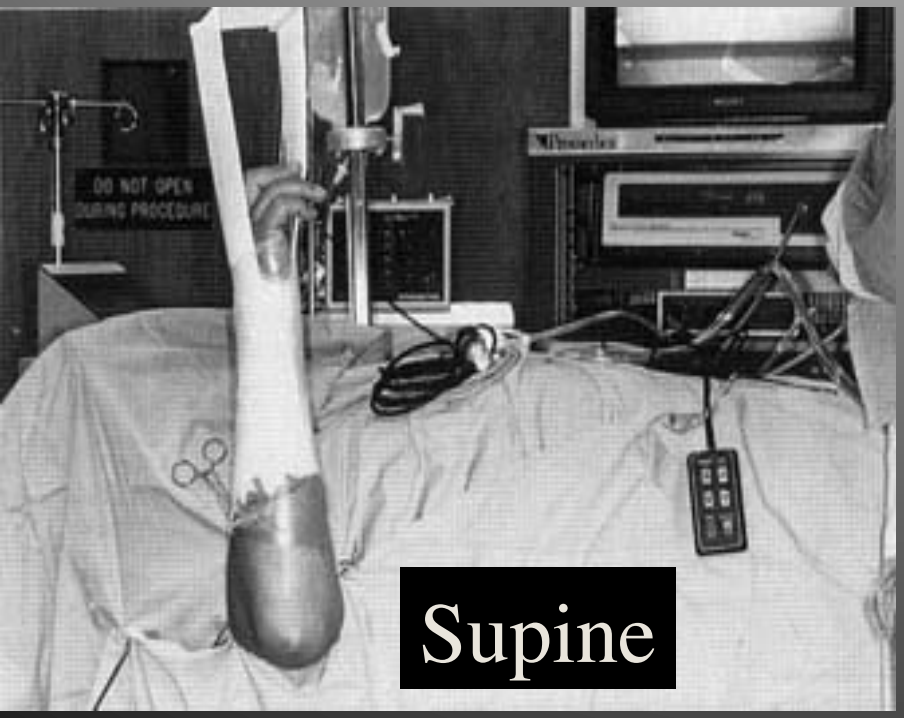

Supine

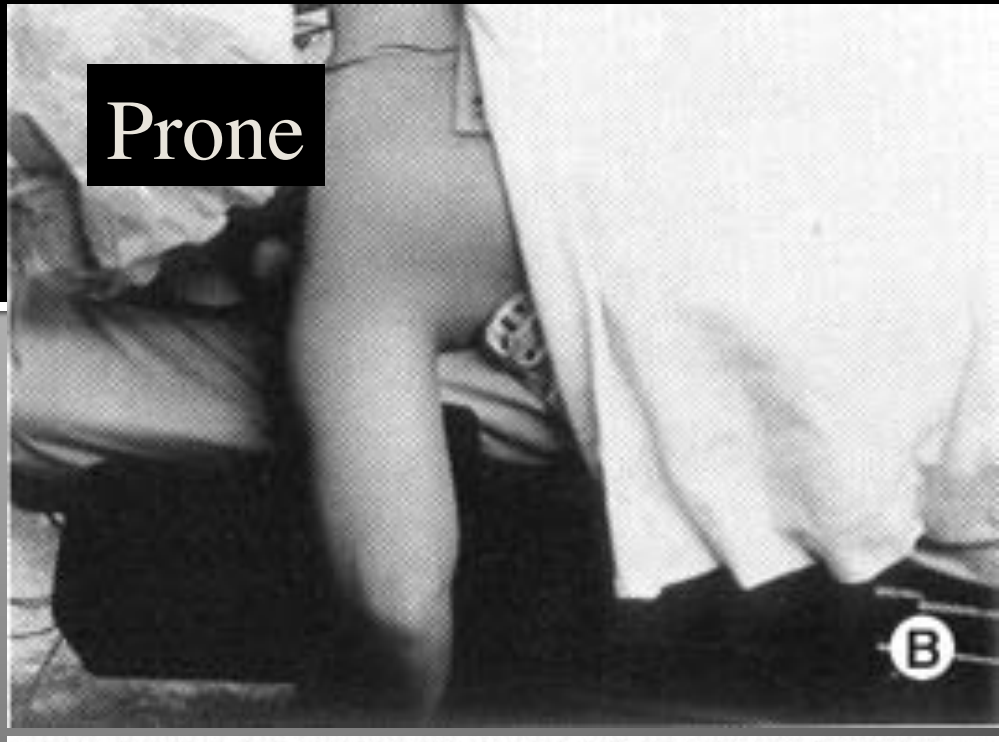

Prone

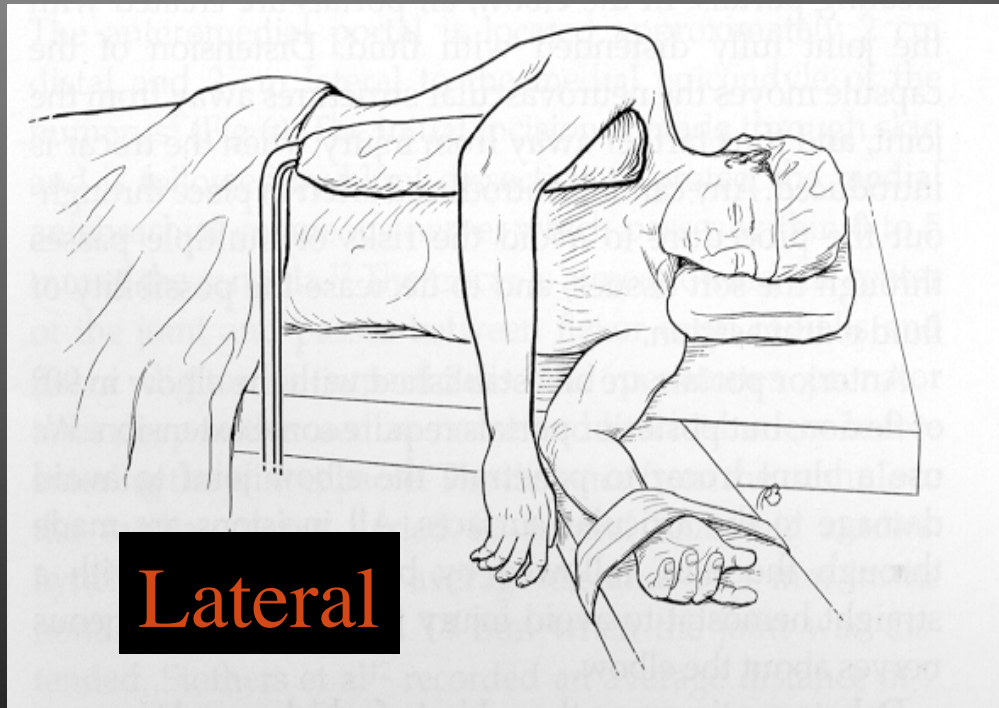

Lateral

UCIRVINE

Arthroscopic Equipment

- Basic arthroscopy set
- 4mm and 2.7 mm arthroscopes
- 30 and 70 degree scopes
- Pump system - extravasate
- Interchangeable cannula system for arthroscopes
- Shavers and burrs

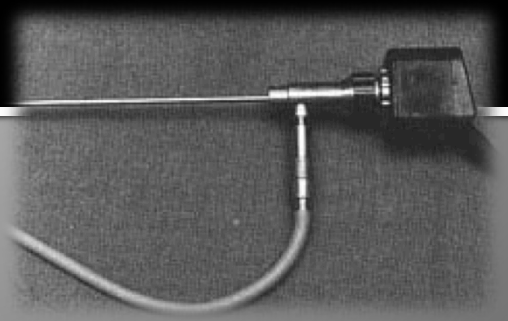



UCIrvine

KAISER PERMANENTE®

Patient positioning

UCIrvine

KAISER PERMANENTE®

Elbow arthroscopy positioning

UCIrvine

KAISER PERMANENTE®

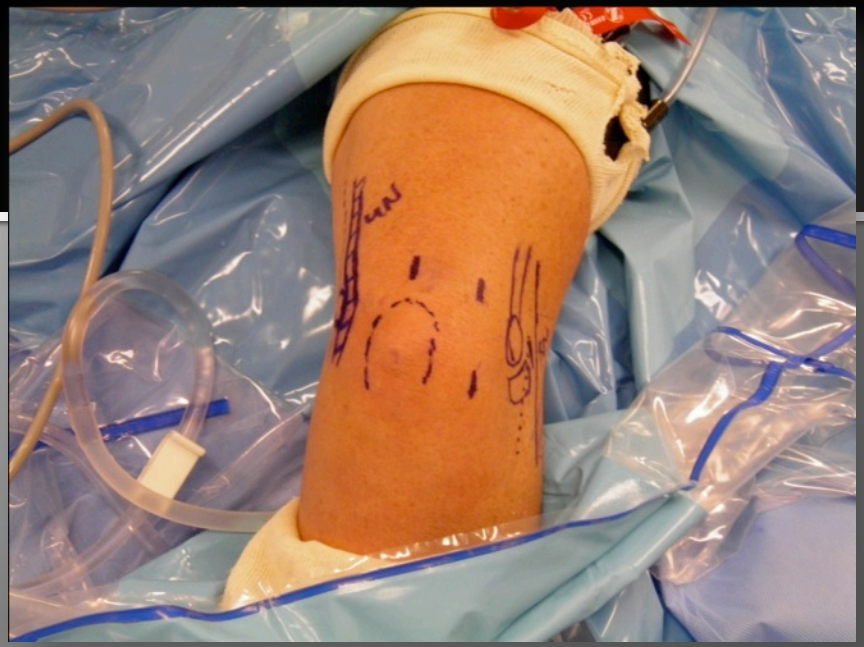

Portals

UCIrvine

KAISER PERMANENTE®

Osteocapsular Arthroplasty

- Safety Driven Strategy
  - Blonna, Wolf, et al JBJS 2013
  - 1. Get in
  - 2. Gaining space
  - 3. Bone work
  - 4. Capsular work
- Cubital tunnel release if < 90 degrees flexion

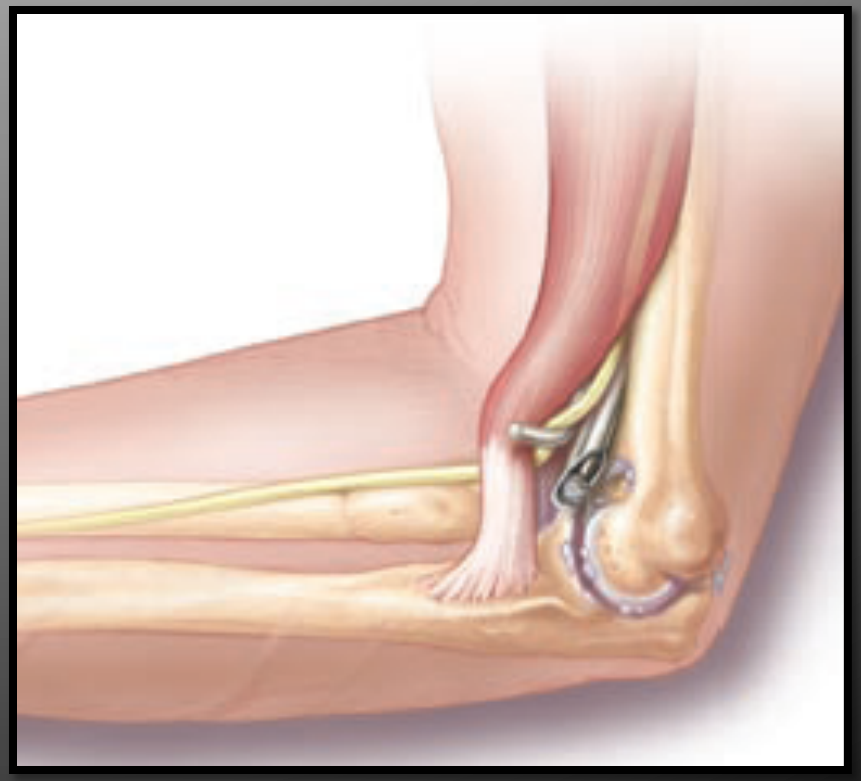

UCIrvine

KAISER PERMANENTE®

Steps

- Don’t Take Shortcuts

UCIrvine

KAISER PERMANENTE®

When to throw in the towel?

- Convert to open
  - Excessive swelling
  - Failure to obtain or maintain view
  - Inadequate progression

UCIrvine

KAISER PERMANENTE®

Arthroscopic Osteocapsular Arthroplasty

UCIrvine

KAISER PERMANENTE®

Results

- Few good studies
- Most are retrospective reviews of a surgeons series

UCIrvine

KAISER PERMANENTE®

Arthroscopic Osteocapsular Arthroplasty

- Cohen et al, Arthroscopy 2000
  - Arthroscopy versus open
    - Less pain with arthroscopy
    - Better motion with open
- Savoie et al, JSES 1999
  - 81 degree motion gain
  - Pain level 2.2/10

UCIrvine

KAISER PERMANENTE®

Results

- Steinman, JSES 2008
  - 41 patients/41 elbows
  - Flexion 117-131
  - Extension 21-8
- MacLean, JSES 2013
  - 20 patients/21 elbows
  - MEPS: 11 Excellent, 5 Good, 4 Fair, 1 Poor
  - No ROM assessment
  - DASH: improved from 34.0 to 12.7

UCIrvine

KAISER PERMANENTE®

Outerbridge (OK) vs Arthroscopic

- OK, Morrey, JBJS-B 1992
  - Extension 38-> 27
  - Flexion 113->123
  - Arc 75->96
- Athroscopic, O'Driscoll (unpublished)
  - Extension 32->17
  - Flexion 119->134
  - Arc 87->117

UCIrvine

KAISER PERMANENTE®

SCIENTIFIC ARTICLE

Outcomes of Elbow Arthroscopic Osteocapsular Arthroplasty

Samuel E. Galle, MD,* John D. Beck, MD,† Raoul J. Burchette, MA, MS,‡ Neil G. Harness, MD§

- JHS, 2016
  - Mild-moderate OA
  - 46 consecutive patients
  - Retrospective review
  - Single surgeon between December 2005 and January 2013.
  - 31 patients returned for final follow up valuation.

UCIrvine

KAISER PERMANENTE®

Methods

- Pre- and post-operative
  - VAS
  - Mayo Elbow Performance Score (MEPS)
- Post-operative
  - DASH
  - ASES

UCIrvine

KAISER PERMANENTE®

Methods

- Clinical examination
  - Range of motion, grip/pinch strength, neurologic evaluation and pain with relation to elbow position.

UCIrvine

KAISER PERMANENTE®

Demographics

Characteristic	Number or average (range)
Gender	
Male	27
Female	4
Age, years	48 (19-77)
Hand Dominence	
Right	30
Left	1
Operation on Dominent Extremity	
Yes	24
No	7
Follow Up Duration, Weeks	175 (31-422)

UCIrvine

KAISER PERMANENTE®

Broberg-Morrey Stage

- Grade 1 – 8
- Grade 2 – 21
- Grade 3 – 2

UCIrvine

KAISER PERMANENTE®

Results

TABLE 2. Results

Criteria	Before Surgery, Average (Range)	After Surgery, Average (Range)	*P*
Extension (°)	25 ± 12 (0–46)	12 ± 10 (0–32)	< .001
Flexion (°)	126 ± 15 (62–150)	135 ± 12 (98–152)	< .001
ROM (flexion-extension arc) (°)	102 ± 21 (43–135)	124 ± 18 (78–150)	< .001
Pronation (°)	80 ± 1 (75–80)	80 ± 4 (60–90)	> .05
Supination (°)	78 ± 7 (50–80)	79 ± 4 (60–80)	> .05
MEPS	57 ± 18 (10–85)	88 ± 14 (50–100)	< .001
VAS	6 ± 3 (0–9.6)	2 ± 2 (0–8)	< .001
DASH	NA	13 ± 18 (0–57.5)	
ASES: pain	NA	40 ± 12 (10–50)	

NA, not available.

UCIRVINE

KAISER PERMANENTE®

MEPS

- Final MEPS
  - 15 Excellent (48%)
  - 10 Good (32%)
  - 5 Fair (16%)
  - 1 Poor (3%)
- No complications

UCIrvine

KAISER PERMANENTE®

Flexion and Extension

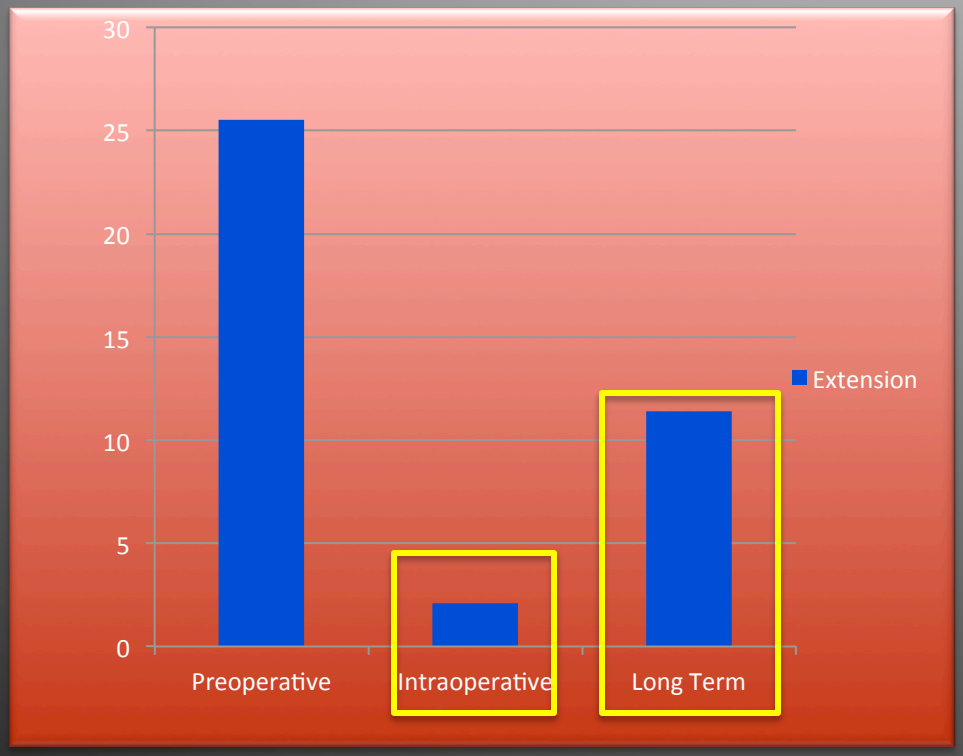

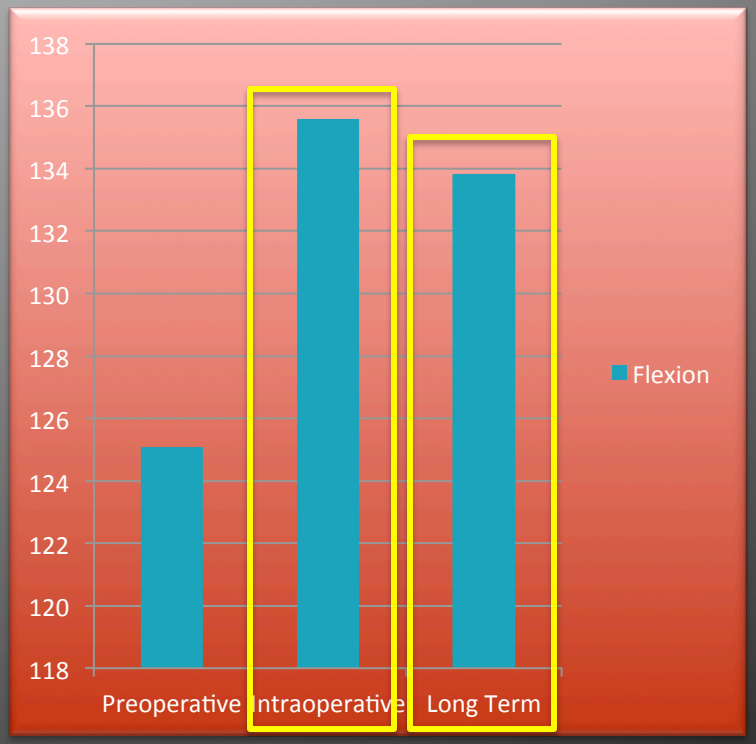

UCIrvine

KAISER PERMANENTE®

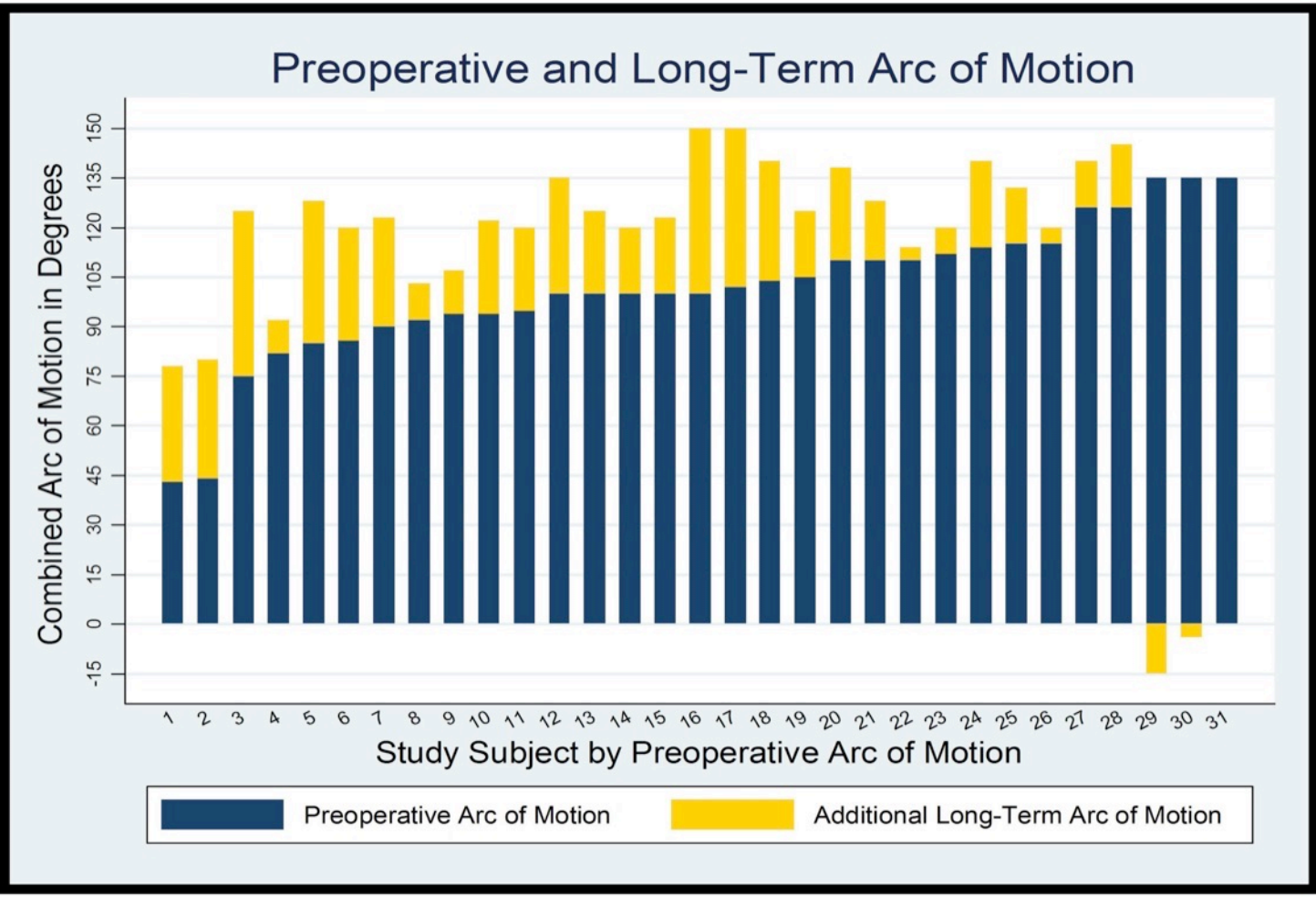

UCIRVINE

KAISER PERMANENTE®

Complications

- Complete transection of the median and radial nerves during arthroscopic release of post-traumatic elbow contracture. *Arthroscopy 1999*
- Ulnar nerve transection. *JBJS 2010*
- Radial nerve damage as a complication of elbow arthroscopy. *Clin Orthop 1987*
- Anterior interosseus nerve injury following elbow arthroscopy. *Arthroscopy 1997*

UCIrvine

KAISER PERMANENTE®

Kelly, Morrey, and O'Driscoll *JBJS* '01

- Reviewed 473 consecutive cases ('80 - '98)
- Dx - OA(150), Loose Body(112), RA(75)
- NO permanent neurovascular injuries, compartment syndromes, HO
- NO complications requiring reoperation
- NO increase in complications w increasing OR times, portals, indications

UCIrvine

KAISER PERMANENTE®

Kelly, Morrey, and O'Driscoll *JBJS* '01

- Serious complication rate of 0.8%
- 4 joint space infections
  - preop/intraop abx - 1/4 (use of abx not sig)
  - associated w intra-articular steroid inj at end of case ($p < 0.005$)
  - 0 of 356 cases w/o steroids had infx
  - Recommend routine use of pre-op abx, and discourage intra-articular steroids

UCIrvine

KAISER PERMANENTE®

Arthroscopic Osteocapsular Arthroplasty

- Valuable technique for elbow OA
  - Best for pain relief
  - Secondary benefit improved motion
- Safety
- Technique
  - Practice
- Experience
  - Start simple

UCIrvine

KAISER PERMANENTE®

Elbow Arthroscopic Osteocapsular Arthroplasty

Neil G. Harness, MD
Kaiser Permanente Orange County
University of California Irvine

UCIrvine

KAISER PERMANENTE®