Treatment decisions in thoracolumbar trauma: The Evolution of care for the Thoracolumbar Burst Fracture

K. B. Wood

Stanford Univ.

Thoracolumbar Spine

- Compression fractures
- Stable burst fractures
- Unstable burst fractures
- Fx- dislocations
- Chance fractures

STANFORD SPINE

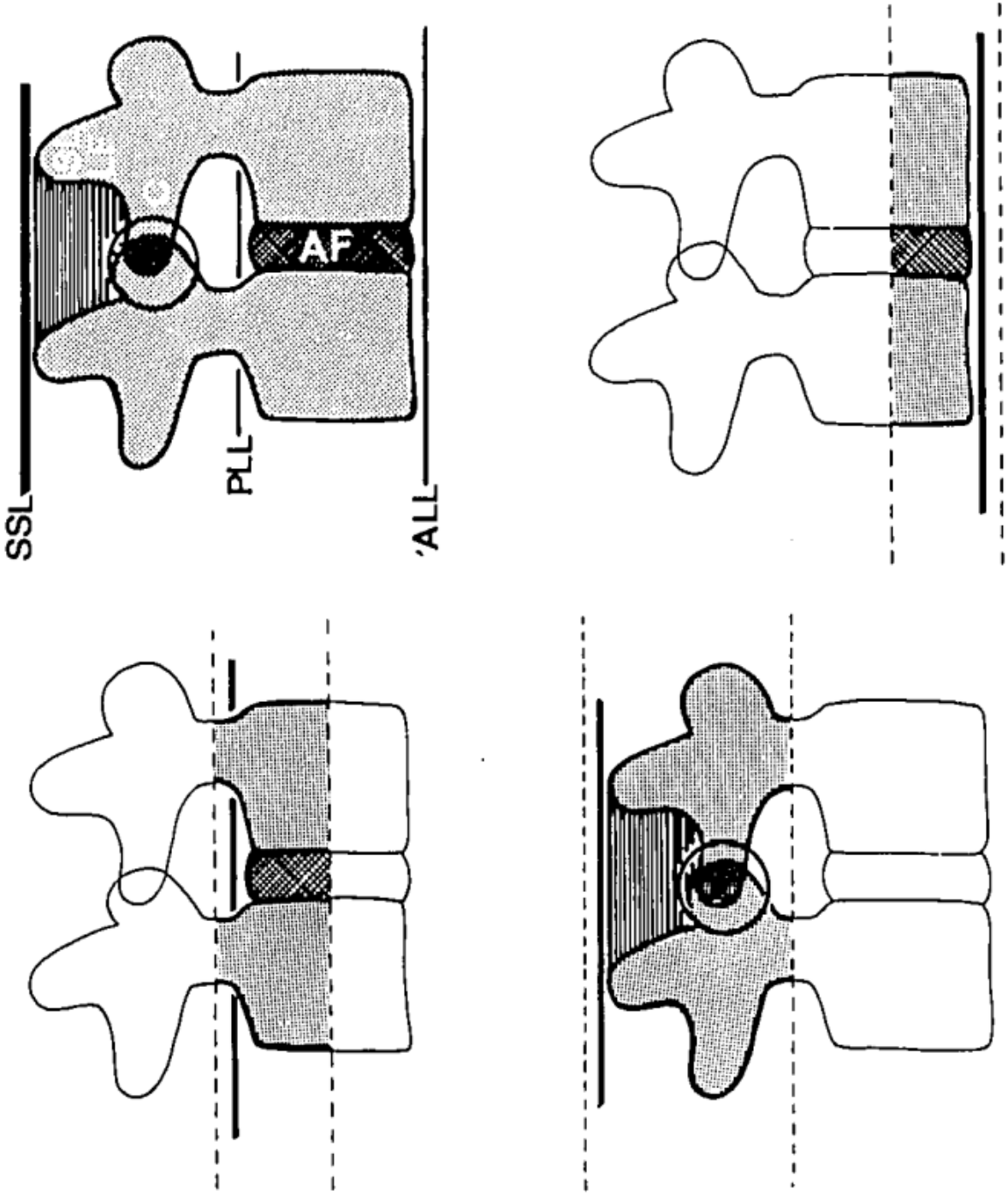

The Three Column Spine and Its Significance in the Classification of Acute Thoracolumbar Spinal Injuries

FRANCIS DENIS, MD, FRCS(C)

Spine, 1983

STANFORD SPINE

James KS, et al. Biomechanical evaluation of the stability of thoracolumbar burst fractures. *Spine* 1994; Aug 1; 19(15) 1731-40

- Biomechanical in-vitro study
- L1 Burst Fractures
- Sequential sectioning of “columns”
- *Significant increase in motion across T12-L2 with ANTERIOR and POSTERIOR column compromise, but NOT when MIDDLE added

STANFORD SPINE

Thoracolumbar Injury Classification System A New Approach

Spine Trauma Study Group

Vacarro, et al. *Spine* 2005
Bono, et al. *J Orthop Trauma* 2006
Lee, et al. *J. Orthop Sci* 2005
Harrop, et al. *J. Neurosurg Spine* 2006

SPINE

Spine Trauma Study Group
Thoracolumbar Injury Severity Scale

Three Part Description

Injury Mechanism

↓

Integrity of PLC

↓

Neurologic Status

STANFORD SPINE

Point System

Injury Mechanism
Select one

Compression fx

Axial, Flexion 1

Lateral (scoliosis >15°) 1

Burst - add 1

Distraction injury

4

Translation / Rotation

3

STANFORD SPINE

Neurology-Point System

Intact
0

Cauda equina
3

Nerve root
1

Cord
And conus medullaris

Incomplete
3

Complete
2

Posterior Soft Tissue Point System

Intact 0

PLC
(displaced in tension)

Suspected/

Indeterminant 2

Injured 3

Evaluated by MRI, CT, Plain X-rays, Exam

STANFORD SPINE

Next Step - Direct TX

Assign Points

Conservative ⟷ Surgery

STANFORD SPINE

Treatment

- Injuries with 3 points or less = non operative
- Injuries with 4 points=Nonop vs Op
- Injuries with 5 points or more = surgery

STANFORD SPINE

TLICS
Suggested Surgical Approach

	Posterior Lig.	Complex
Neuro Status	Intact	Disrupted
Intact	Posterior**	Posterior
Root Injury	Posterior	Posterior
Incomplete SCI or CES	Anterior	Combined
Complete SCI Cauda Equina	Posterior / *(Anterior)	Posterior / *(Combined)

* If felt necessary to optimize ANY potential, for neurologic recovery, restore CSF flow, allow short segment fixation ** Anterior if preferred

STANFORD SPINE

Morpholog	Neurology	PLC	Ant	Post	Combine
	Intact	Intact	40%	60%	
	Intact	Disrupt		92%	
	Incomplete	Intact	92%	4%	4%
	Incomplete	Disrupt	4%	14%	82%
	Complete	Intact	45%	55%	
	Complete	Disrupt	15%	76%	9%
Distraction				100%	

STANFORD SPINE

Spine

SPINE Volume 38, Number 23, pp 2028-2037

DIAGNOSTICS

AOSpine Thoracolumbar Spine Injury Classification System

Fracture Description, Neurological Status, and Key Modifiers

Alexander R. Vaccaro, MD, PhD,* Cumhur Oner, MD, PhD,† Christopher K. Kepler, MD, MBA,* Marcel Dvorak, MD,‡ Klaus Schnake, MD,§ Carlo Bellabarba, MD,¶ Max Reinhold, MD,‖ Bizhan Aarabi, MD,** Frank Kandziora, MD, PhD,§ Jens Chapman, MD,†† Rajasekaran Shanmuganathan, MD, PhD,‡‡ Michael Fehlings, MD, PhD,§§ Luiz Vialle, MD, PhD,¶¶ and for the AOSpine Spinal Cord Injury & Trauma Knowledge Forum

Figure 1. *The 3 basic types*—Type A: Compression injuries. Failure of anterior structures under compression with intact tension band. Type B: Failure of the posterior or anterior tension band. Type C: Failure of all elements leading to dislocation or displacement.

STANFORD SPINE

AOSpine Thoracolumbar Spine Injury Classification Study

- Continued lack of a universally accepted classification system
- AO Magerl: Multitudes, poor reliability, absence of clinical decision making
- TLICS: Poorly reliable; creator bias

STANFORD SPINE

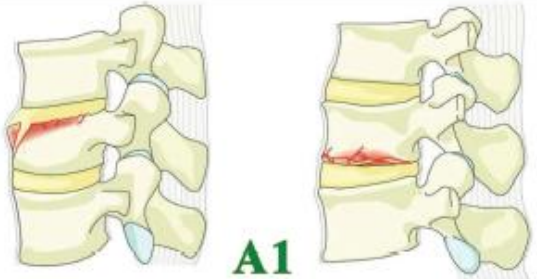

Figure 4. *Subtype A1—Wedge Compression*: Fracture of a single endplate without involvement of the posterior wall of the vertebral body. Vertebral canal is intact. Figure 4 demonstrates schematic drawing of this injury while Figure 4.2 available at Supplemental Digital Content http://links.lww.com/BRS/A814 shows a CT scan of a patient with this injury. CT indicates computed tomography.

- *Subtype* A1 injuries are wedge compression or impaction fractures with fracture of a single endplate without involvement of the posterior wall of the vertebral body as demonstrated in Figure 4; Figure 4.2, Supplemental Digital Content available at http://links.lww.com/BRS/A814.
- *Subtype* A2 injuries are split- or pincer-type fractures

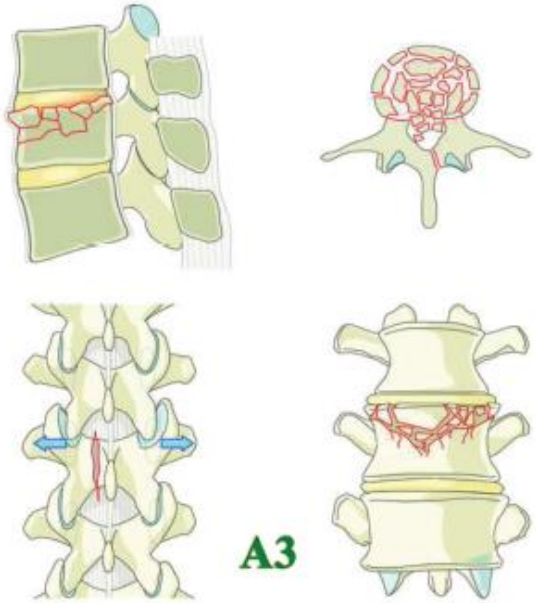

Figure 6. *Subtype A3—Incomplete burst:* Fracture with any involvement of the posterior wall of the vertebral body. Only a single endplate

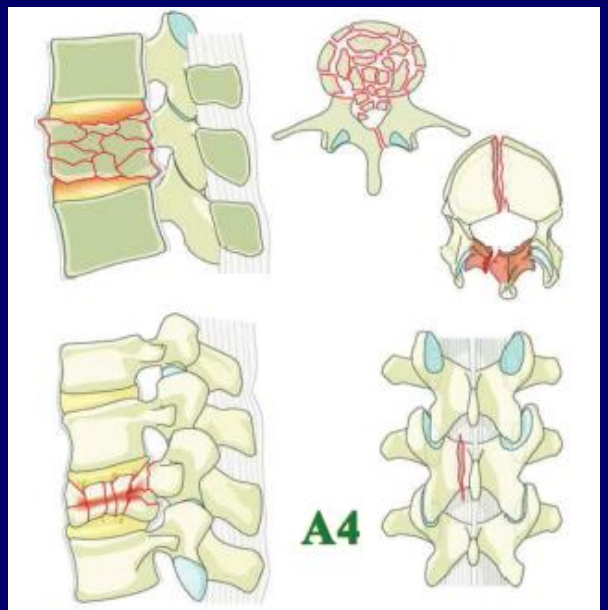

Figure 7. *Subtype A4—Complete burst:* Fracture with any involvement of the posterior wall of the vertebral body and both endplates. Vertical

fracture of the lamina is usually present and does not indicate a tension band failure. Figure 7 demonstrates schematic drawing of this injury while Figure 7.2 available at Supplemental Digital Content http://links.lww.com/BRS/A817 shows a CT scan of a patient with this injury. CT indicates computed tomography.

Type B Injuries: Tension Band Injury

Type B injuries affect either anterior or posterior tension band. These injuries may be seen in combination with type A fractures of the vertebral body. They are further divided in 3 subgroups.

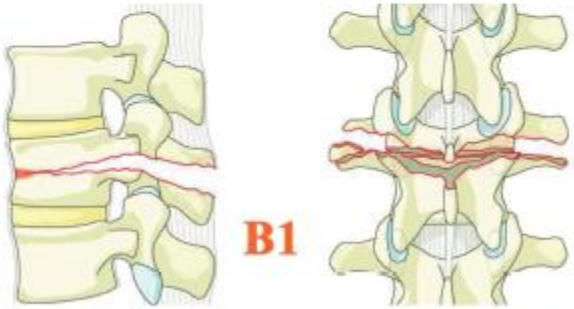

Figure 8. *Subtype B1—Monosegmental bony posterior tension band injury:* Transosseous failure of the posterior tension band. The classical

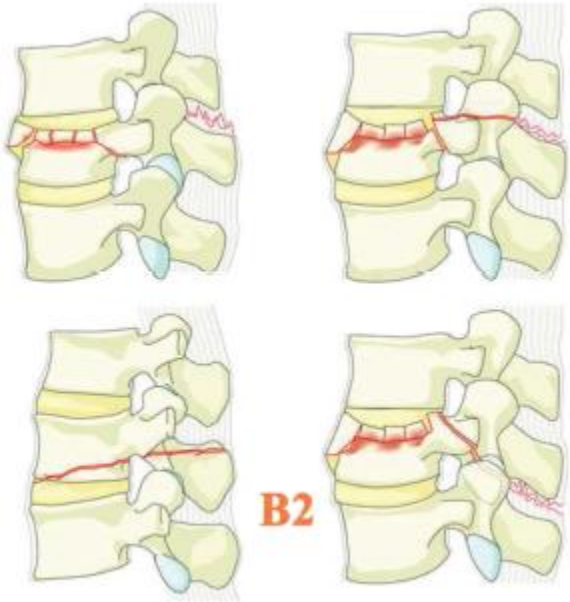

Figure 9. *Subtype B2—Posterior tension band disruption:* Bony and/or ligamentary failure of the posterior tension band together with a type A fracture. type A fracture should be classified separately. This example should be classified as: T12–L1 "type B2" with T12 "A4" according to

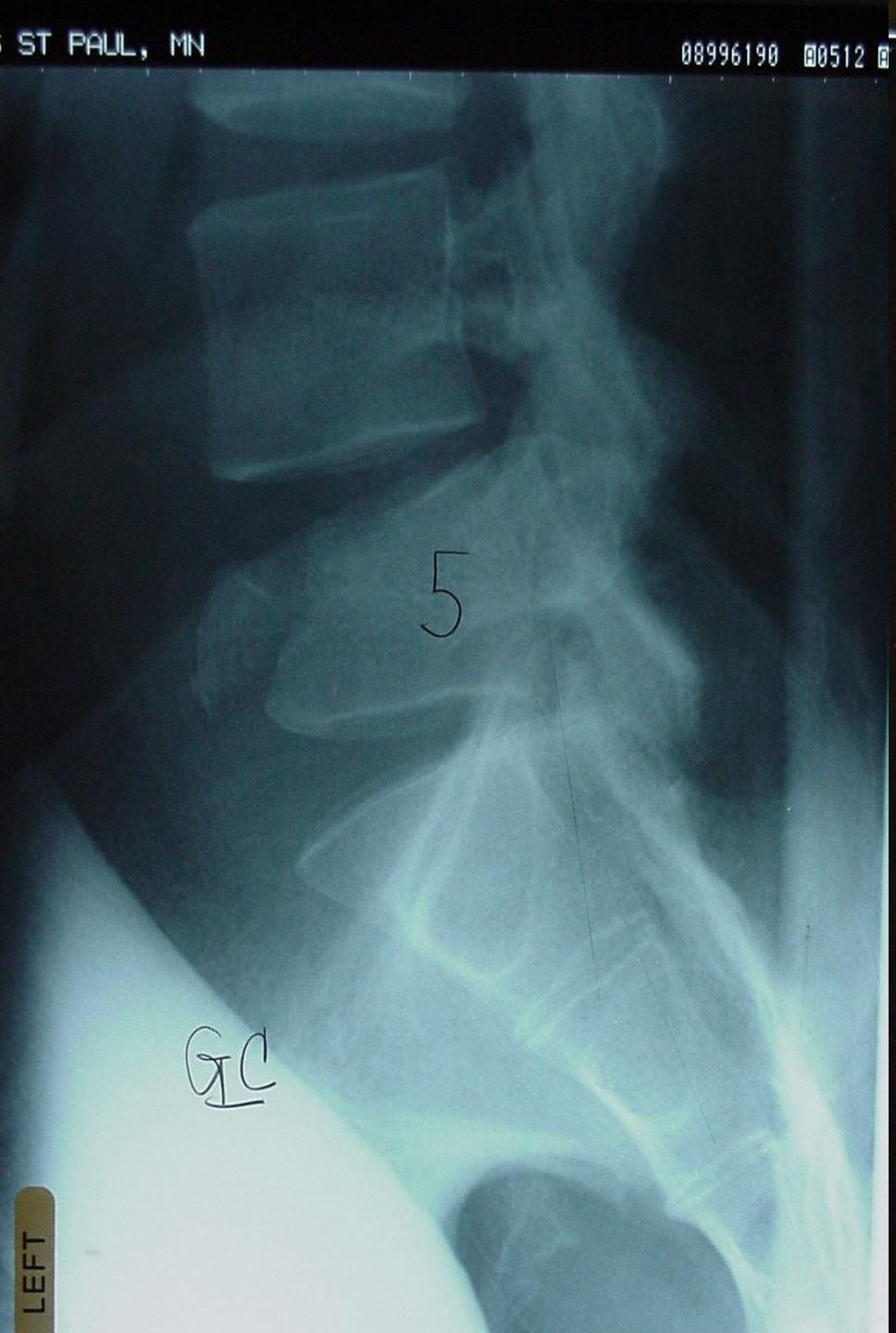
ST PAUL, MN
08996190 0512
5
GC
LEFT

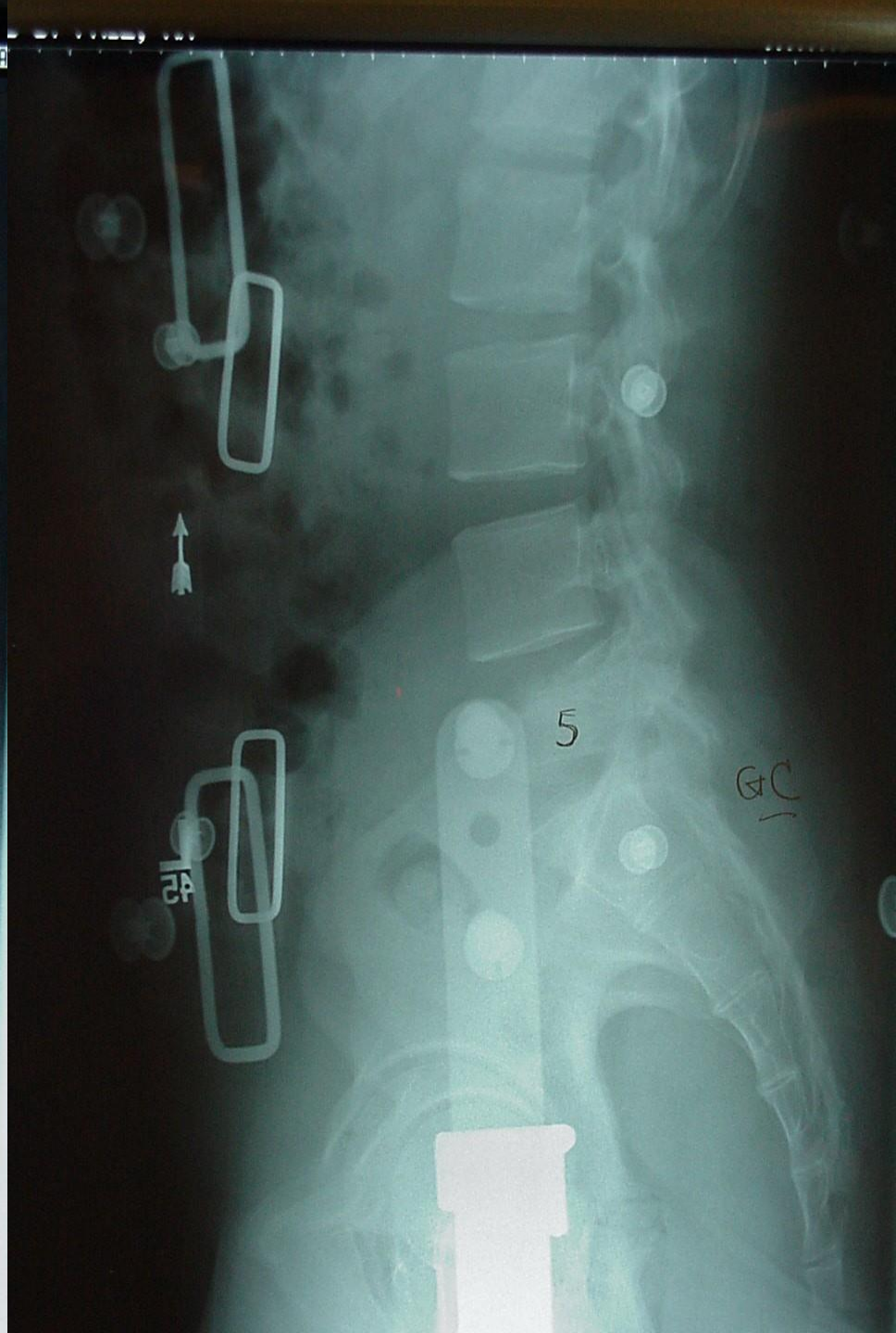
5
GC

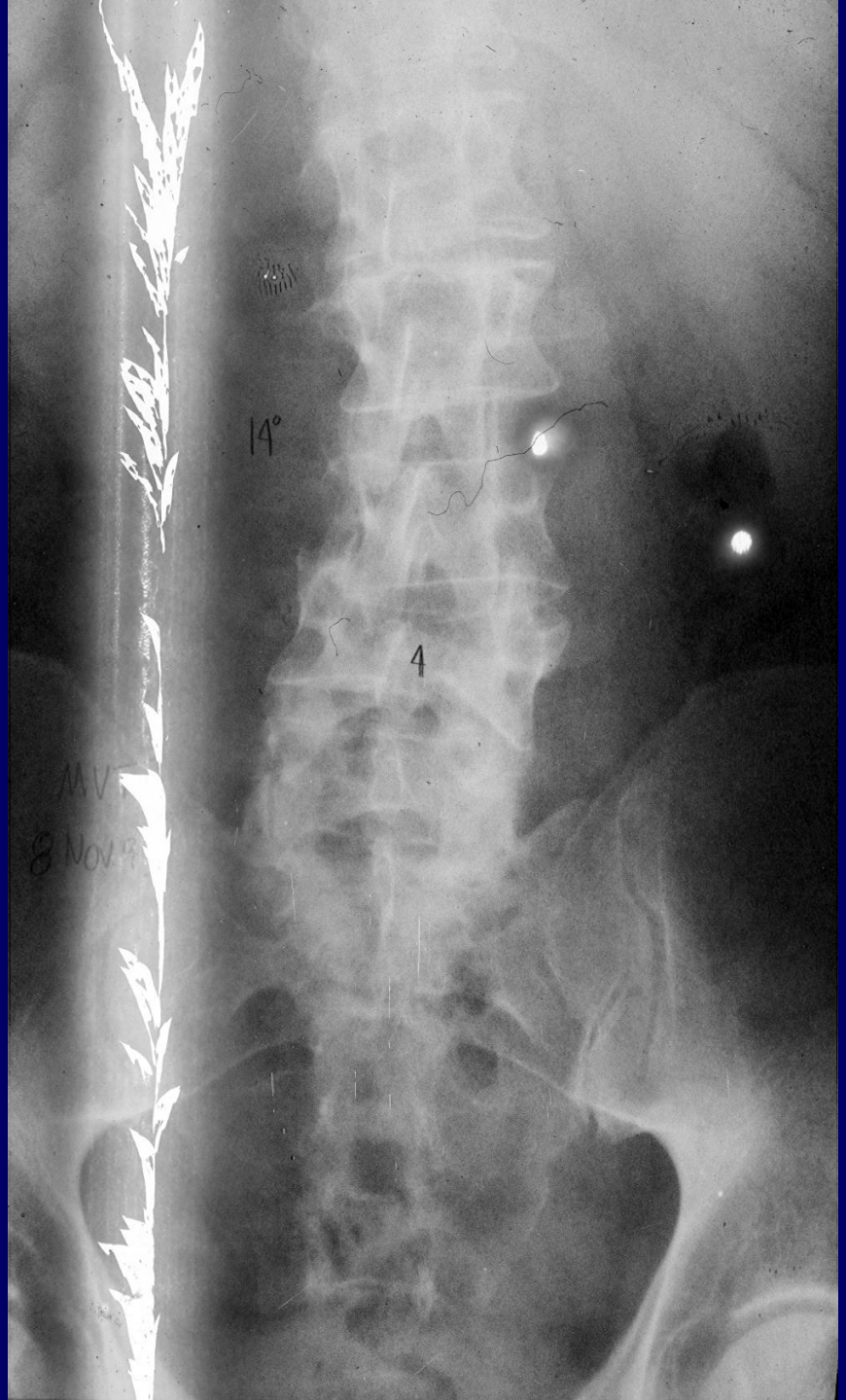
14°
4
8 Nov.


SPINE
SOMATOM PLUS
UNIVERSITY OF MINN
NTERIOR

Operative v. Non-operative Treatment of Thoracolumbar Burst Fractures Without Neurologic Deficit: A Prospective, Randomized Study 16-22 year follow-up

JBJS-Am. 2015 Jan. (97-A); pg 3-8

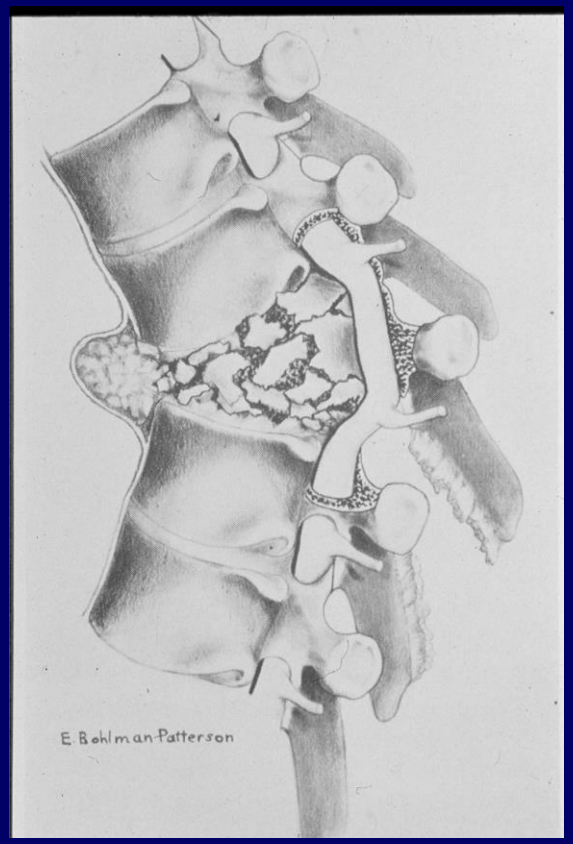

STANFORD SPINE

Results
Pain

- Visual Analog Scale
  - Operative: Admiss. 6.3 (3-10)
    - » 4 year Follow-up: 3.4 (0- 7.5)
    - » 15-20 year follow-up: 3.9
  - Non-Operative: Adm: 5.8 (0-10)
    - » 4 year Follow-up: 2.3 (0-9)
    - » 15-20 year follow-up: 1.7 (p=0.14)

Results
Rolland and Morris Back Disability

	Operative	Non-Operative
Adm	24.6	24
4 yr. F/U	16	20
17 yr. F/U	17 (6-25)	23.5 (16-25)

(p=0.003)

STANFORD SPINE

Results
Oswestry

	Operative	Non-operative
4 yr. F/U	22.1	15.1
15-20 yr. F/U	17.2 (0-48)	4.9 (0-22) (p=0.032)

(0-20 = minimal disability
21-40 = moderate disability)

STANFORD SPINE

SF-36

- All indices favored the NON-operative group
- Social (p=0.02)
- Pain (p=0.01)
- General health (p=0.01)

Results
Return to work

- Operative:
  - 10/25 in < 6 mo (40%)
  - 2 in a6 – 12 mo
  - 40% (10) not working
  - 53% not working
- Non-operative
  - 16/23 in < 6 mo (70%)
  - 5/23 (22%) not working
  - 27% not working

STANFORD SPINE

Summary

- First study with 15-20 year follow-up
- No advantage to operative treatment of stable, neurologically intact thoraco-lumbar burst fractures
- Non-operative treatment may be significantly advantageous

STANFORD SPINE

Non-operative treatment

- Gummerson Surgery 2009
- Thomas KC, et al. J Neurosurg Spine 2006
- Weinstein Spine 1988
- Mumford, et al. Spine 1993
- Shen, et al Spine 2001
- Aviles C, Medwave 2016
  - 14 systematic reviews and 25 RCTs
  - “Unclear if there are any differences”
- Cahuque M, et al. J Orthop 2016
  - Conservative treatment recommended
  - Less than 35º of kyphosis

STANFORD SPINE

J Neurosurg Spine 11:295–303, 2009

Comparison of thoracolumbosacral orthosis and no orthosis for the treatment of thoracolumbar burst fractures: interim analysis of a multicenter randomized clinical equivalence trial

Clinical article

Christopher S. Bailey, M.D., M.Sc.(Surg), F.R.C.S.C.,[1]
Marcel F. Dvorak, M.D., F.R.C.S.C.,[2] Kenneth C. Thomas, M.D., M.H.Sc., F.R.C.S.C.,[3]
Michael C. Boyd, M.D., F.R.C.S.C.,[2] Scott Paquett, M.D., F.R.C.S.C.,[2]
Brian K. Kwon, M.D., Ph.D., F.R.C.S.C.,[2] John France, M.D., F.R.C.S.C.,[4]
Kevin R. Gurr, M.D., F.R.C.S.C.,[1] Stewart I. Bailey, M.D., F.R.C.S.C.,[1]
and Charles G. Fisher, M.D., M.H.Sc., F.R.C.S.C.[2]

- 69 patients randomized
- Non-brace wearers were encouraged to ambulate immediately maintaining “neutral” alignment for 2 mos.
- No difference at 1 year
- 4 failures requiring surgery: 3 from TLSO group

STANFORD SPINE

When IS surgery indicated for thoracolumbar burst fractures?

- Multi-trauma
- Obese?
- Senile?
- Injuries to the Posterior ligamentous complex
  - "Unstable Burst Fractures" MacAfee 1983
  - There remains NO level I or II data directly comparing operative v. non-operative
  - Sensitivity of MR
- Neurologic injuries
- The 10 – 25%??

STANFORD SPINE

STANFORD
SPINE

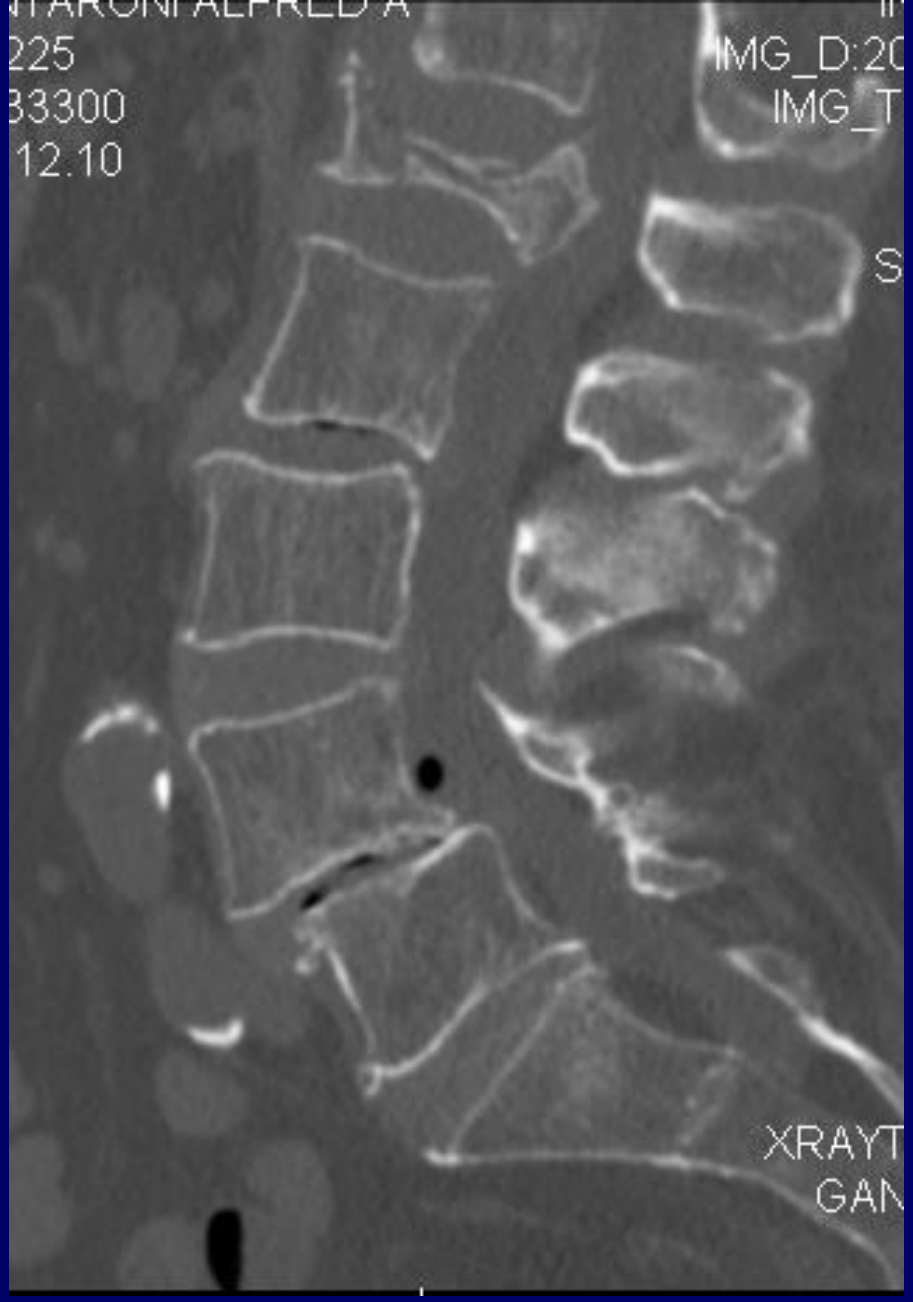

SPINE

Nguyen HV, Ludwig S, Gelb D. Osteoporotic vertebral burst fractures with neurologic compromise. *J Spinal Disord Tech*. 2003 Feb; 16(1): 10-19

- 10 pts. In three years with neurological compromise.
- Mean age 76.
- 90% present > 1 mo. after symptoms
- Symptoms themselves typically present LATE

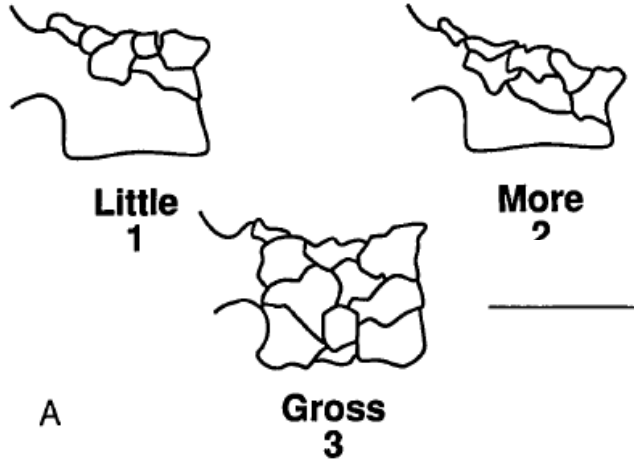

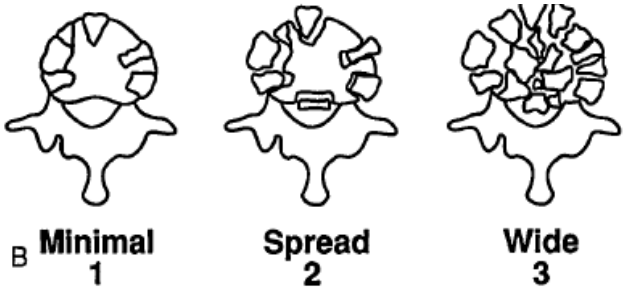

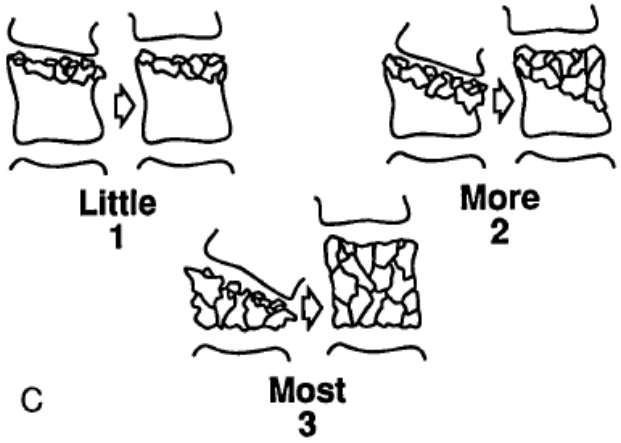

SPINE Volume 19, Number 15, pp 1741–1744

The Load Sharing Classification of Spine Fractures

Thomas McCormack, MD, Eldin Karaikovic, MD, and Robert W. Gaines, MD

STANFORD
SPINE

Operative

- Siebenga, et al. Treatment of traumatic thoracolumbar spine fractures: a multicenter prospective randomized study of operative versus nonsurgical treatment. *Spine* 2006
  - 34 pts. With AO Type A fractures
  - All functional outcomes better with operative treatment at 4.3 yr
- Siebenga, et al. Cost-effectiveness of the treatment of traumatic thoracolumbar spine fractures: Nonsurgical or surgical therapy? *Indian J. Orthop*. 2007
  - 30 pts. Compared at 2 years for direct and indirect costs
  - Total cost TWICE as much per patient when treated non-operatively
- Schmid, et al *Injury* 2012
- Shen *Orthop Surg*. 2011

STANFORD SPINE

Spine
SPINE Volume 41, Number 6, pp 483–489

CLINICAL CASE SERIES

Nonoperative Management in Neurologically Intact Thoracolumbar Burst Fractures: Clinical and Radiographic Outcomes

Patrick W. Hitchon, MD,* Kingsley Abode-Iyamah, MD,* Nader S. Dahdaleh, MD,† Christopher Shaffrey, MD,‡ Jennifer Noeller, ARNP,* Wenzhuan He, MD,§ and Toshio Moritani, MD¶

- 68 neurologically intact burst fractures of T-L junction (T11-L2)
- All with TLICs score of 2
- 18/68 (25%) failed mobilization and went on to surgery
- More kyphotic (8º v. 1º)
- More stenotic (48% v. 37%)
- LSC score (McCormack Spine 1994) (7 v. 6)

STANFORD SPINE

PLOS | ONE

RESEARCH ARTICLE

Risk Factors for the Failure of Spinal Burst Fractures Treated Conservatively According to the Thoracolumbar Injury Classification and Severity Score (TLICS): A Retrospective Cohort Trial

Jieliang Shen[1], Linfei Xu[2], Baolong Zhang[2]*, Zhenming Hu[1]*

1 Department of Orthopaedic Surgery, the First Affiliated Hospital of Chongqing Medical University, 1 Youyi Rd., Chongqing, 400016, China, **2** Department of Orthopaedic Surgery, The People's Hospital Of Zhengzhou, No.33 Huanghe Rd, Zhengzhou, Henan Province, 450003, China

* blzhang111@163.com (BZ); spinecenter_hu@126.com (ZH)

Aug 15, 2015

Retrospective study of 129 Pts. With TL burst fractures (TLICS < 4) (Mean f/u 36 +/- 11 mo.)
80% successful NON-operative
20% NOT successful: Converted to surgery
RISK factors:
- VAS on admission: 6.5 v. 3.6
- Age and kyphosis NOT a predictor

ASIAN SPINE JOURNAL
Clinical Study
Asian Spine J 2016;10(1):136-142 • http://dx.doi.org/10.4184/asj.2016.10.1.136

Decision-Making Process in Patients with Thoracolumbar and Lumbar Burst Fractures with Thoracolumbar Injury Severity and Classification Score Less than Four

Shirzad Azhari, Parisa Azimi, Sohrab Shahzadi, Hassan Reza Mohammadi, Hamid Reza Khayat Kashani

Department of Neurosurgery, Shahid Beheshti University of Medical Sciences, Tehran, Iran

- PROSPECTIVE study
- Non-operative treatment with bed rest and bracing
- Surgery for “intractable pain”
- 90% successful (30% improvement in ODI)
- RISK predictors:
  - AGE (51 v. 33)
  - Canal involvement (51% v. 33%)

STANFORD SPINE

SPINE Volume 33, Number 23, pp 2536–2544

Conservative Treatment of Thoracolumbar Burst Fractures

A Long-term Follow-up Results With Special Reference to the Load Sharing Classification

Li-Yang Dai, MD, PhD, Lei-Sheng Jiang, MD, PhD, and Sheng-Dan Jiang, MD, PhD

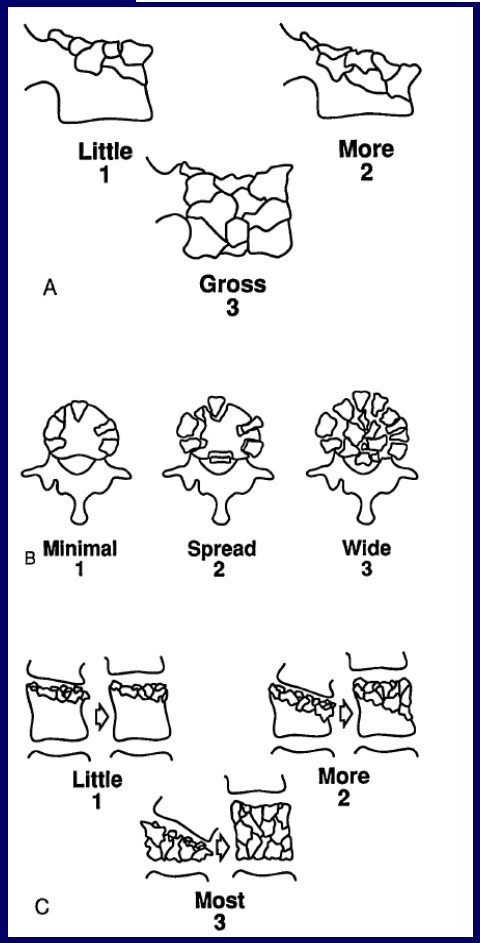

- 137 thoracolumbar burst fractures
- 22 pts. with neurologic deficit
- Loss of kyphosis correction significantly correlated with load sharing score
- Loss of correction positively correlated with severity of pain ($p=0.04$, $r = 0.194$)

STANFORD SPINE

Less invasive?

- Obese?

ELSEVIER

CrossMark

The Spine Journal 15 (2015) 1172–1178

THE SPINE JOURNAL

Clinical Study

Clinical and radiological results 6 years after treatment of traumatic thoracolumbar burst fractures with pedicle screw instrumentation and balloon assisted endplate reduction

Jorrit-Jan Verlaan, MD, PhD[a,*], Inne Somers, MD[b], Wouter J.A. Dhert, MD, PhD[a], F. Cumhur Oner, MD, PhD[a]

[a]*Department of Orthopaedics, University Medical Center Utrecht, Heidelberglaan 100, 3584CX Utrecht, The Netherlands*
[b]*Department of Radiology, University Medical Center Utrecht, Heidelberglaan 100, 3584CX Utrecht, The Netherlands*

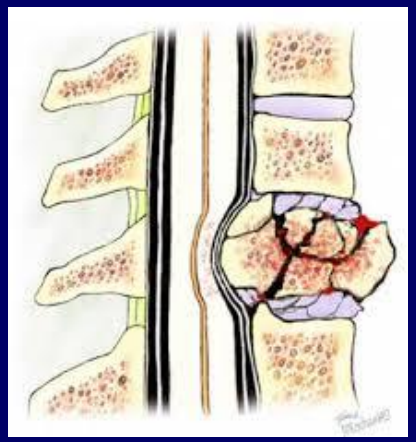

STANFORD SPINE

Less Invasive?

- 20 patients
  - Earlier it was *Vertebroplasty* but had five cement leakages!
- Remove pedicle screws after one year
- Average kyphosis 5.6º

Minimally invasive pedicle screw fixation combined with percutaneous vertebroplasty for the treatment of thoracolumbar burst fracture

Chunbo Li, M.D., Jianfeng Pan, M.D., Yutong Gu, M.D., Ph.D., Jian Dong, M.D., Ph.D

37 pts.
Kyphosis corrected from 22 ➡ 5 degrees
VAS 1 at final (2 year) follow-up

STANFORD SPINE

Future?

OP

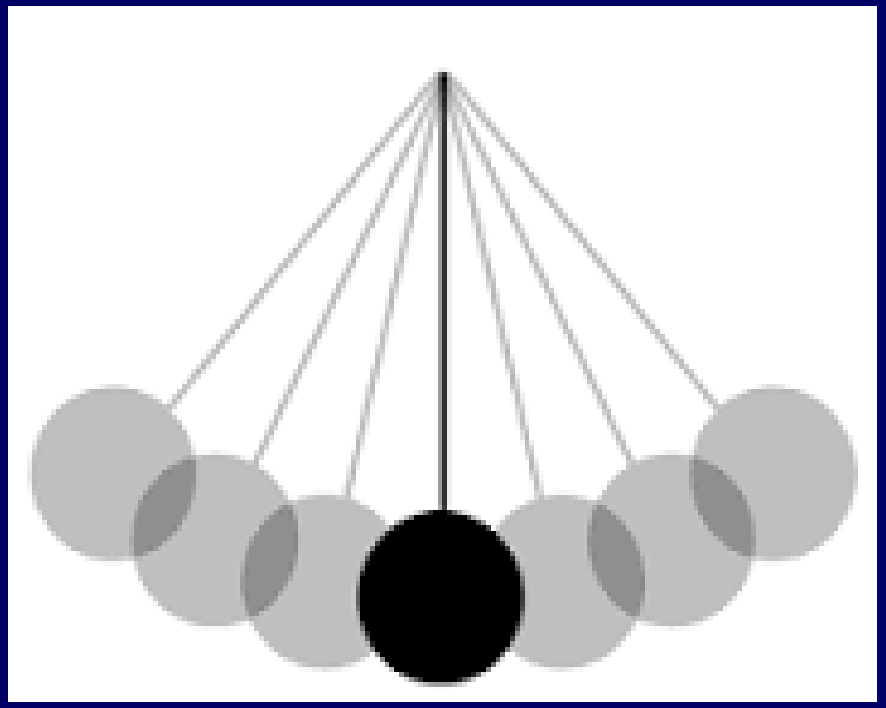

Non-OP

Something in between?

Thank You

STANFORD SPINE